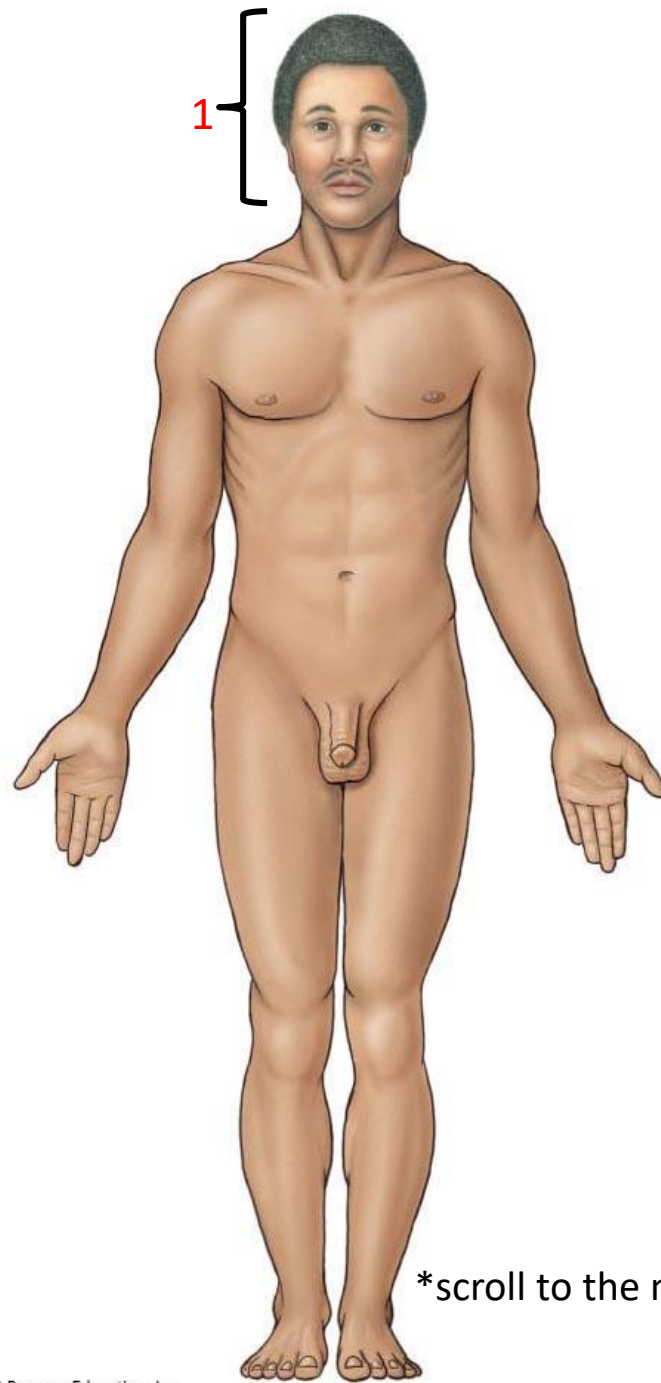


# **Anatomical Terminology**

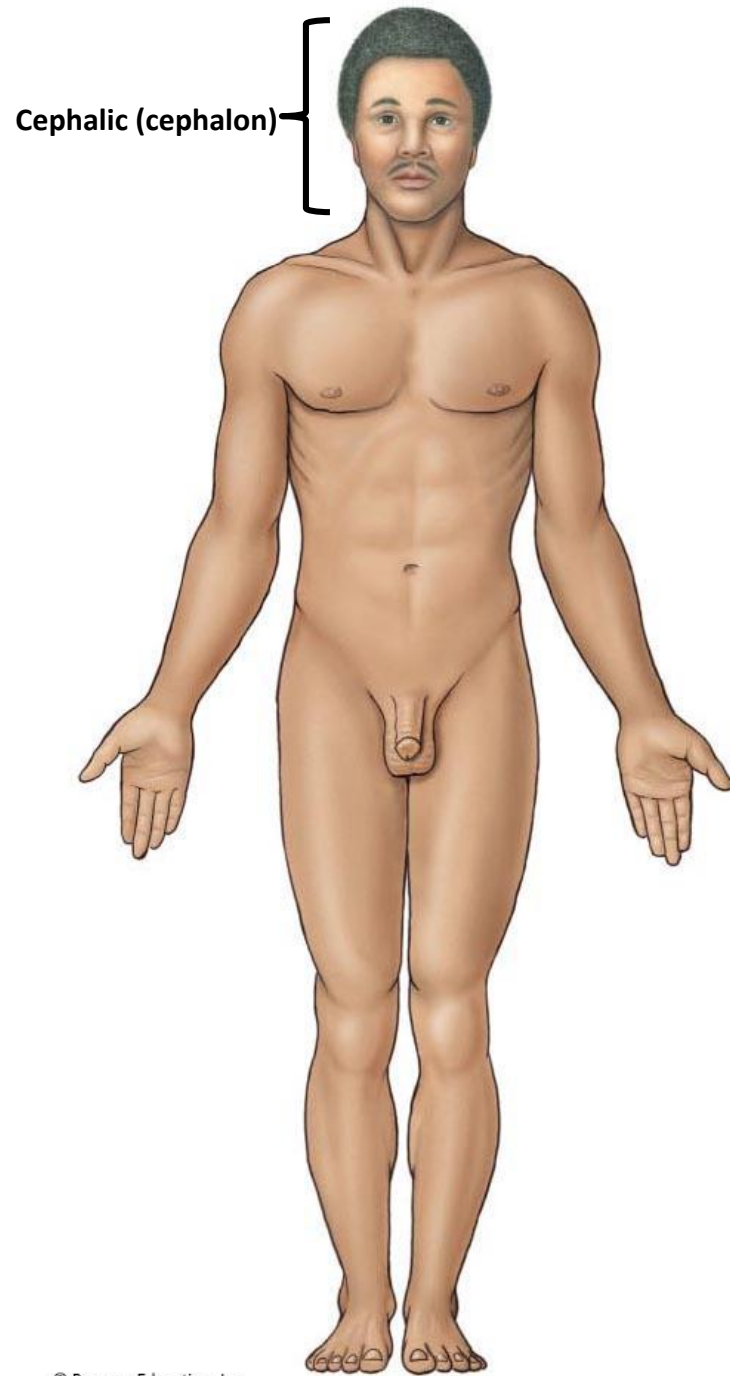
## **Practice Exam #2**

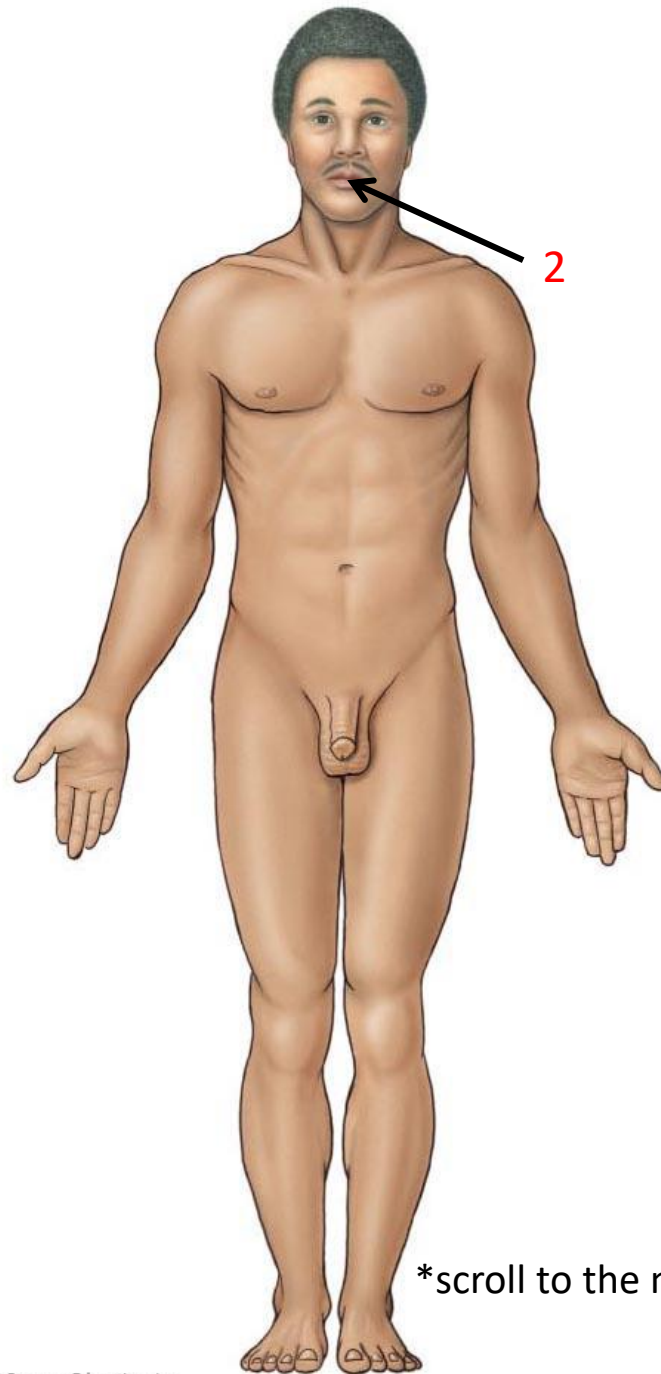
\*For best results on these practice exams, write your answers on paper before scrolling to see the correct answer and make sure to check your spelling!

Using proper anatomical terminology, name the following body regions and landmarks:

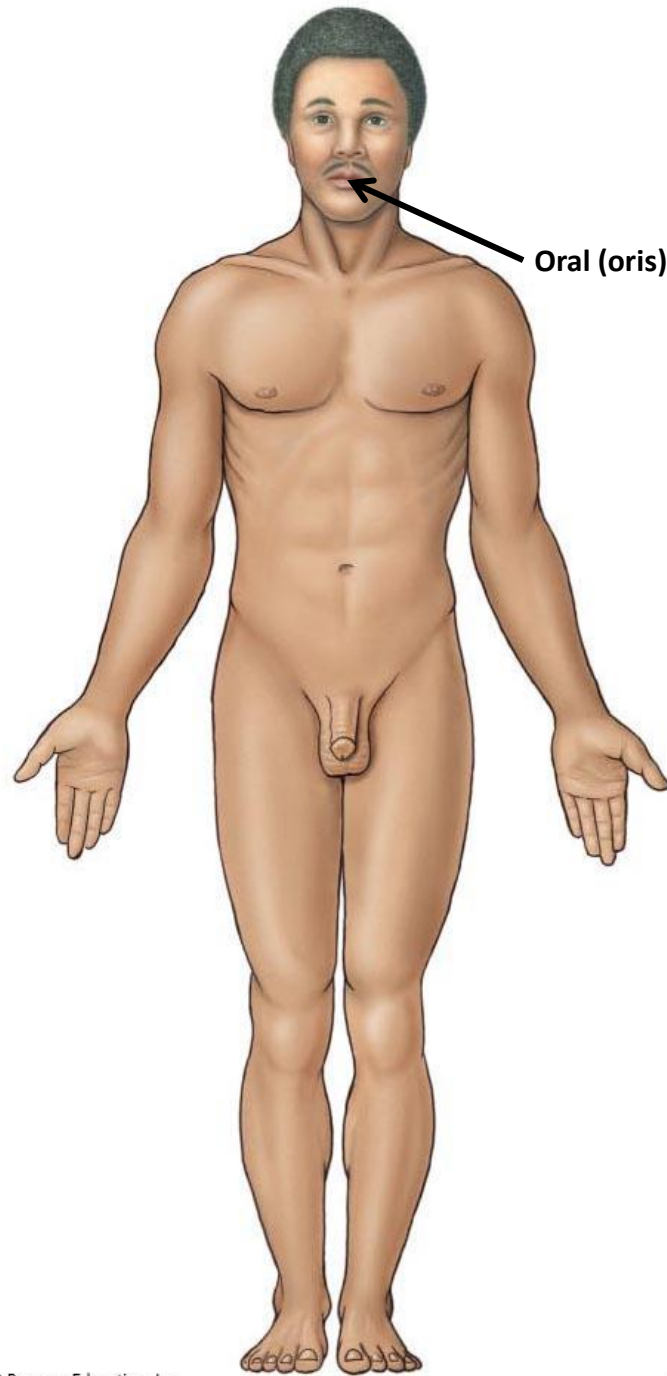


\*scroll to the next slide to check your answer

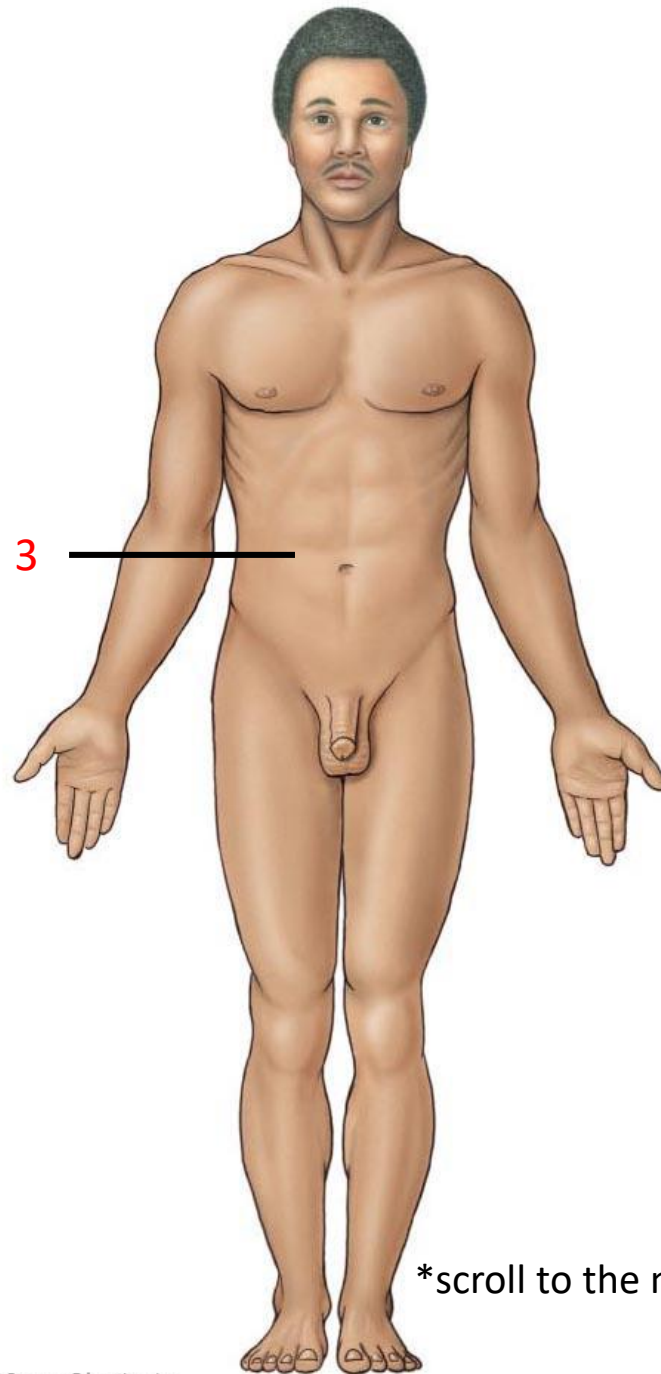




\*scroll to the next slide to check your answer

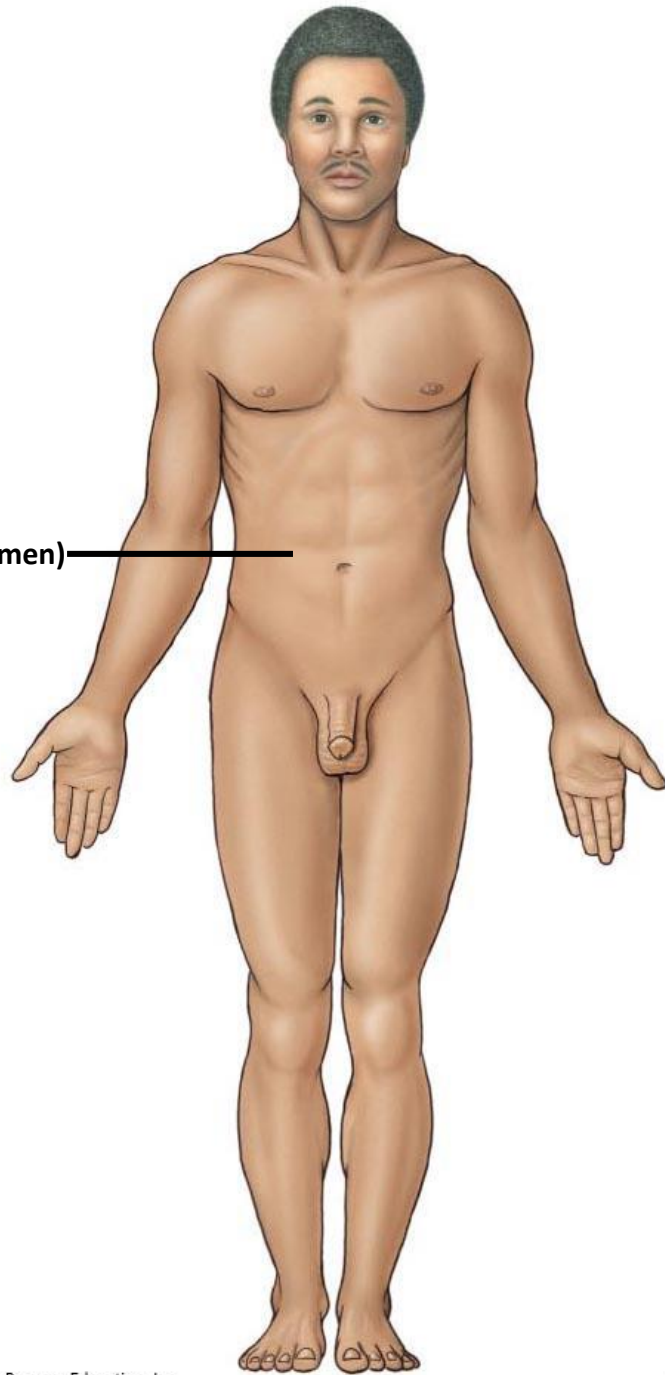


**Oral (oris)**

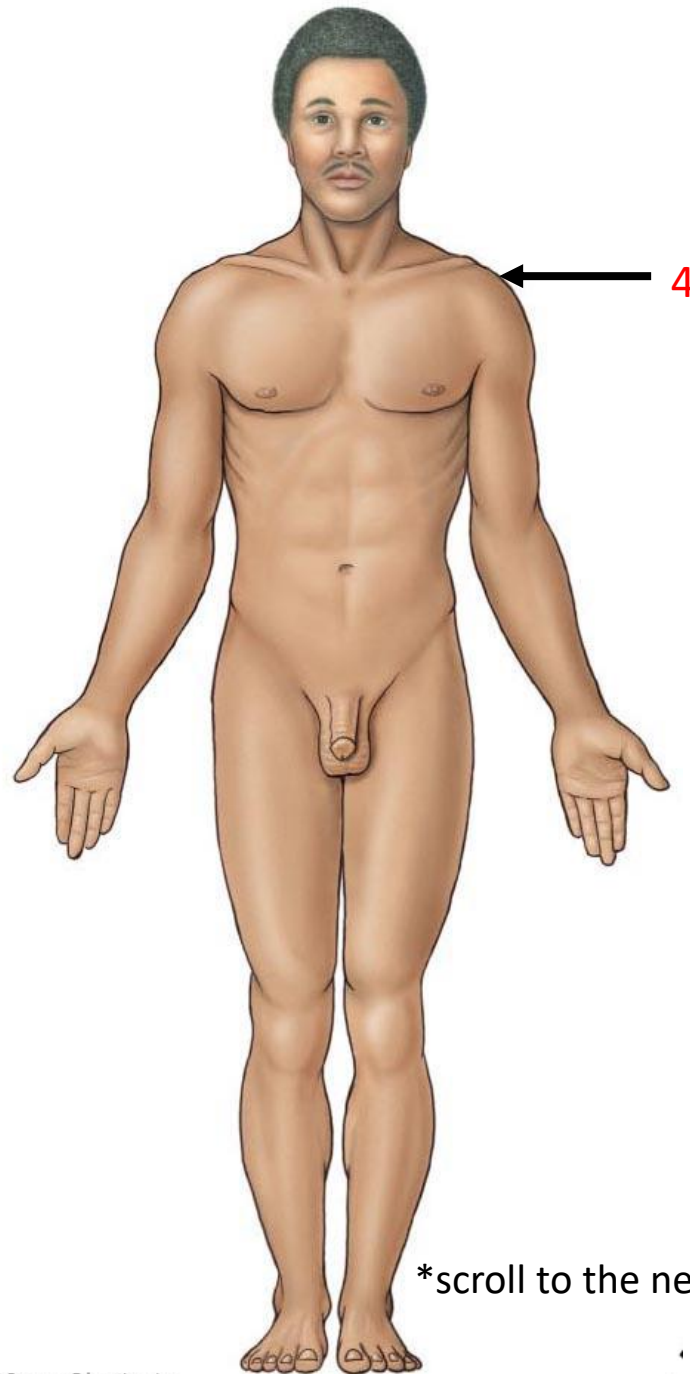


\*scroll to the next slide to check your answer

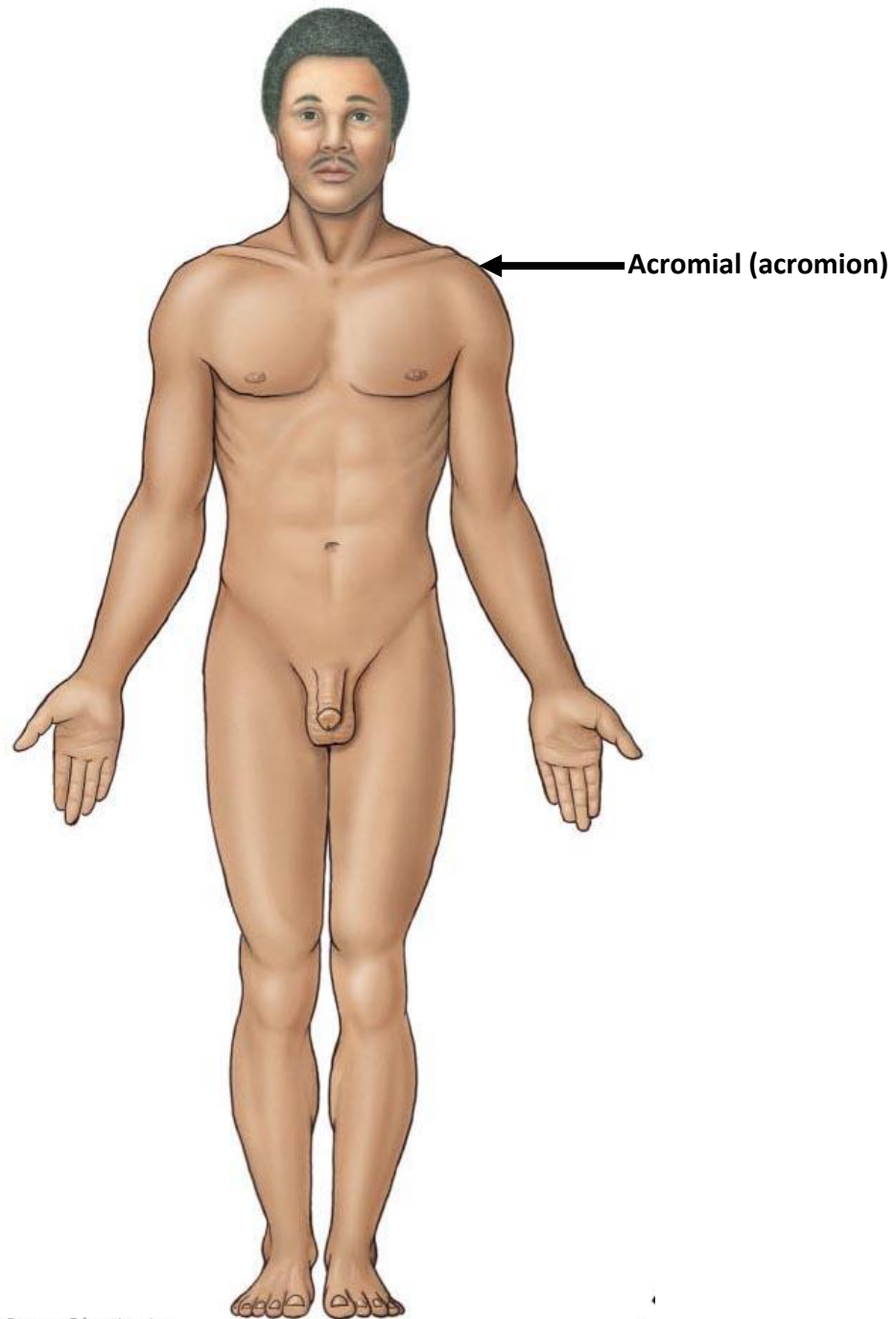
**Abdominal (abdomen)** —

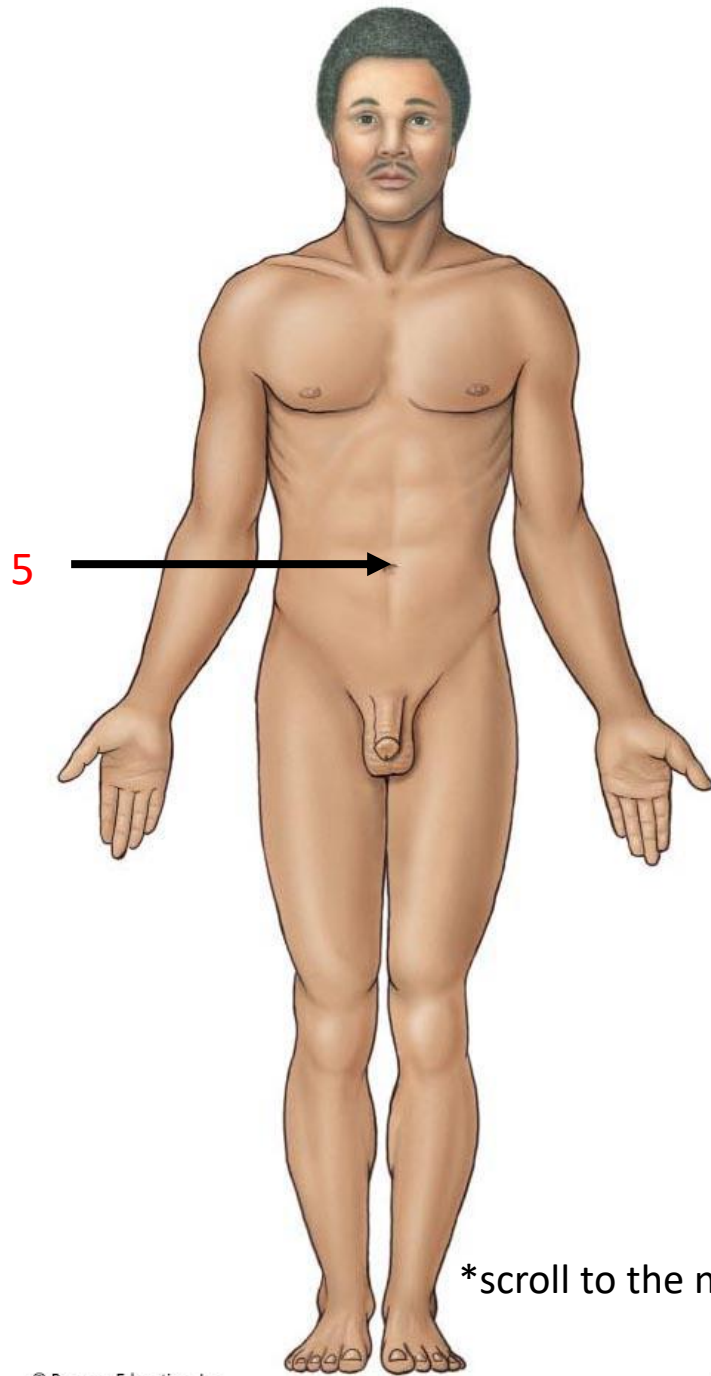






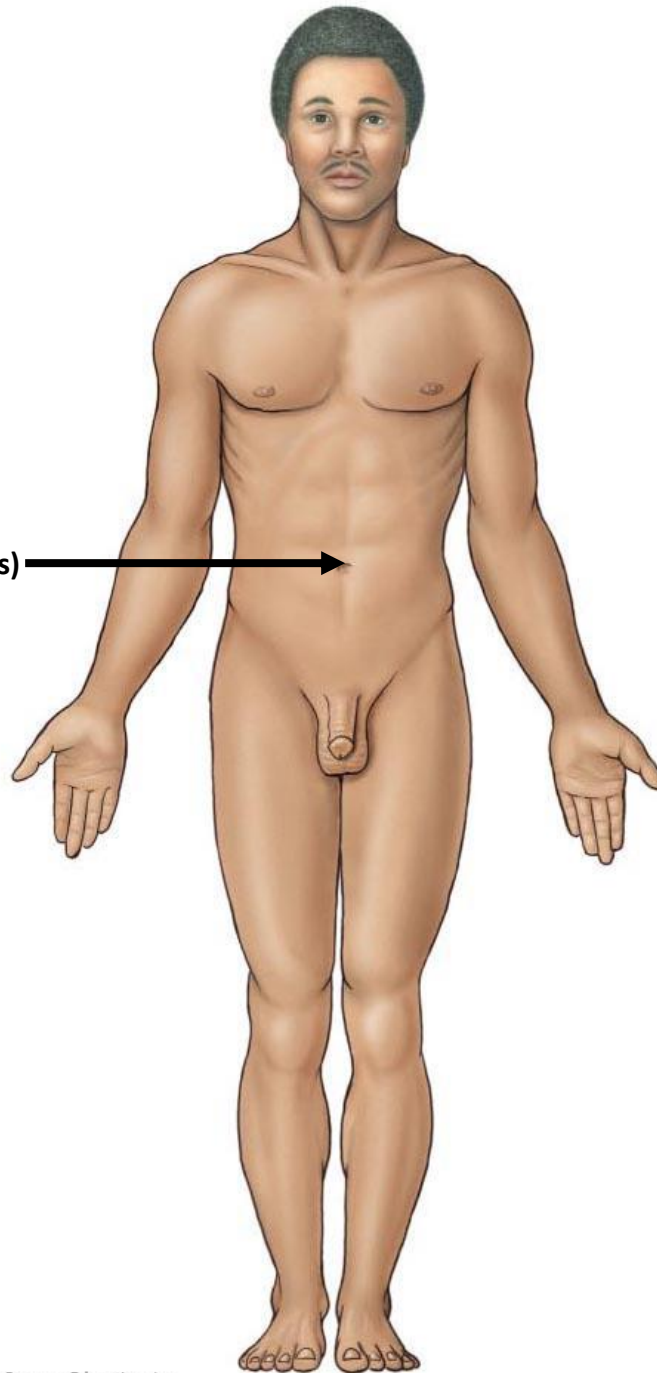
\*scroll to the next slide to check your answer

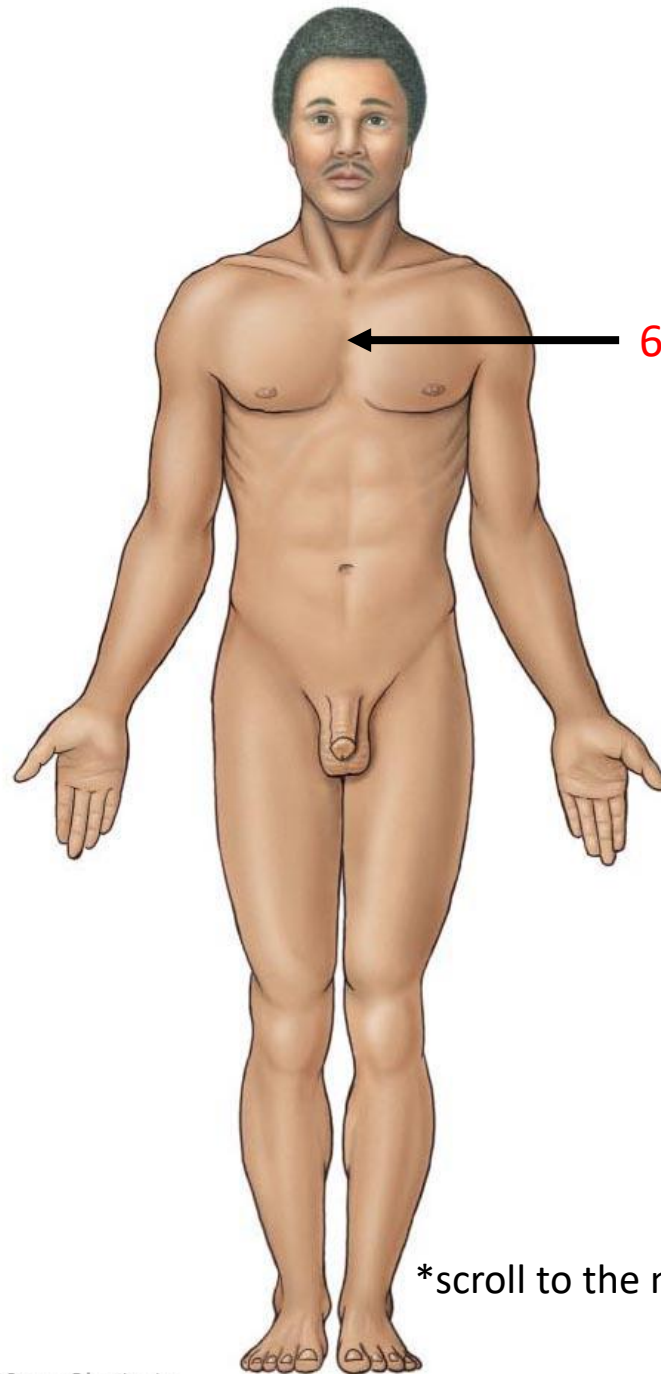




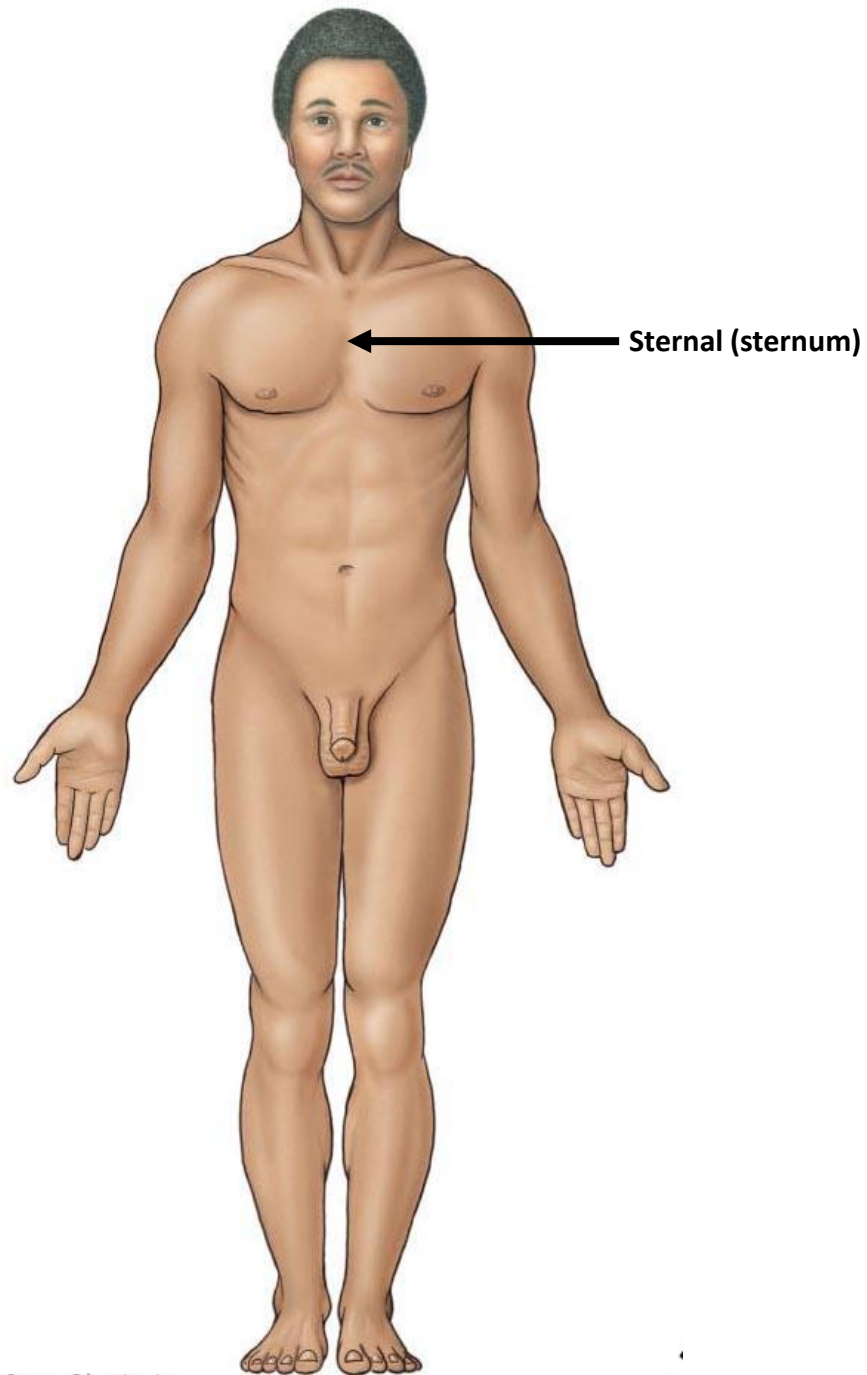
\*scroll to the next slide to check your answer

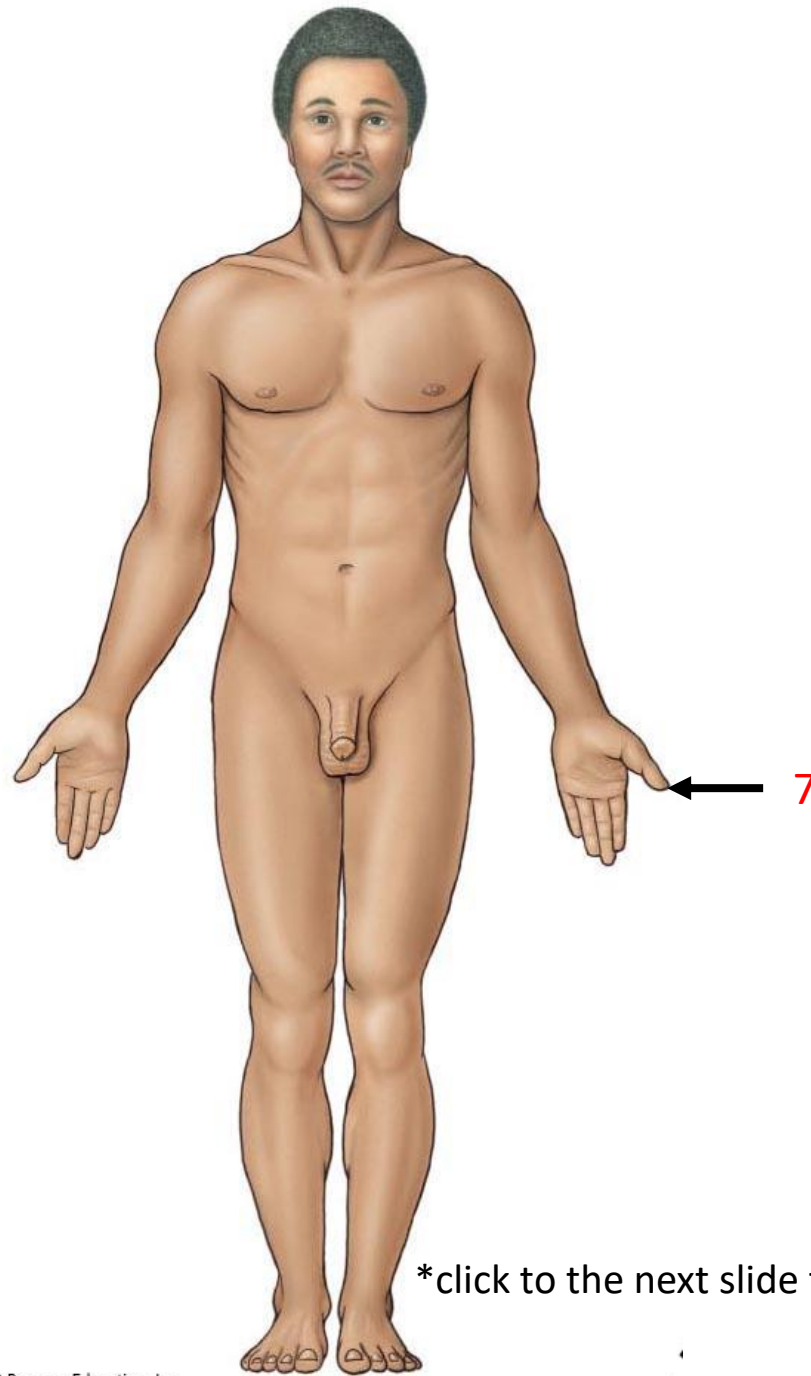
**Umbilical (umbilicus)** →



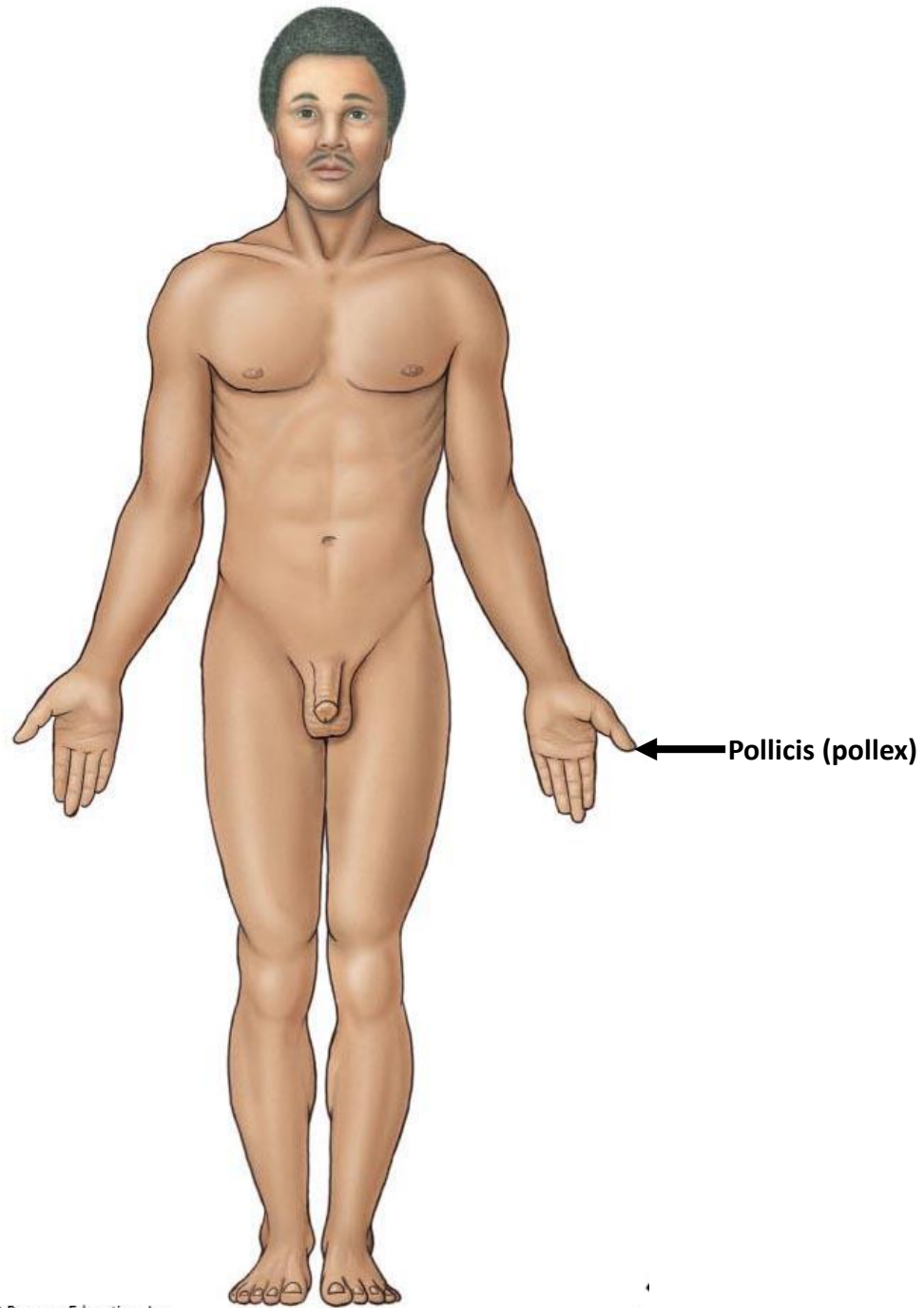


\*scroll to the next slide to check your answer



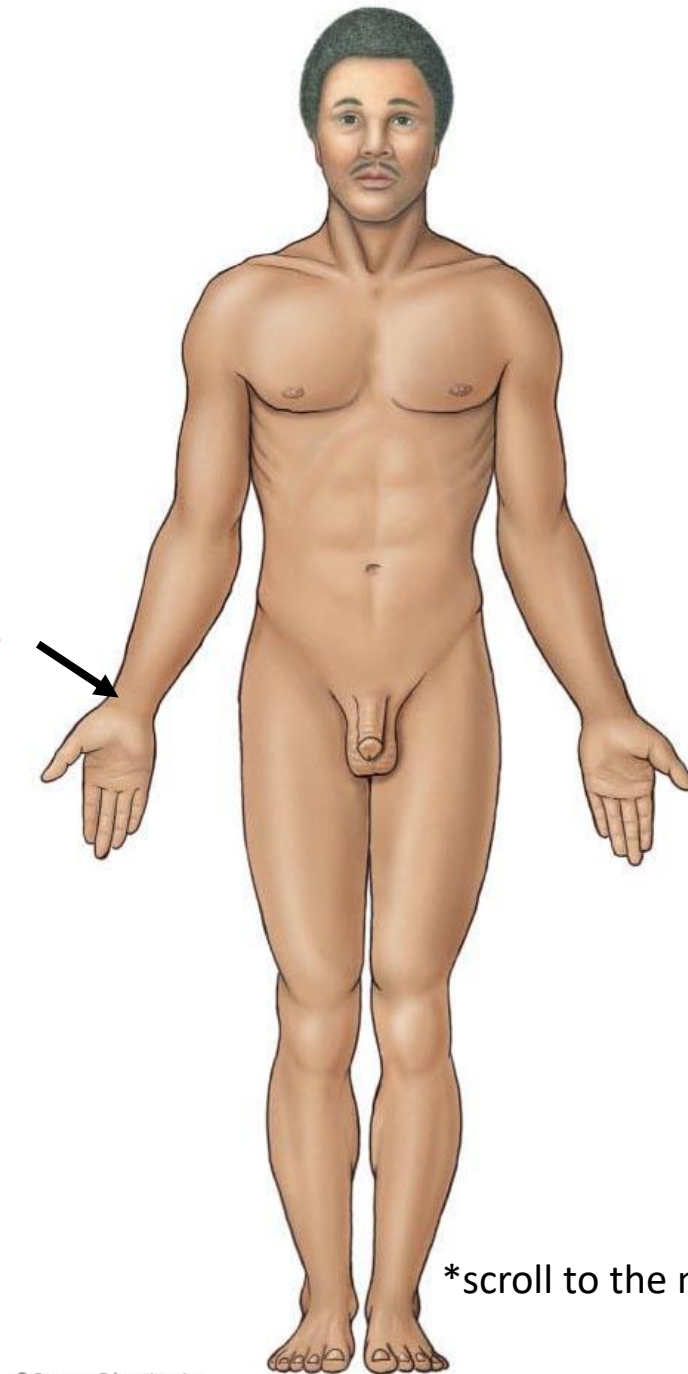


\*click to the next slide to check your answer



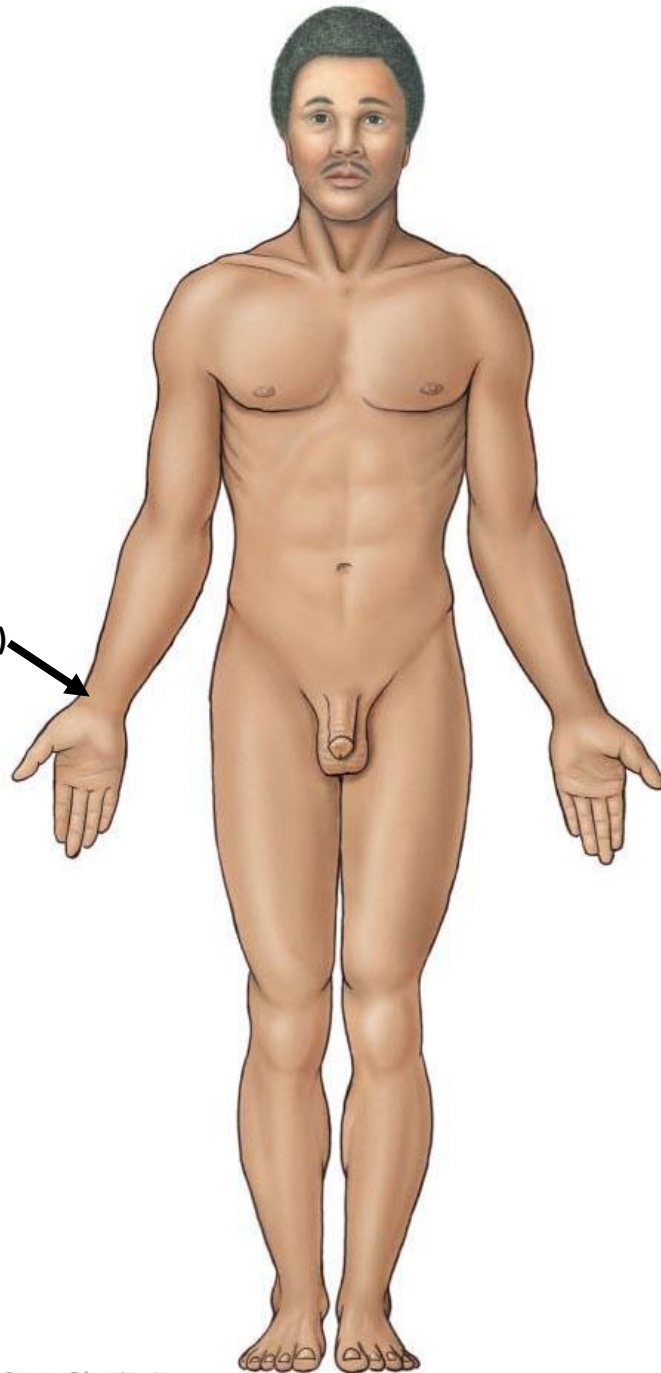


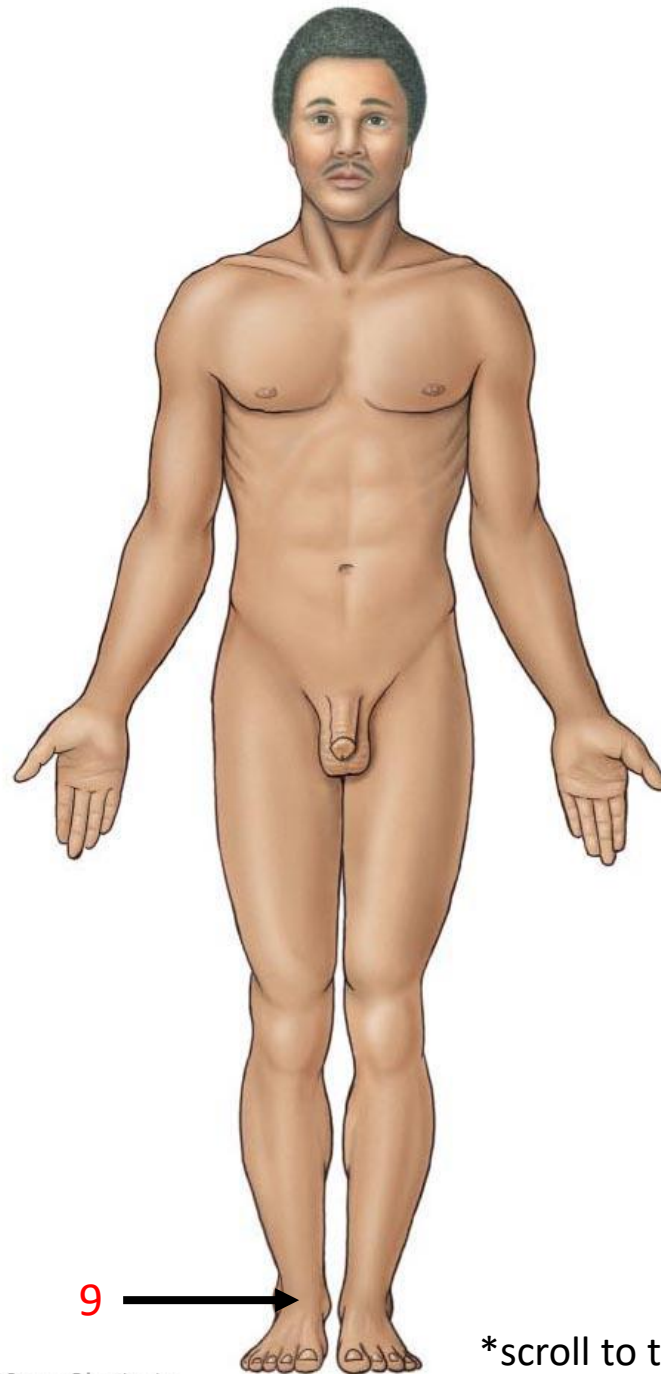
8

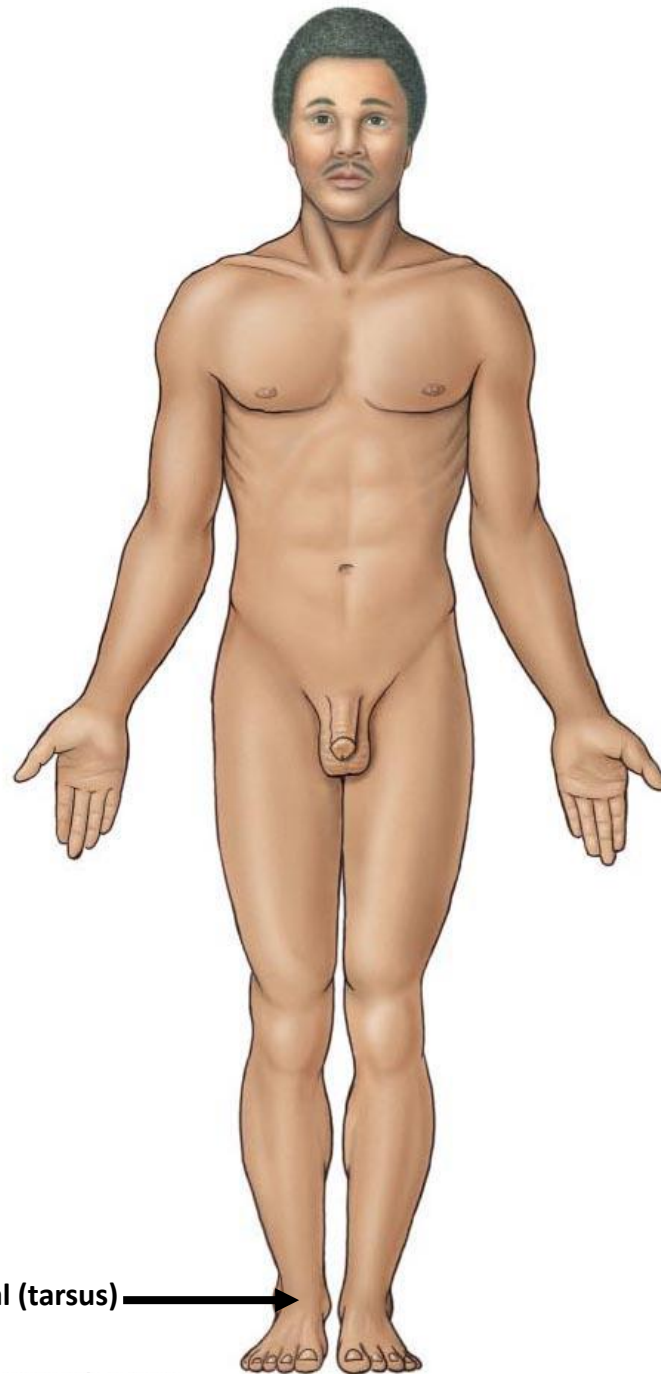


\*scroll to the next slide to check your answer

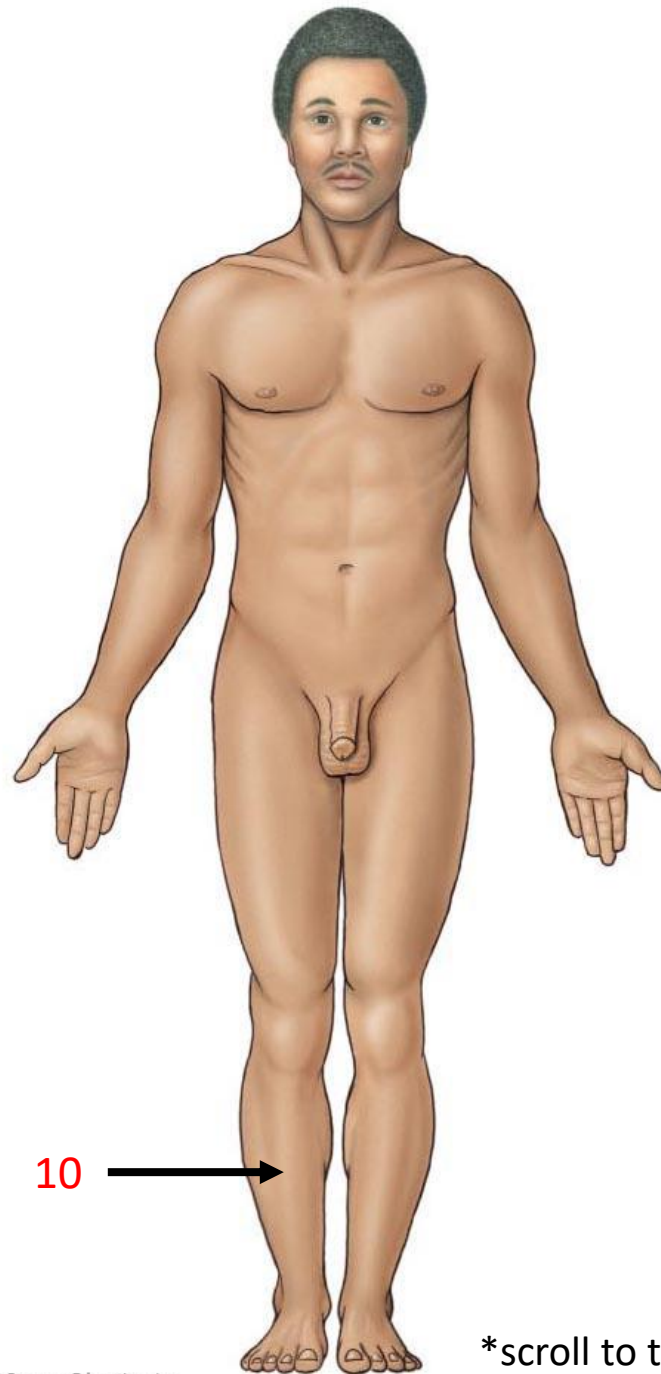
**Carpal (carpus)**

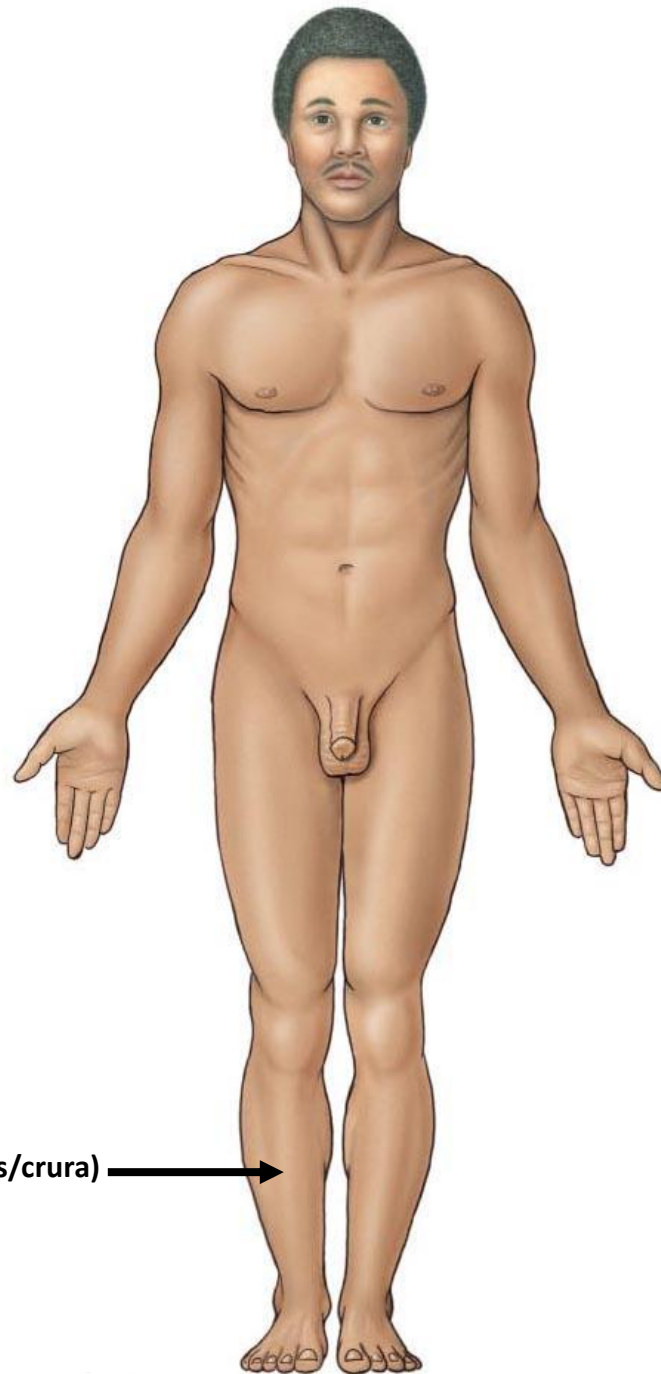




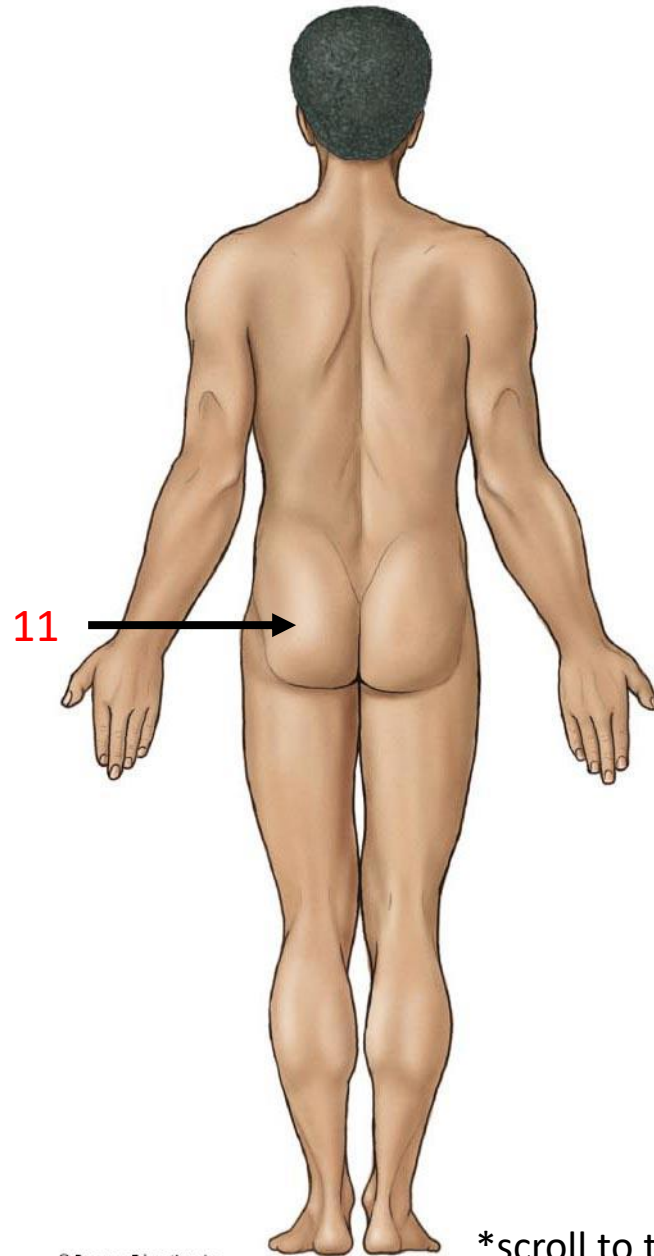


**Tarsal (tarsus)** →

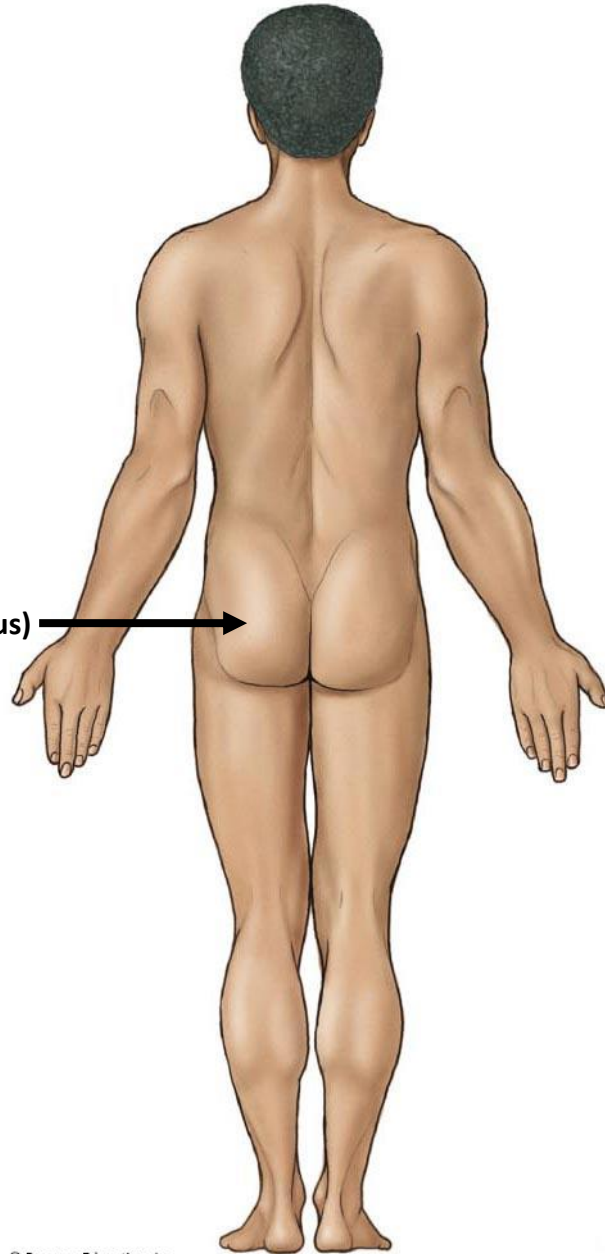




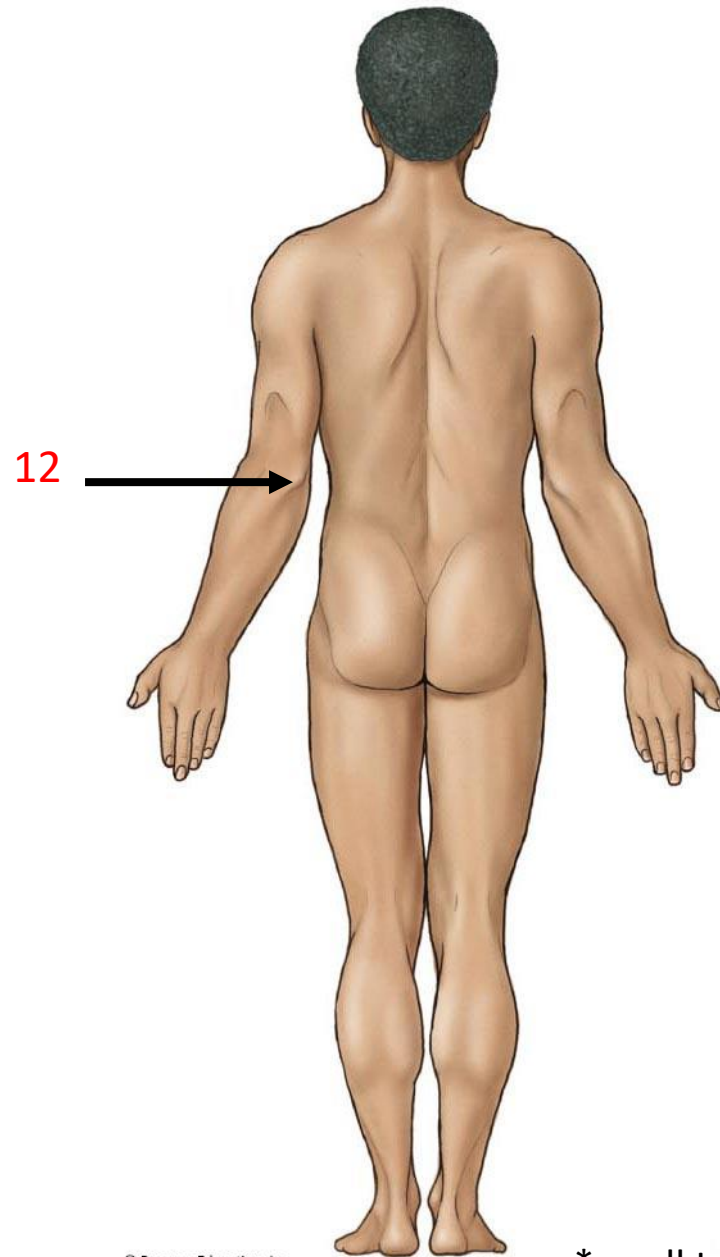
Crural (crus/crura) →



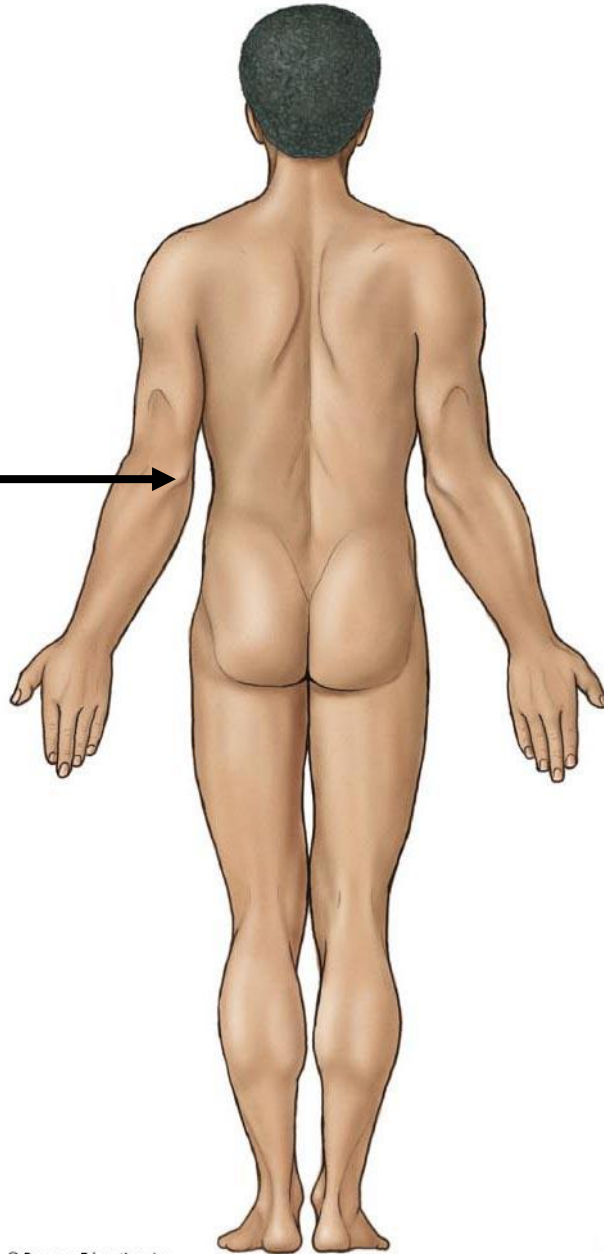
**Gluteal (gluteus)** →

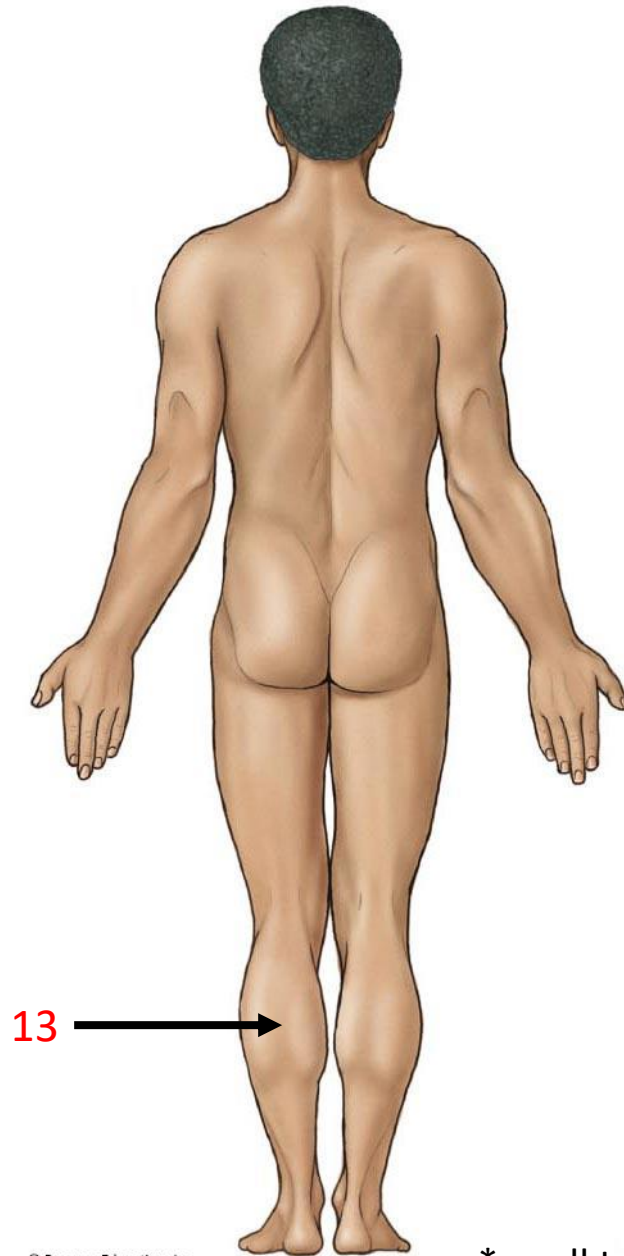


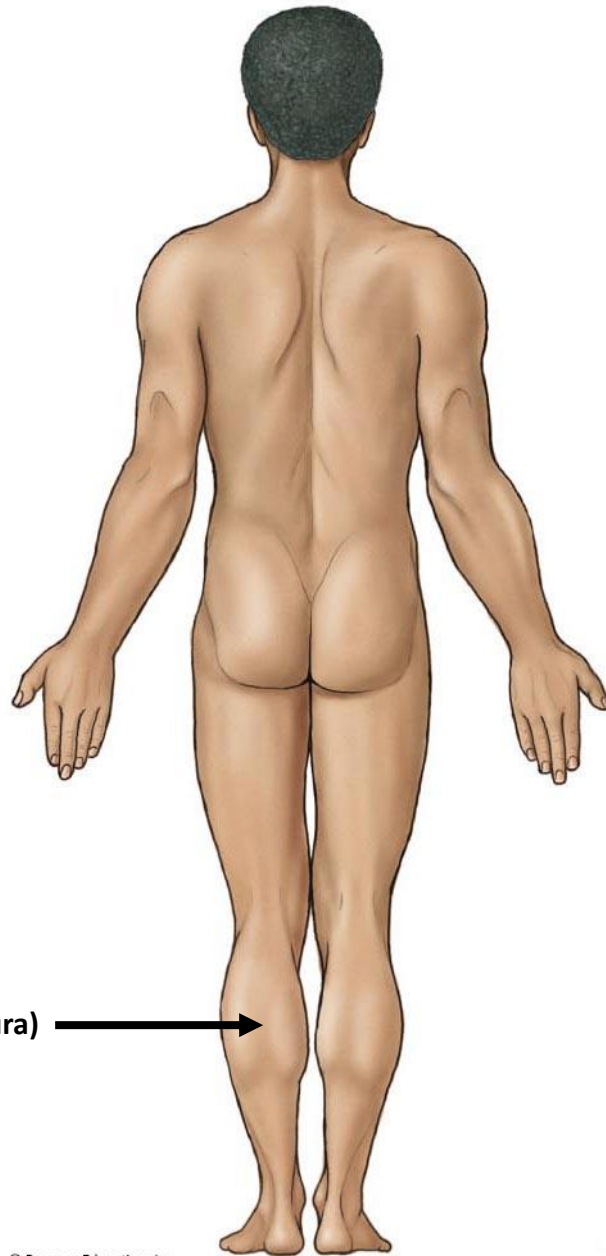




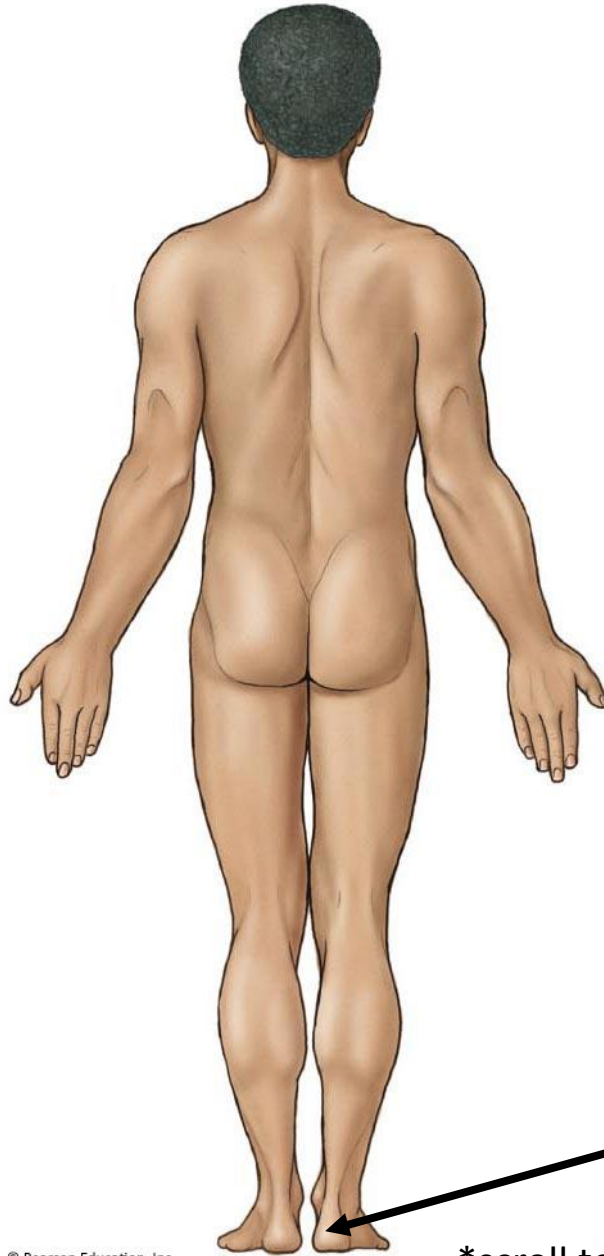
**Olecranal (olecranon)** →







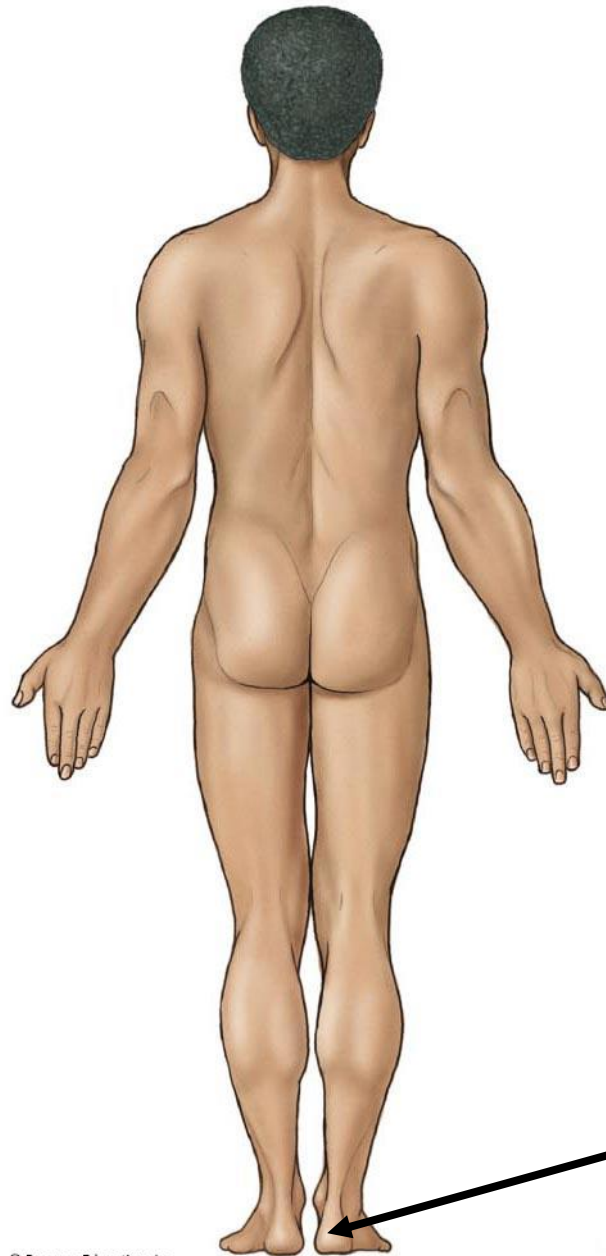
**Sural (sura)** →



© Pearson Education, Inc

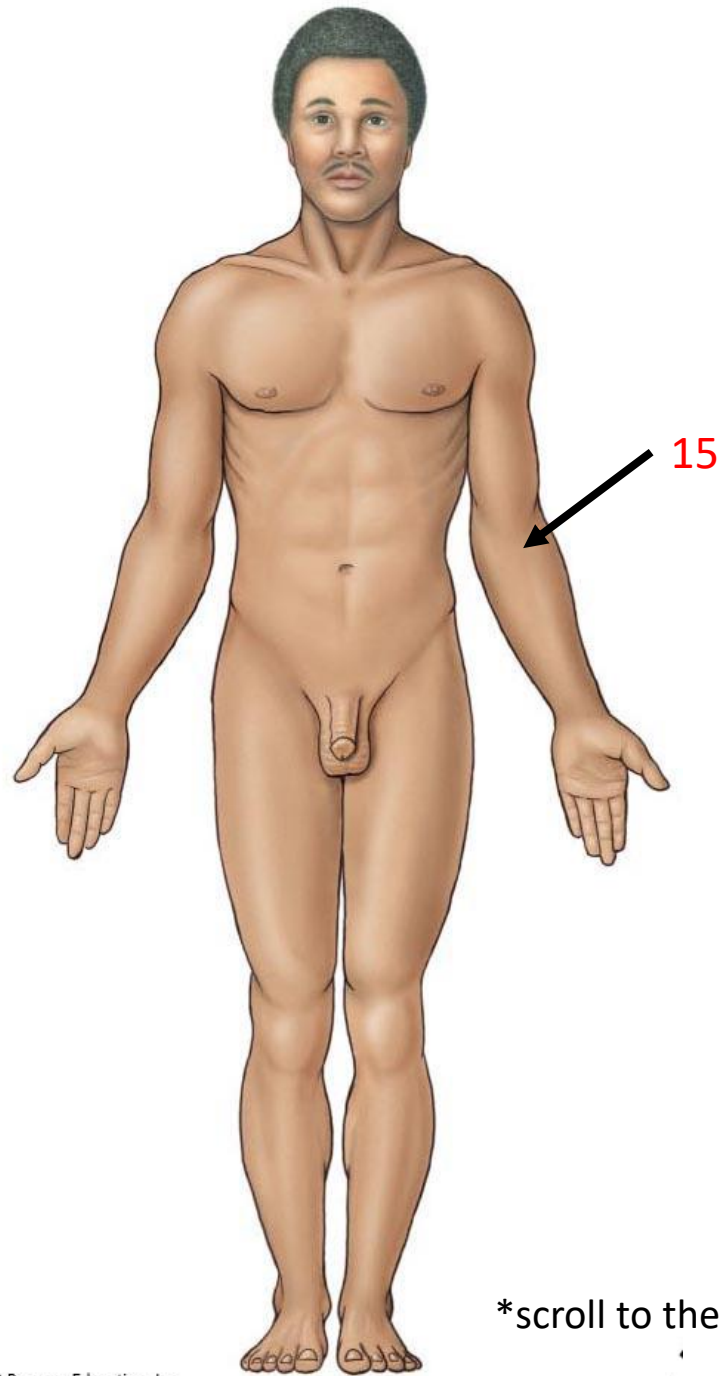
14

\*scroll to the next slide to check your answer

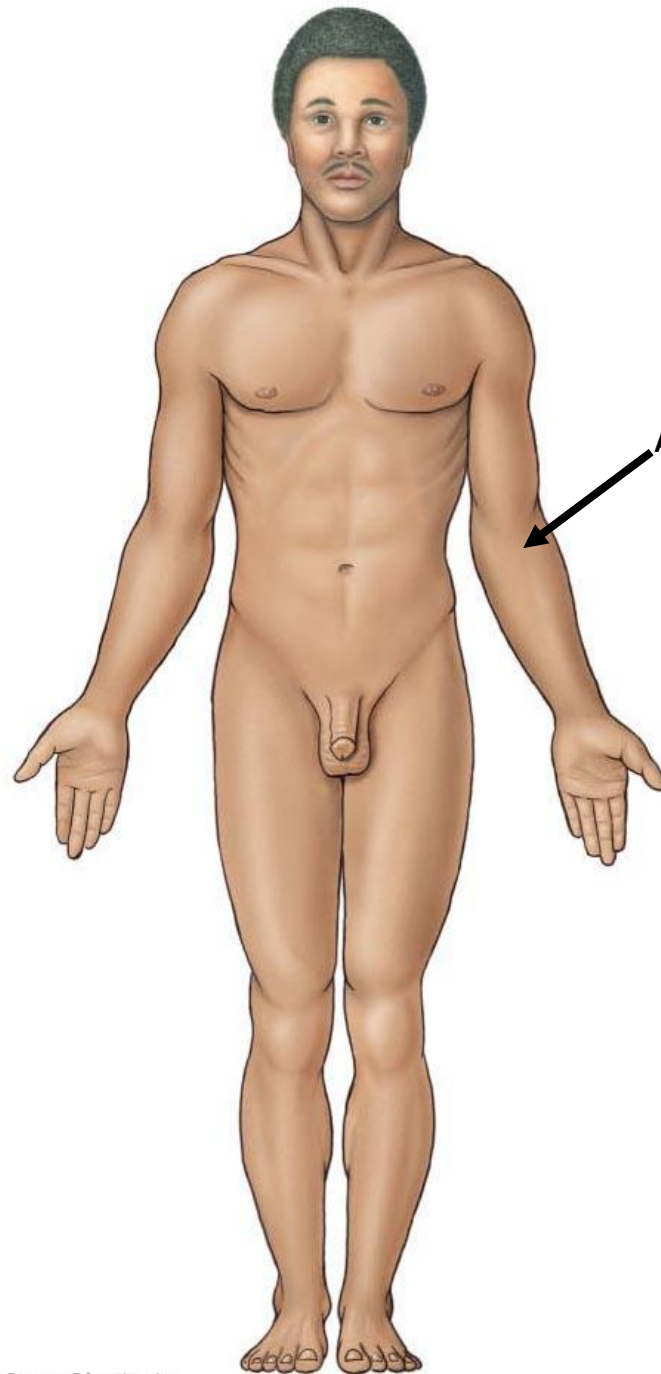


**Calcaneal (calcaneus)**





\*scroll to the next slide to check your answer



Antecubital (antecubitus)