

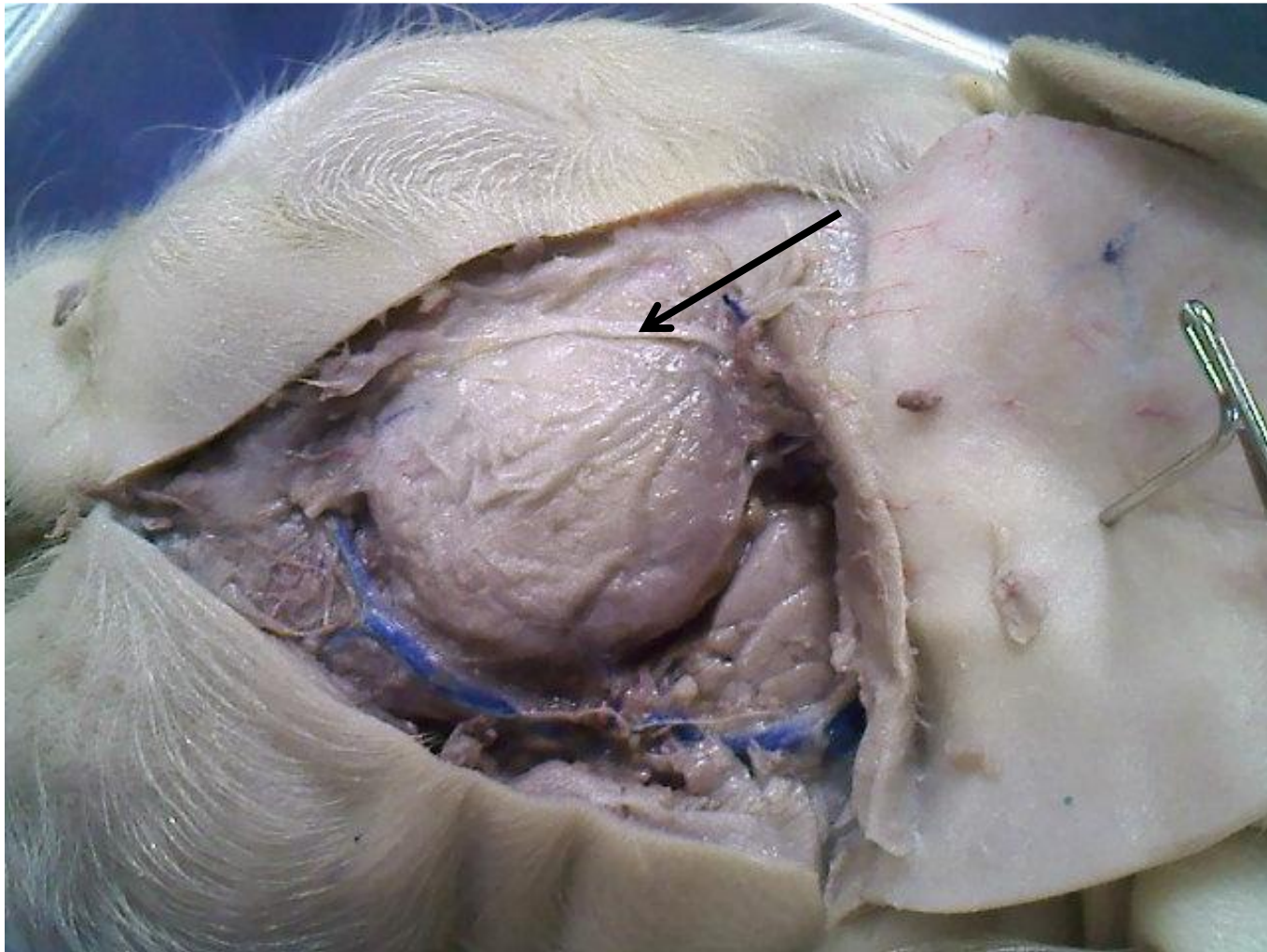
Fetal Pig Practice Exam

#1

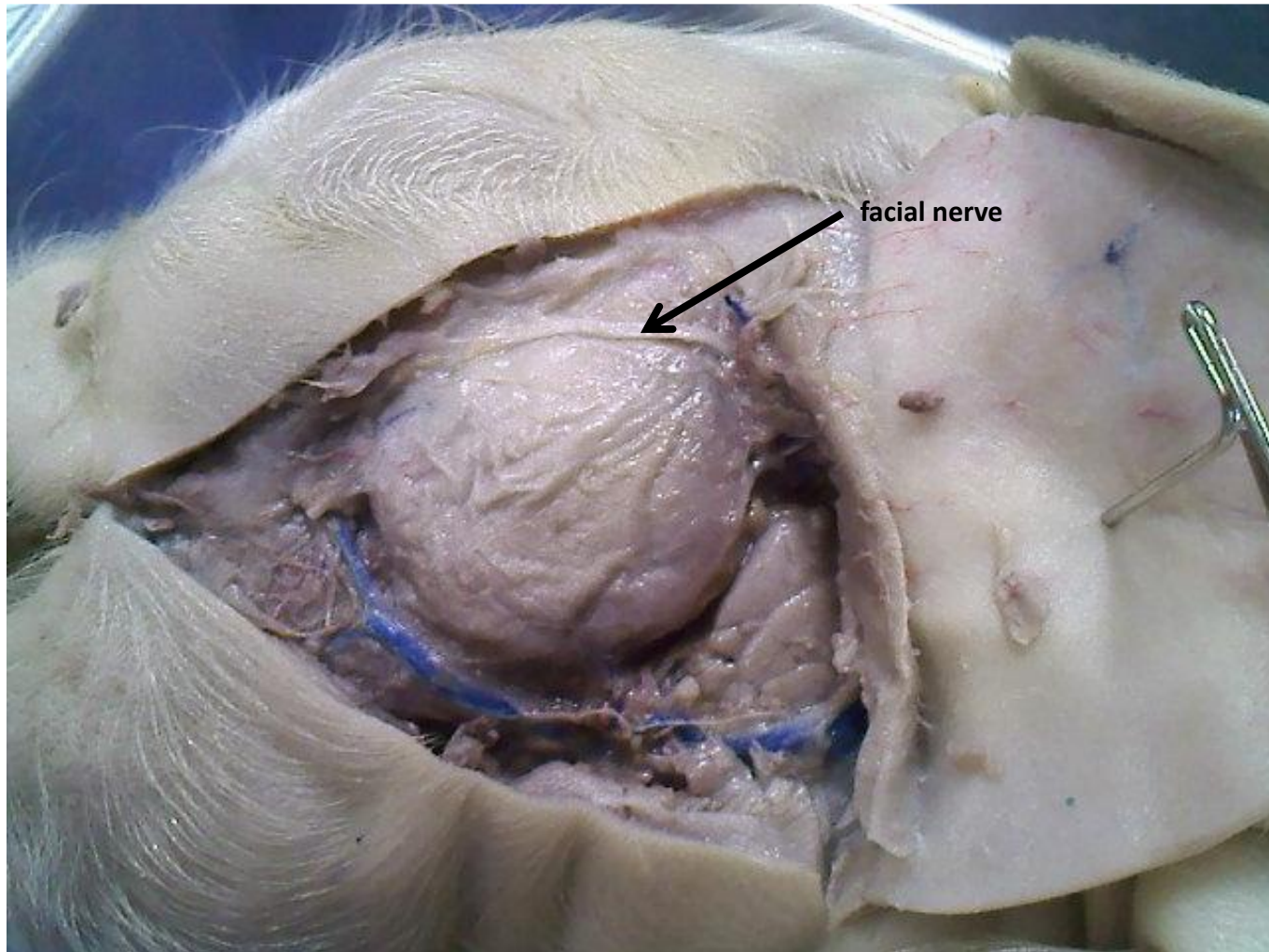
Name the following structures indicated by the arrows.
Scroll to the next slide to see the answer.

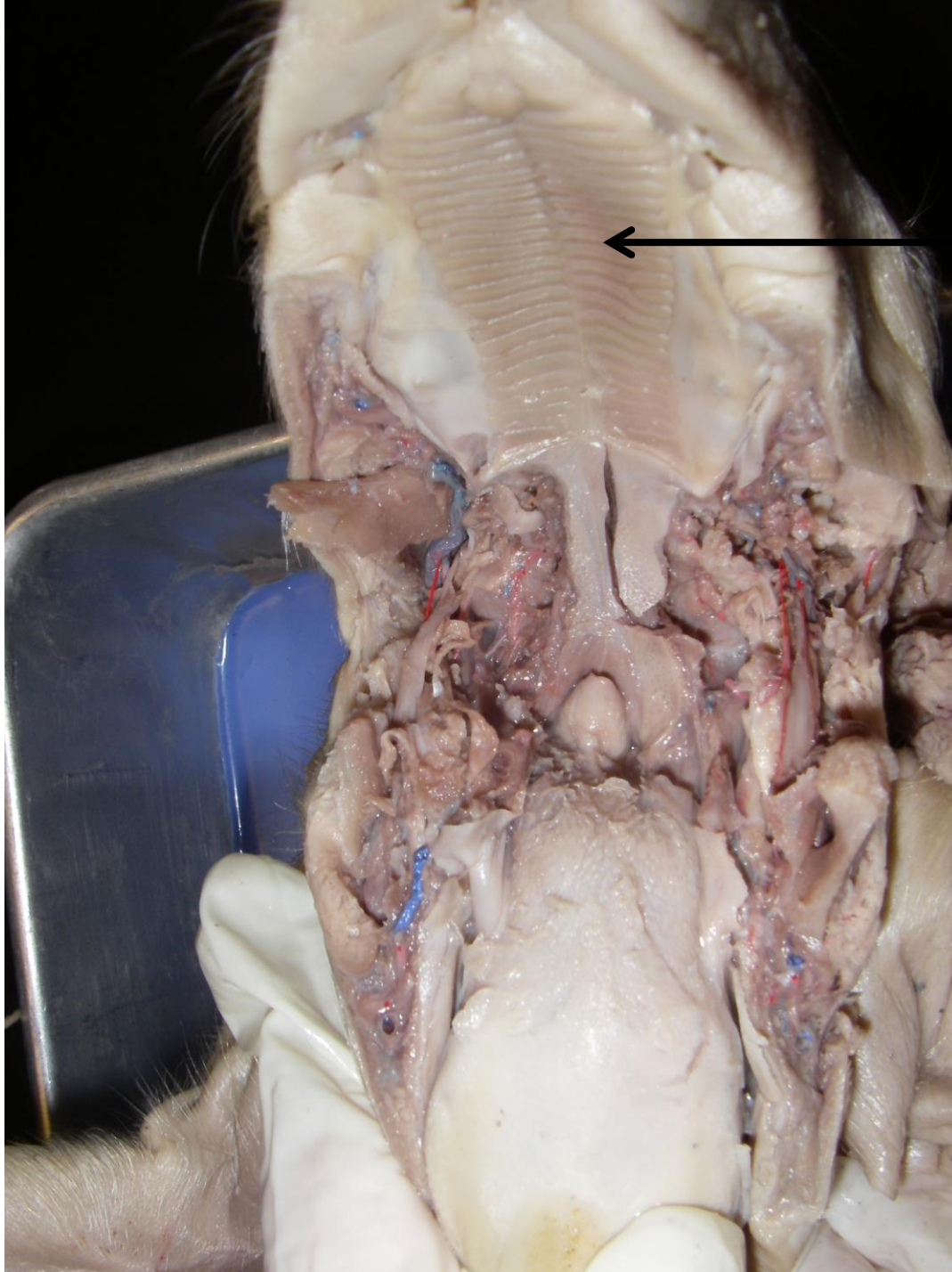
*For best results on these practice exams, write your answers on paper before scrolling to see the correct answer. Try to answer within a minute (remember your lab exams will be timed) and make sure to check your spelling!

*note: not every structure you are required to know will be on this practice exercise so make sure you review the checklist of structures (p. 178-179 in your lab manual) when preparing for your lab exam

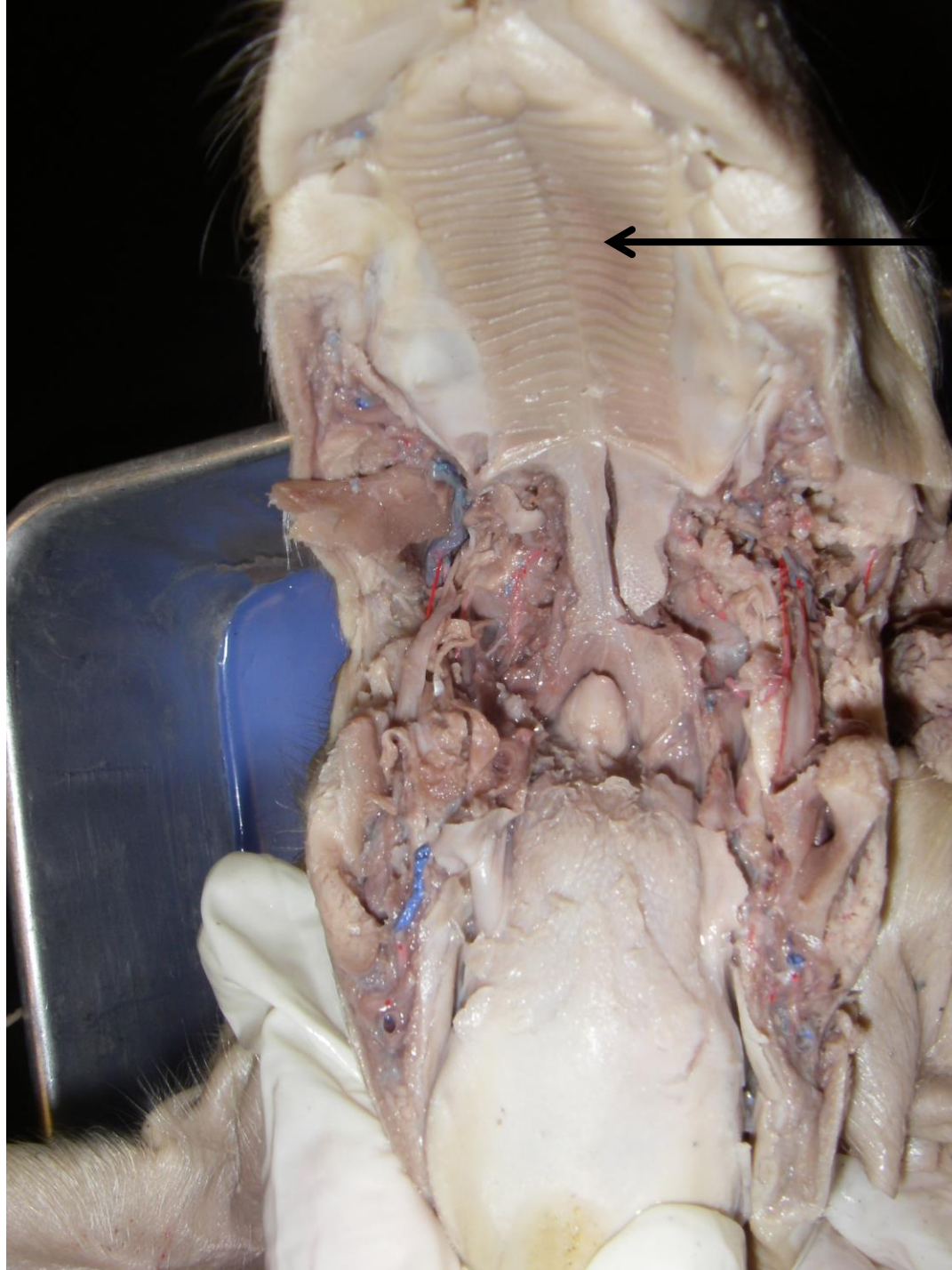


*scroll to the next slide to check your answer

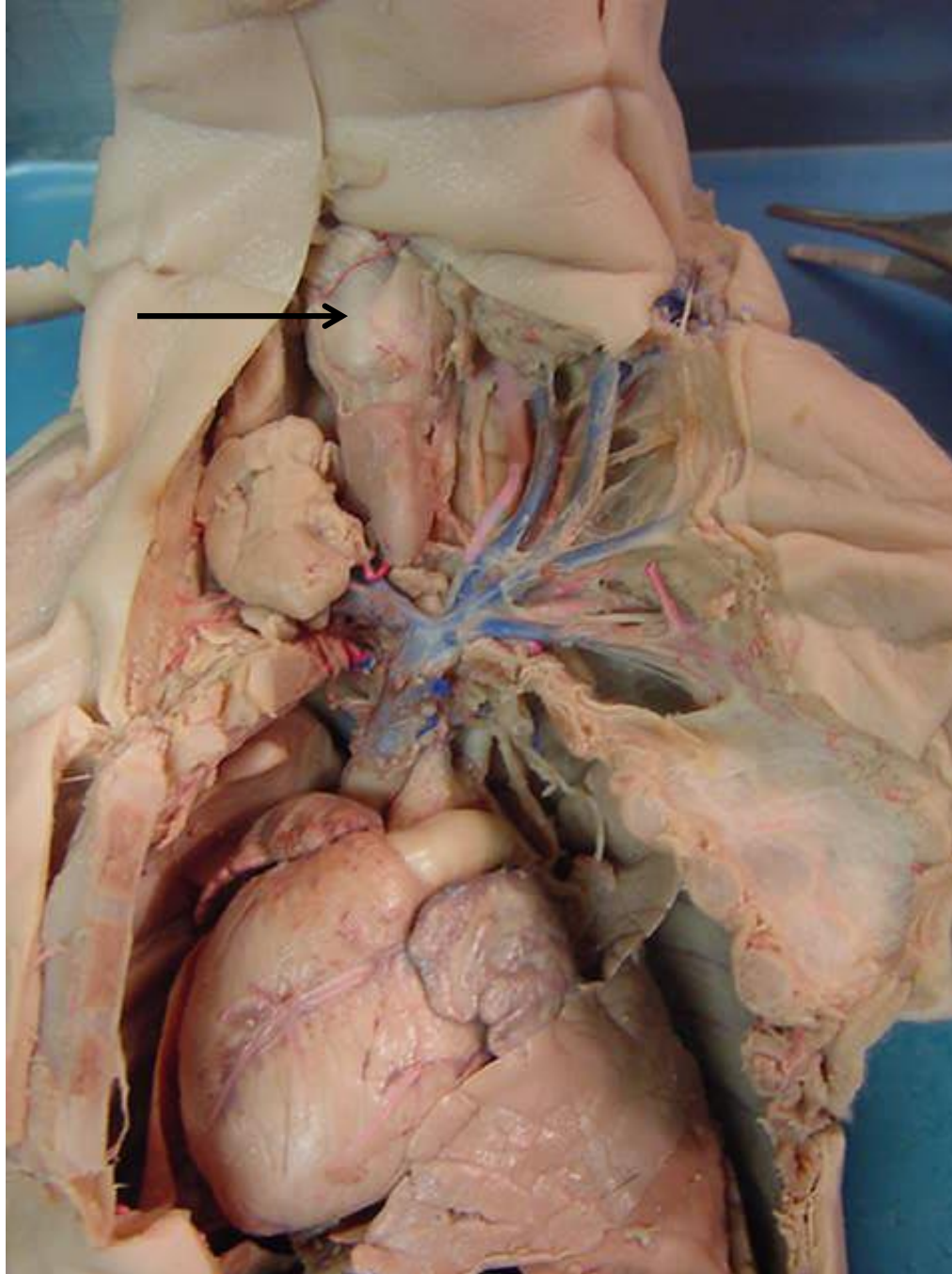




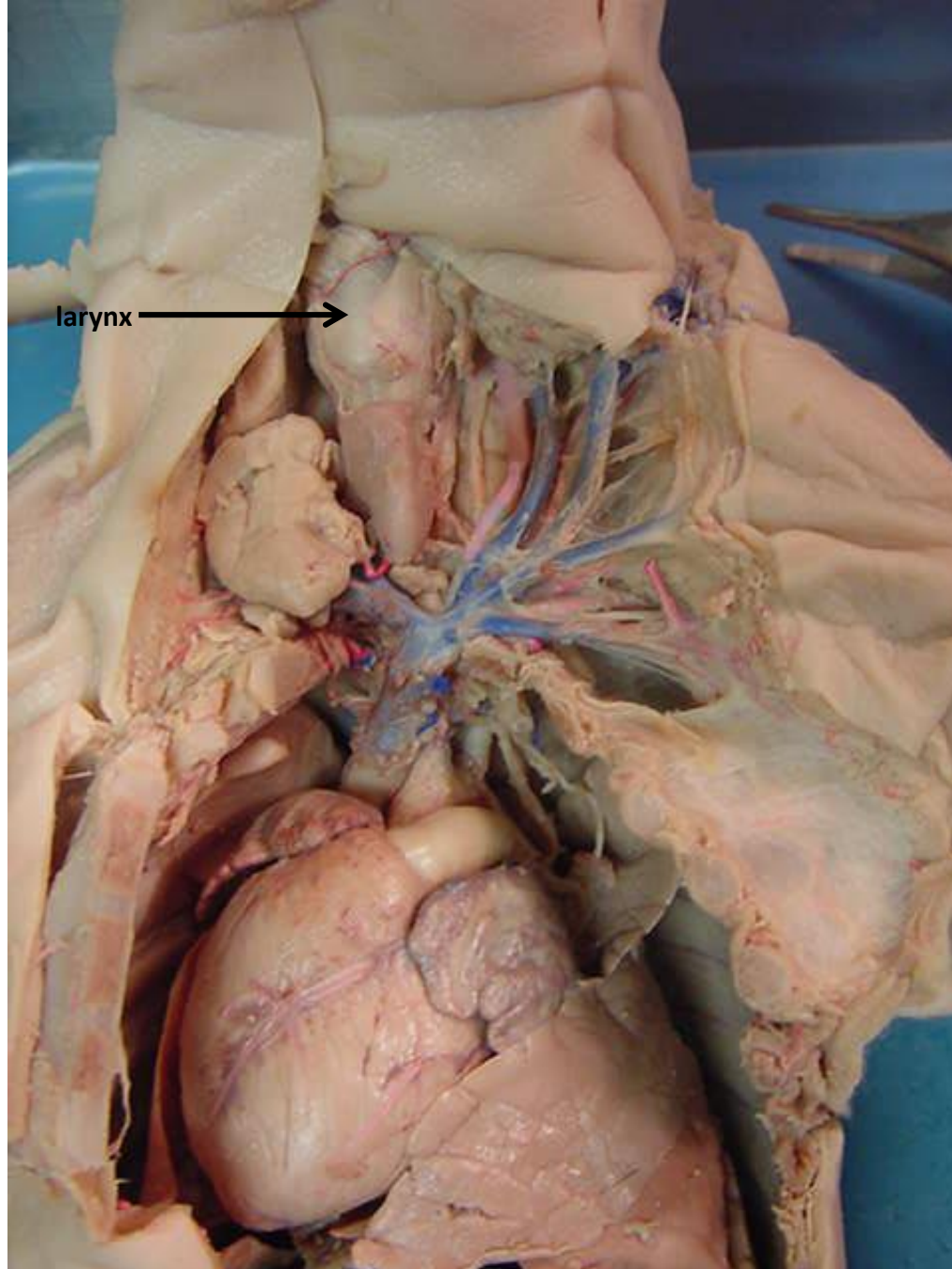
*scroll to the next
slide to check your
answer

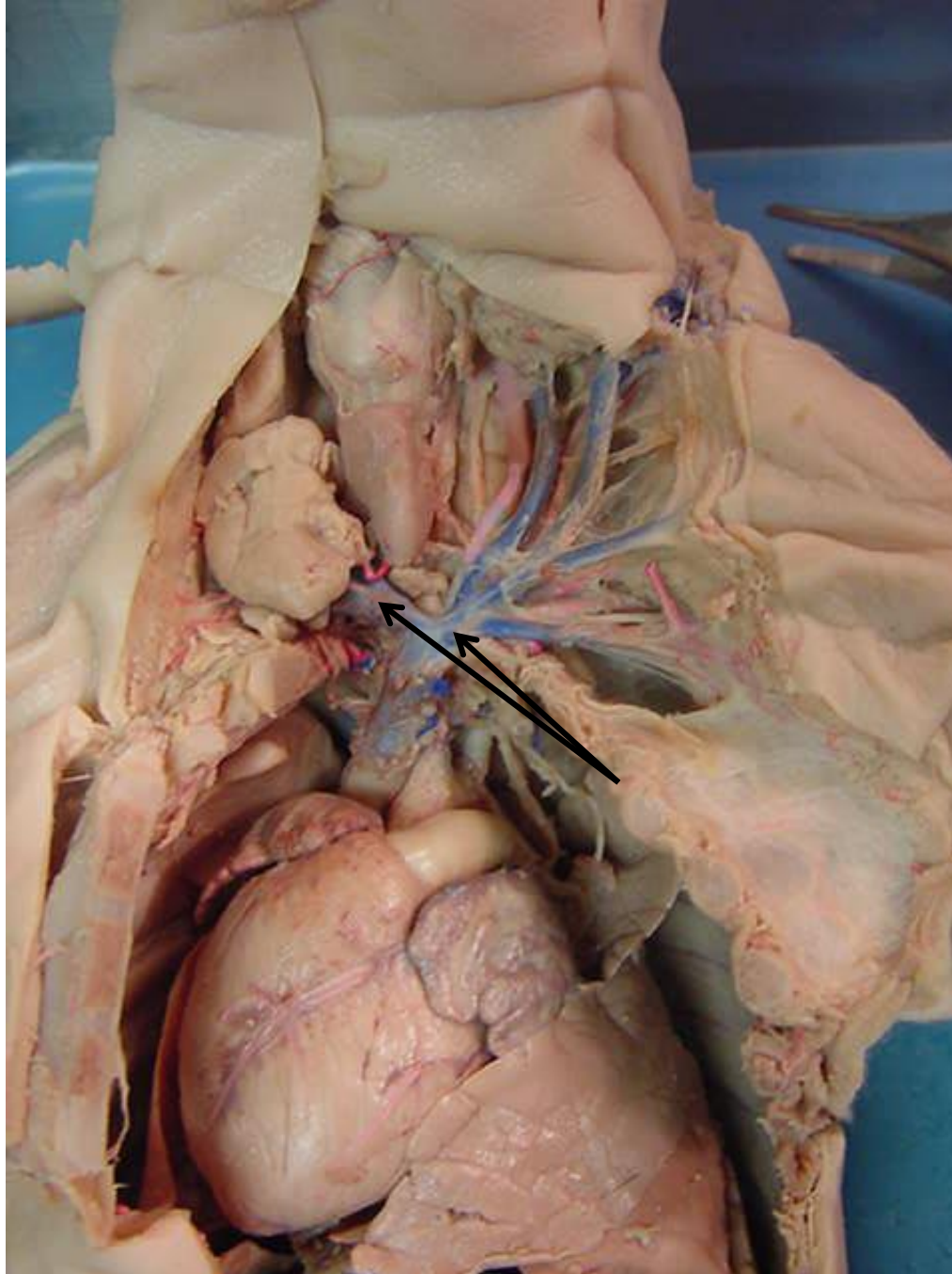


hard palate

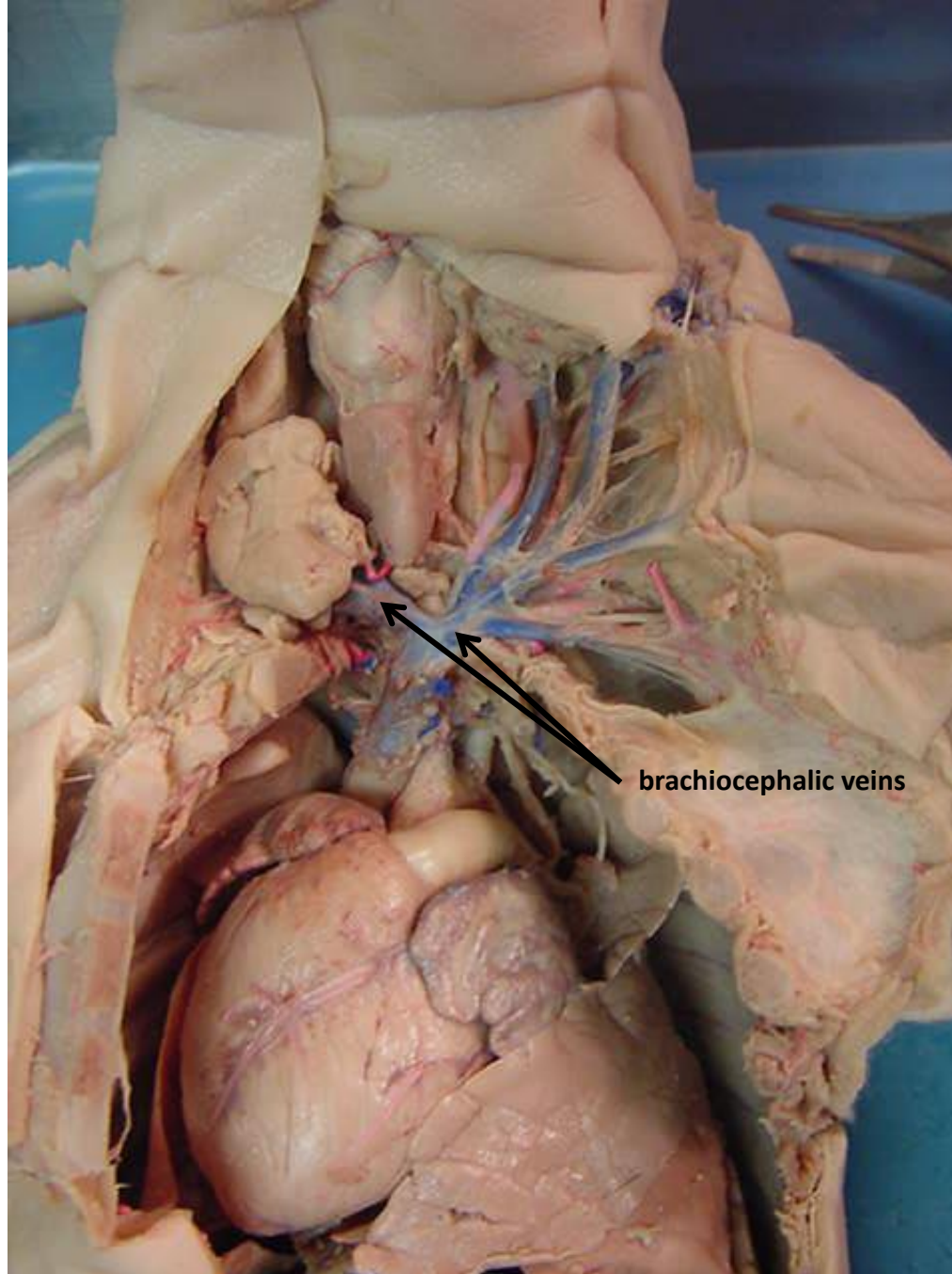


*scroll to the next
slide to check your
answer

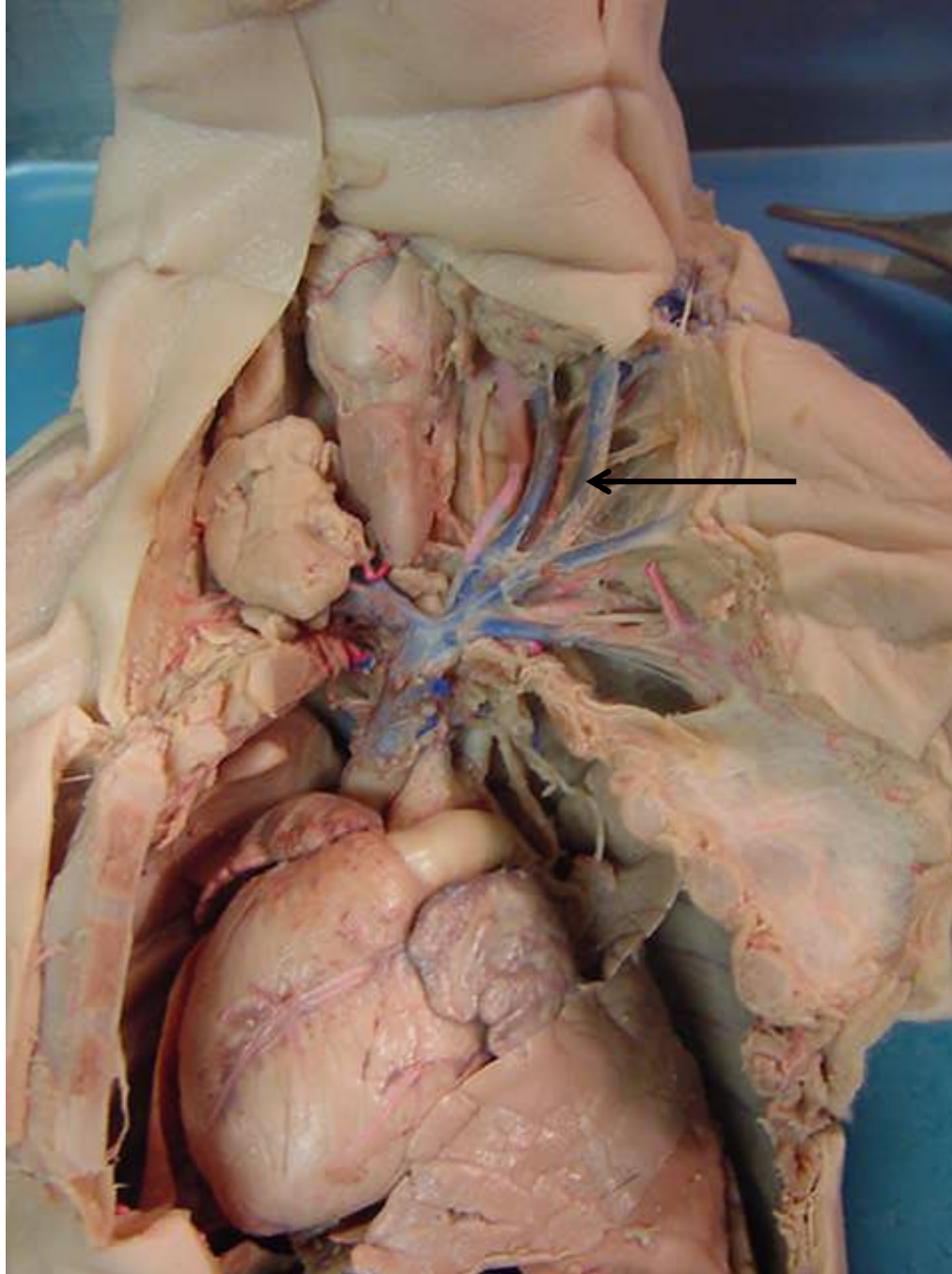




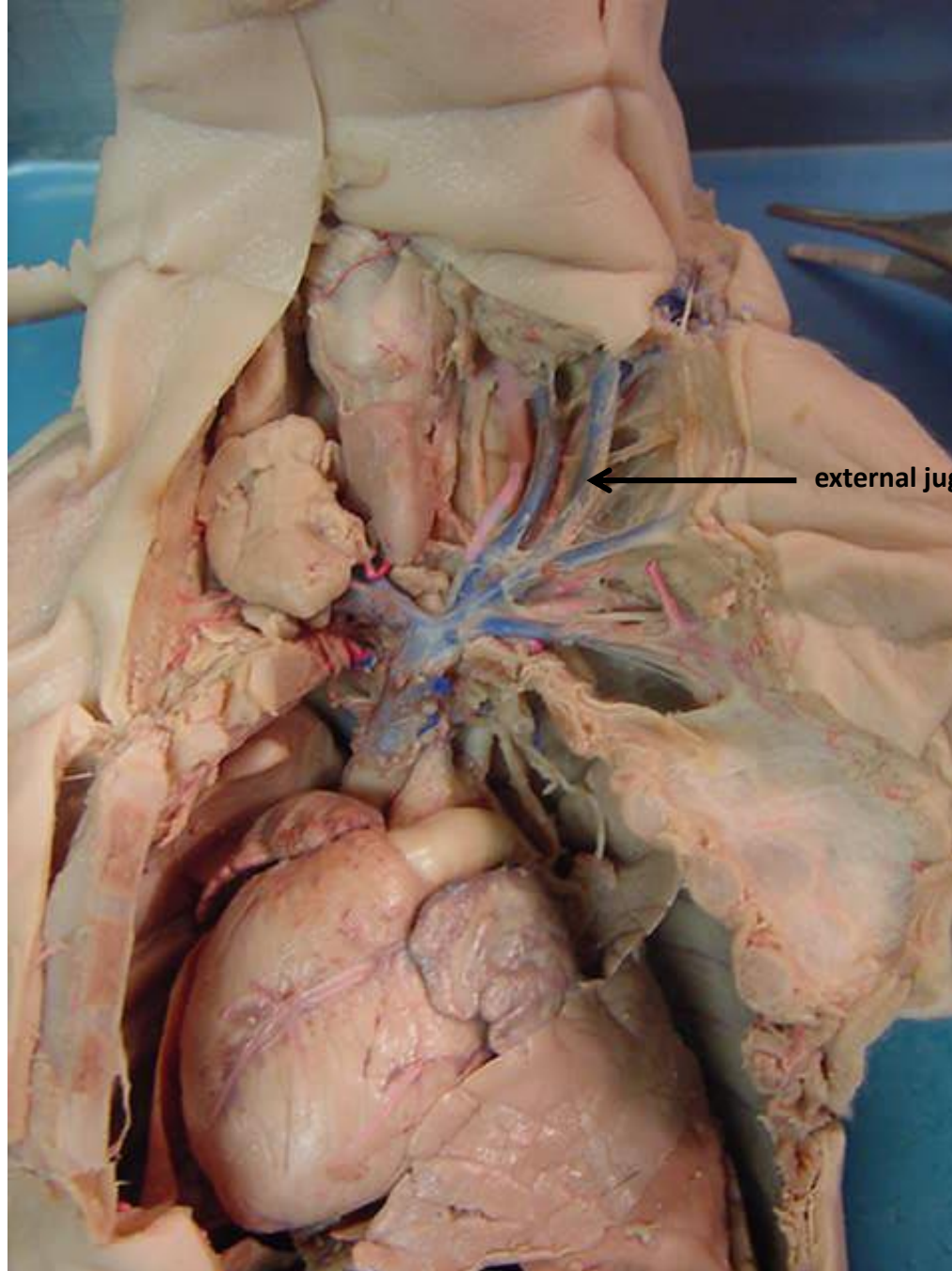
*scroll to the
next slide to
check your
answer



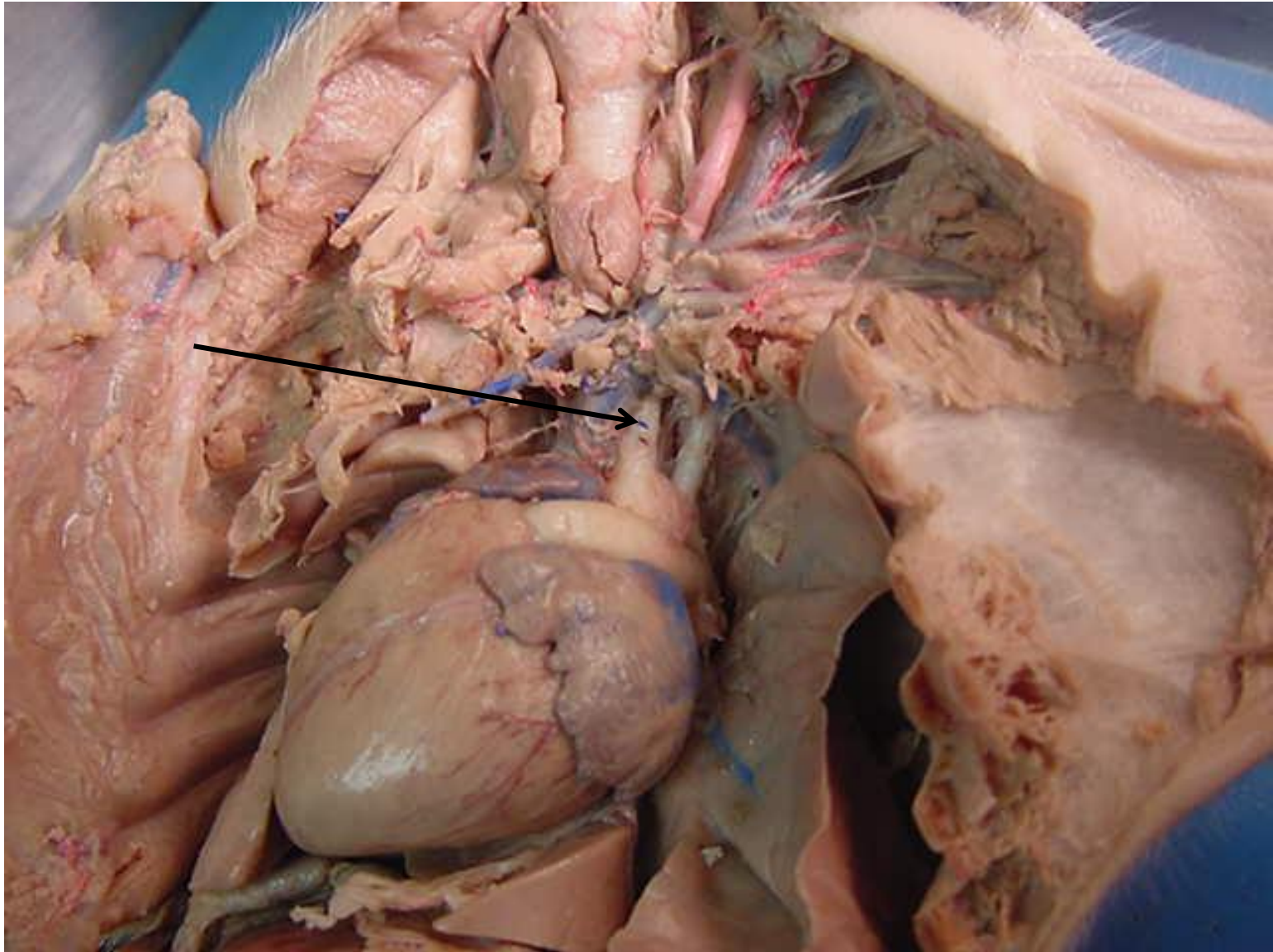
brachiocephalic veins



*scroll to the
next slide to
check your
answer

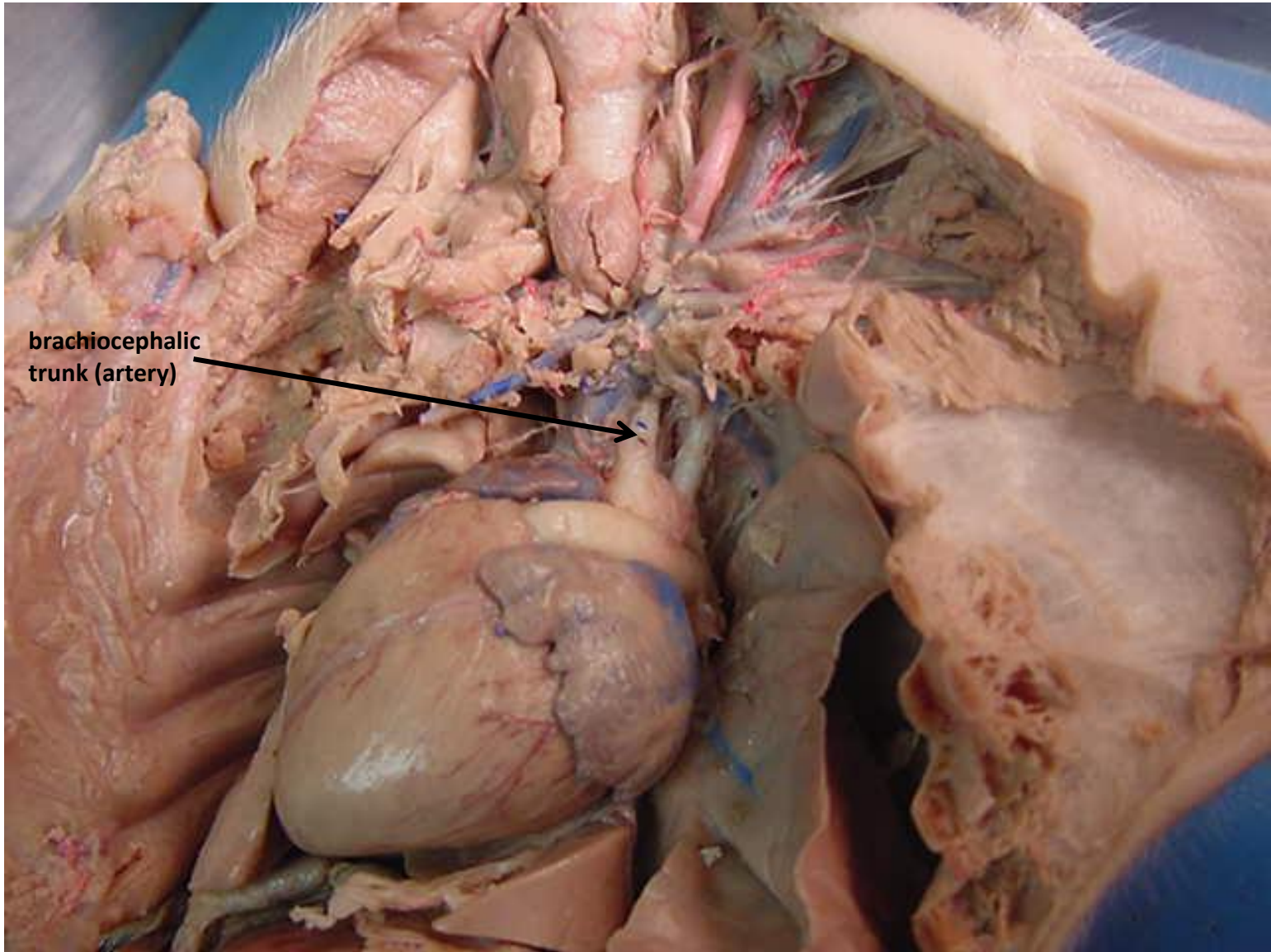


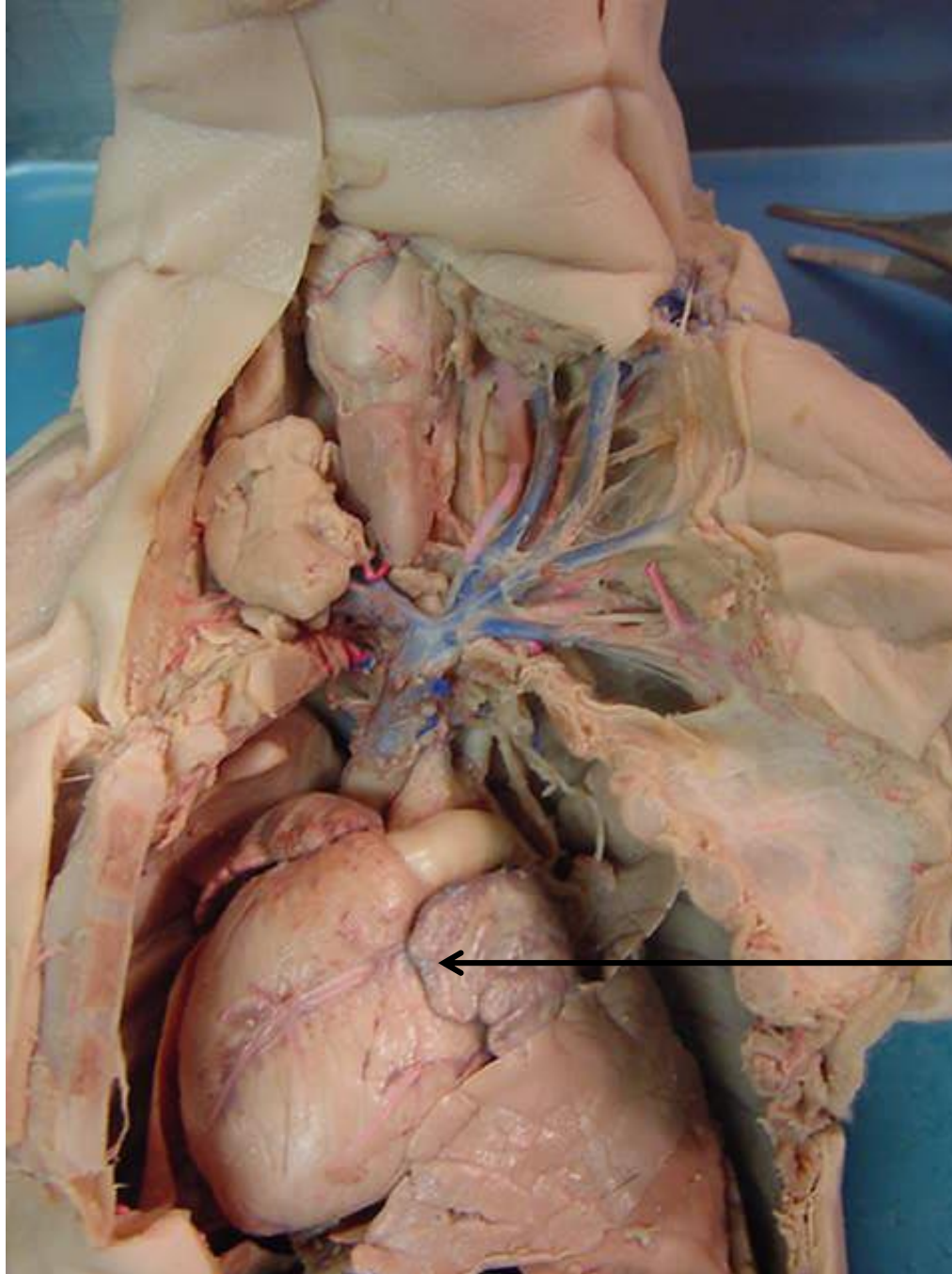
external jugular vein



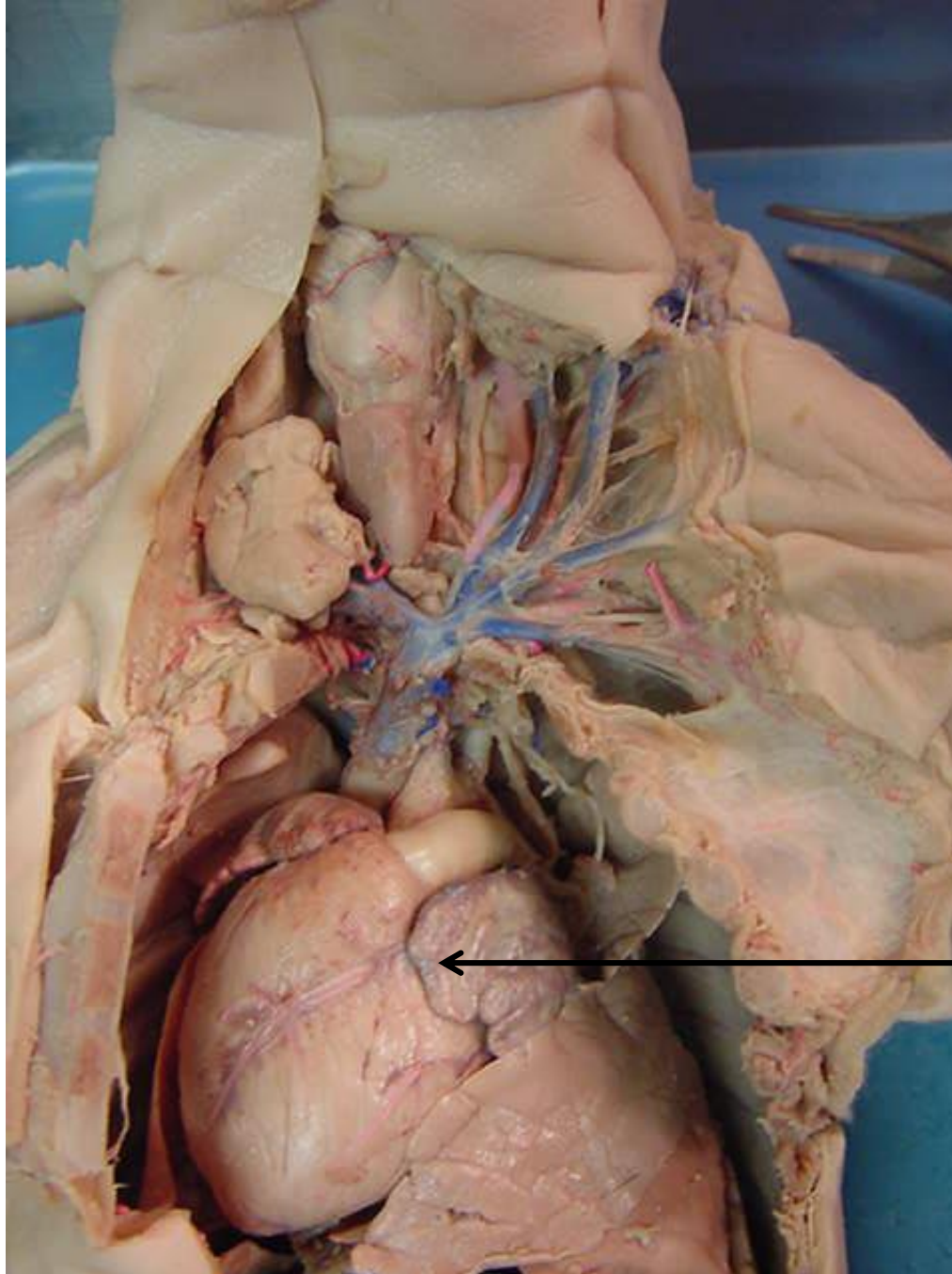
*scroll to the next slide to check
your answer

brachiocephalic
trunk (artery)

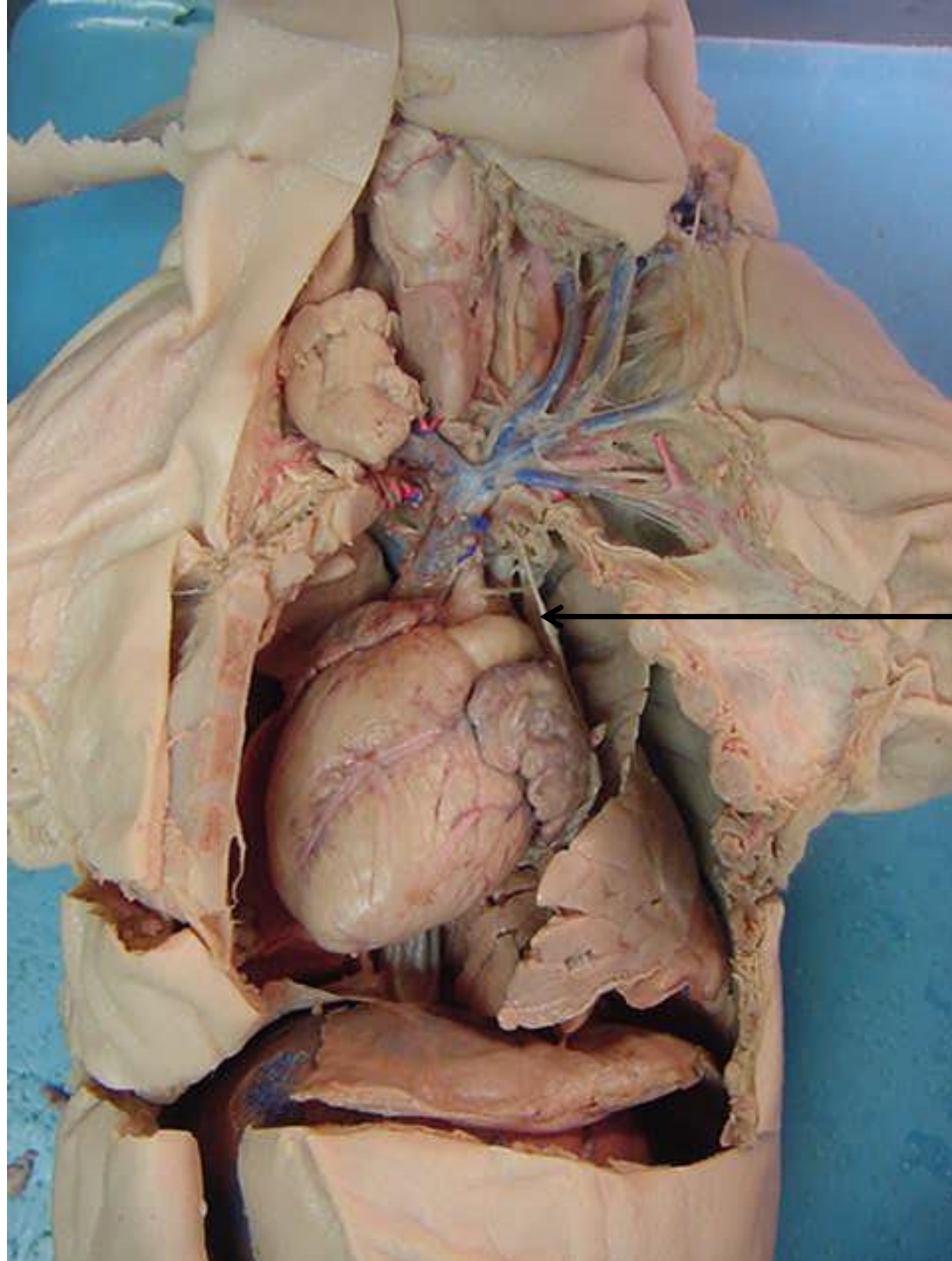




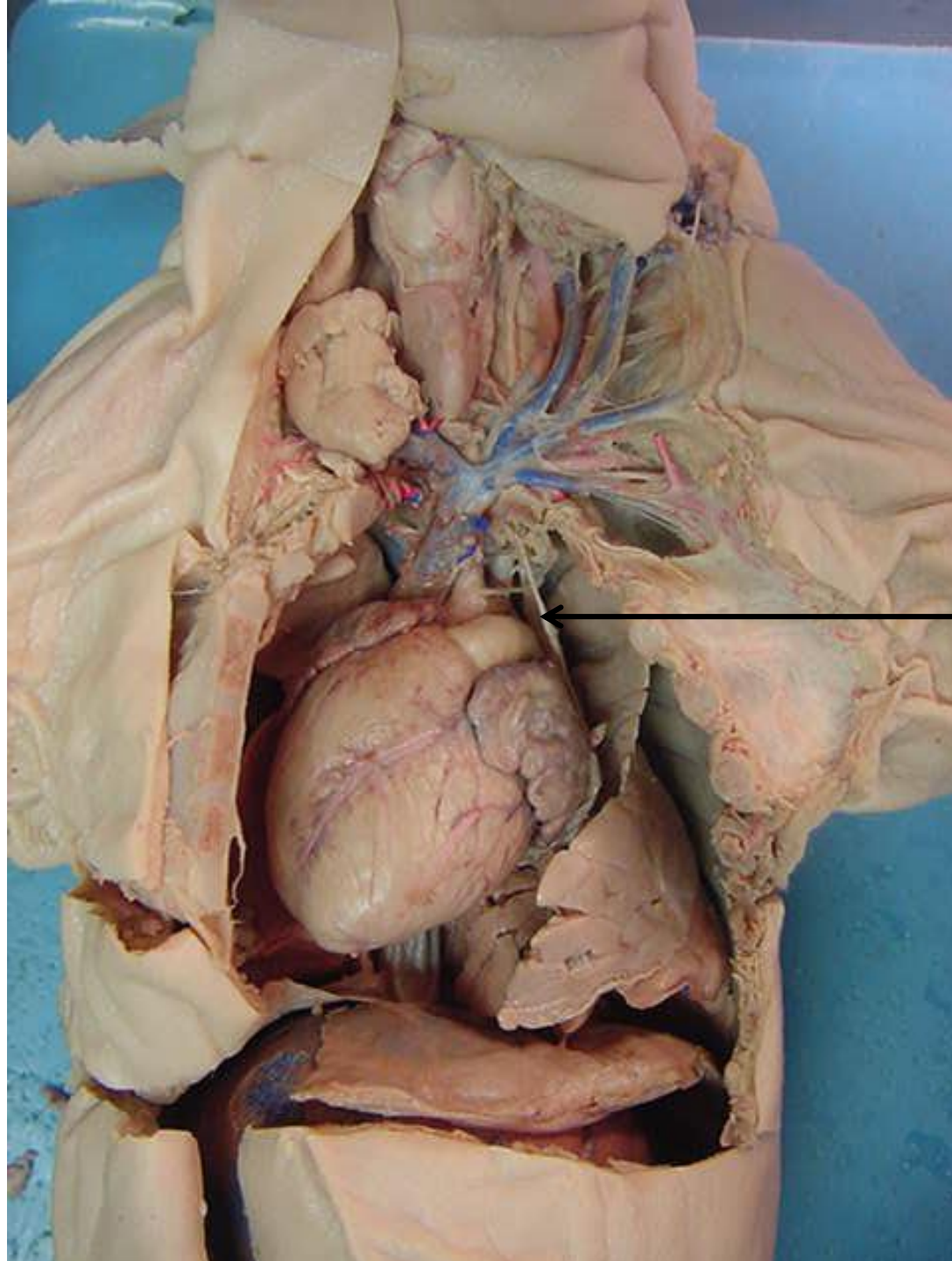
*scroll to the
next slide to
check your
answer



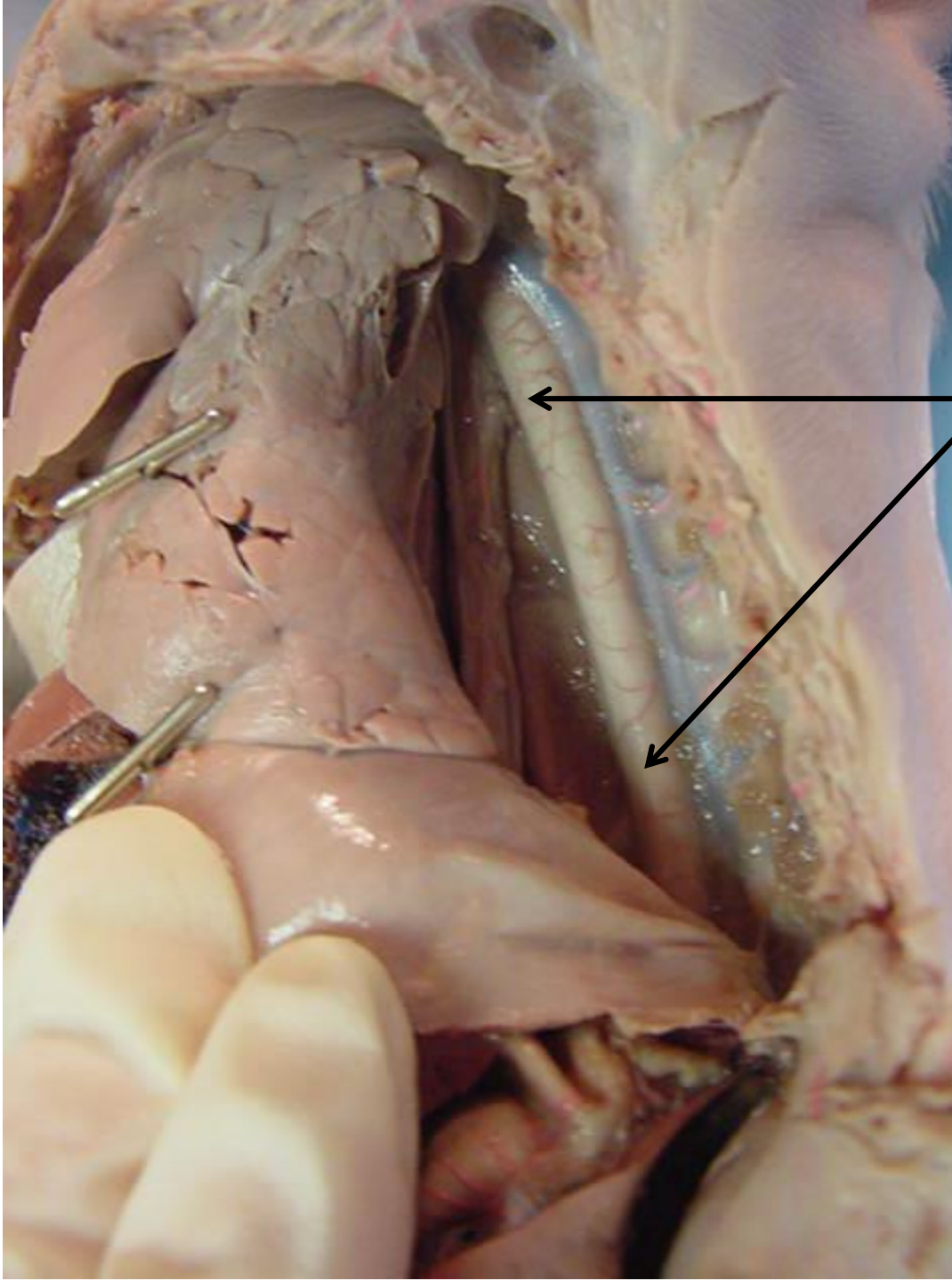
← auricle of left atrium



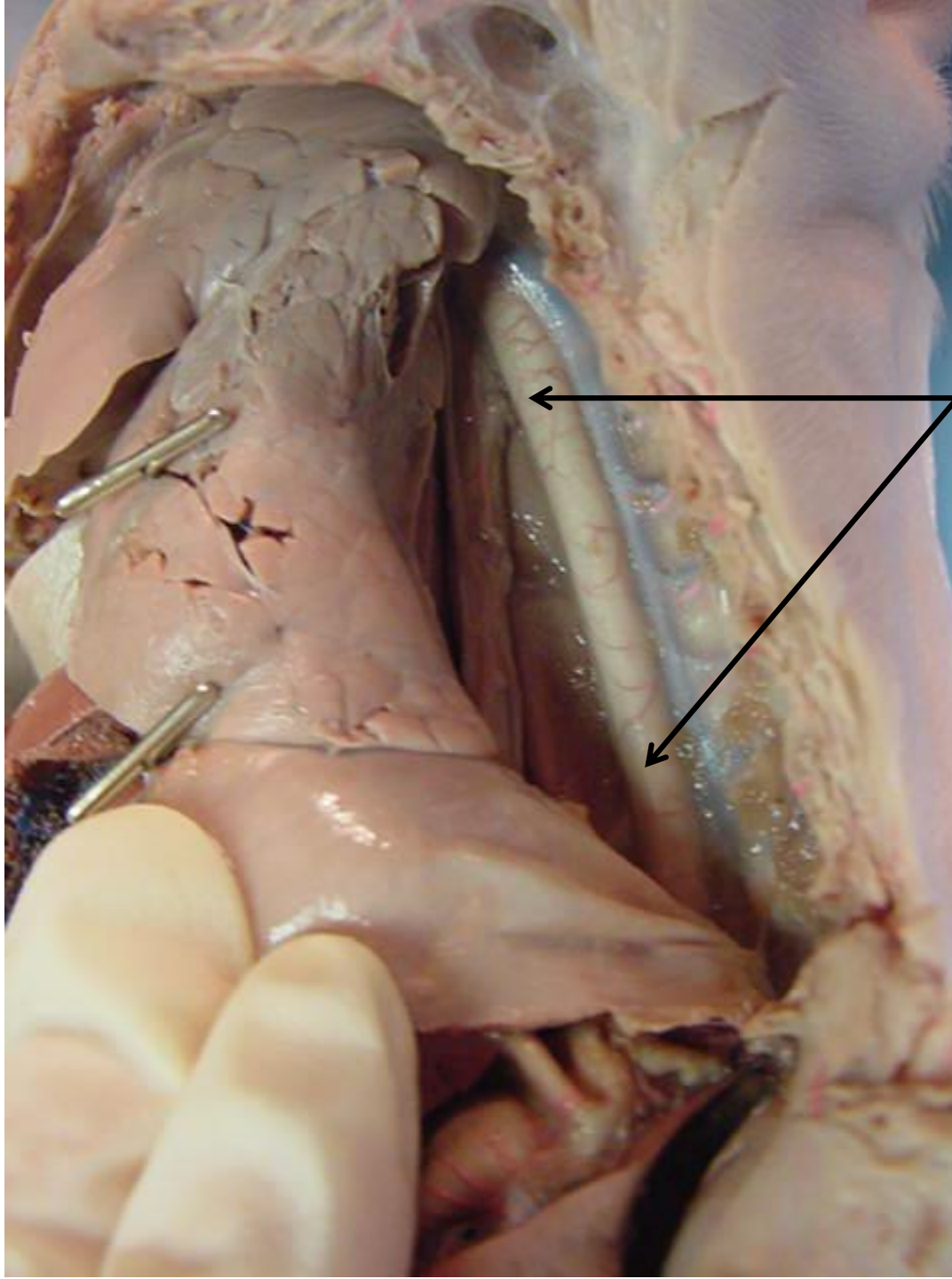
*scroll to the next slide to check your answer



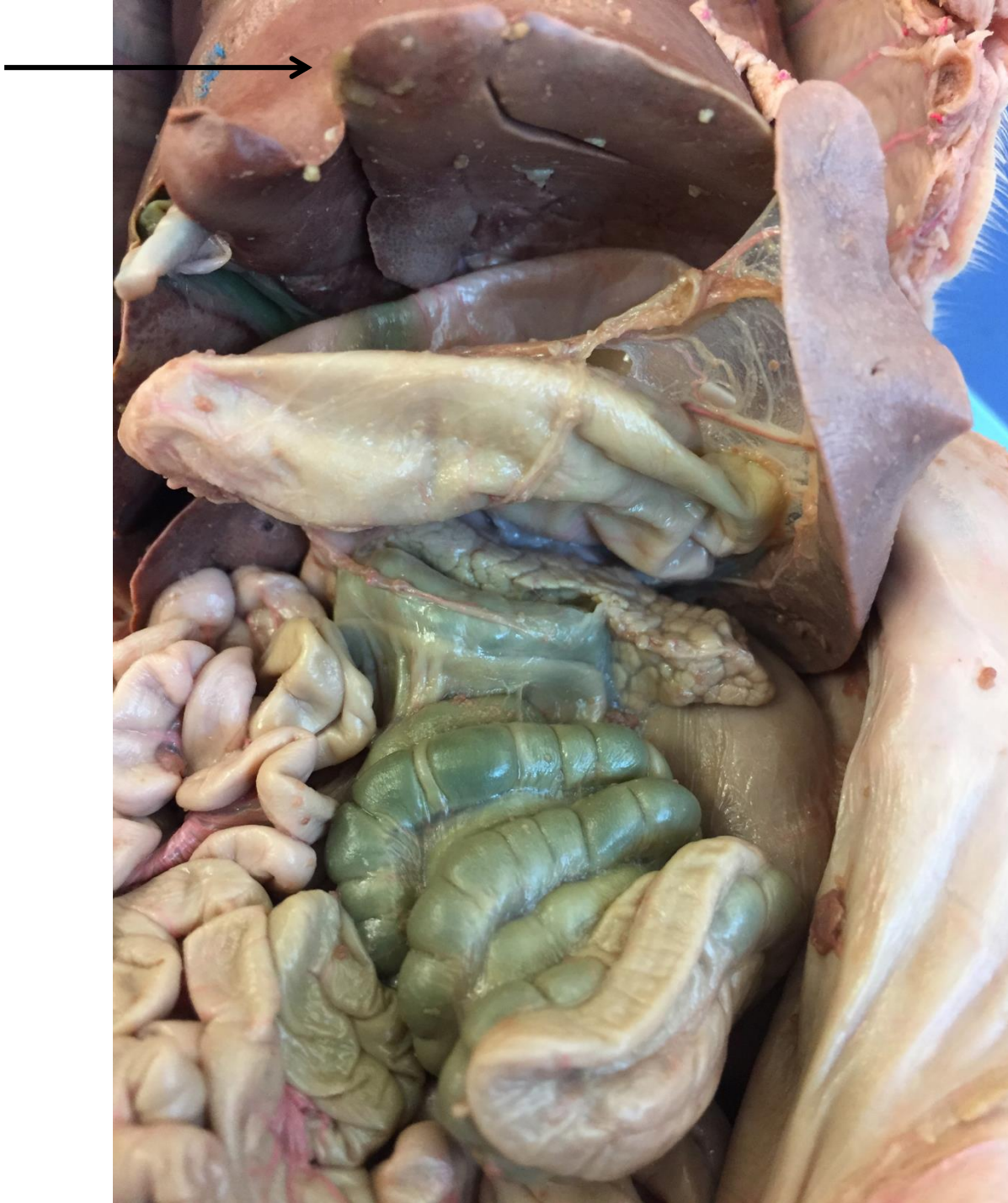Phrenic nerve



*scroll to the next slide to check your answer

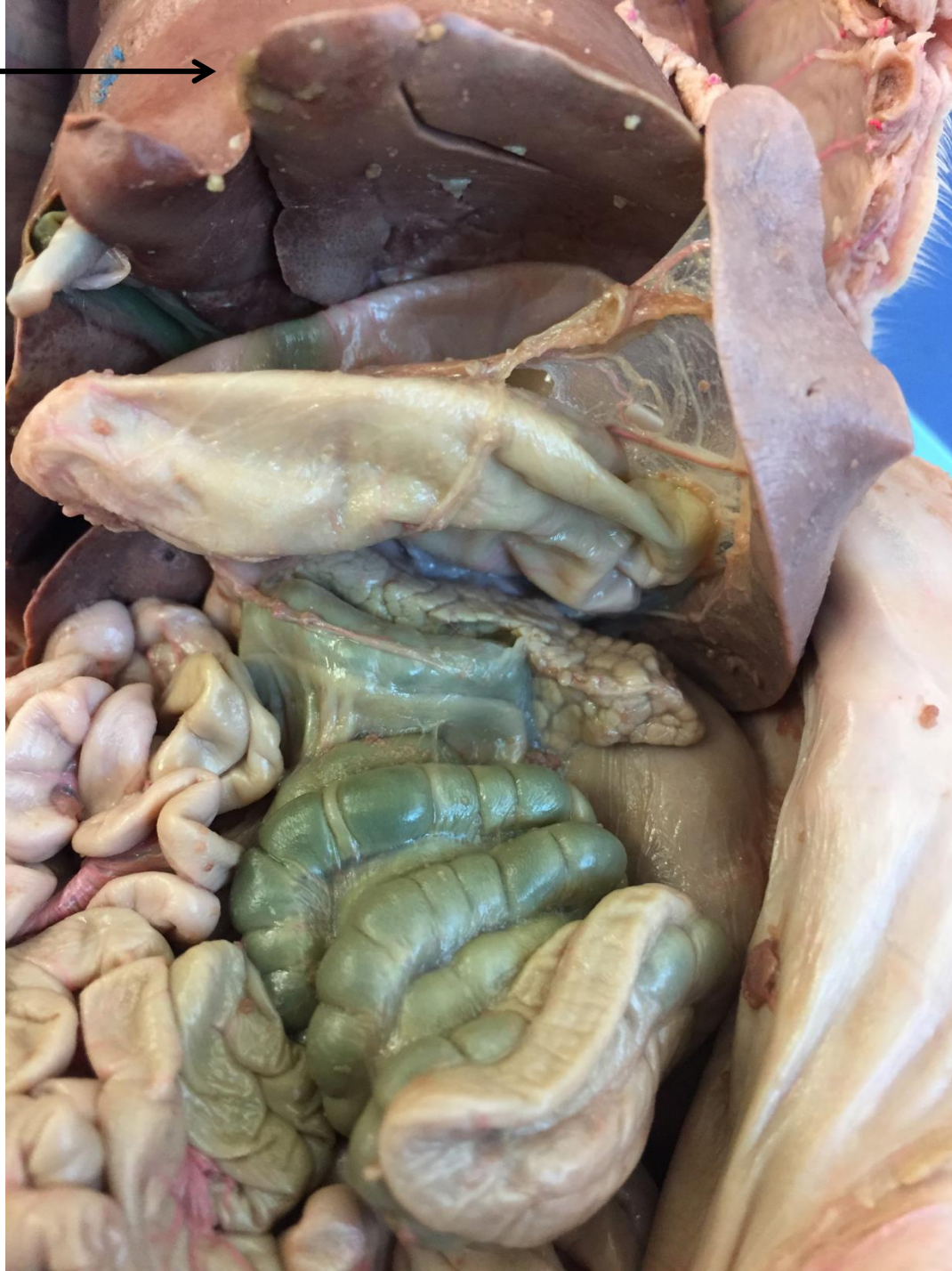

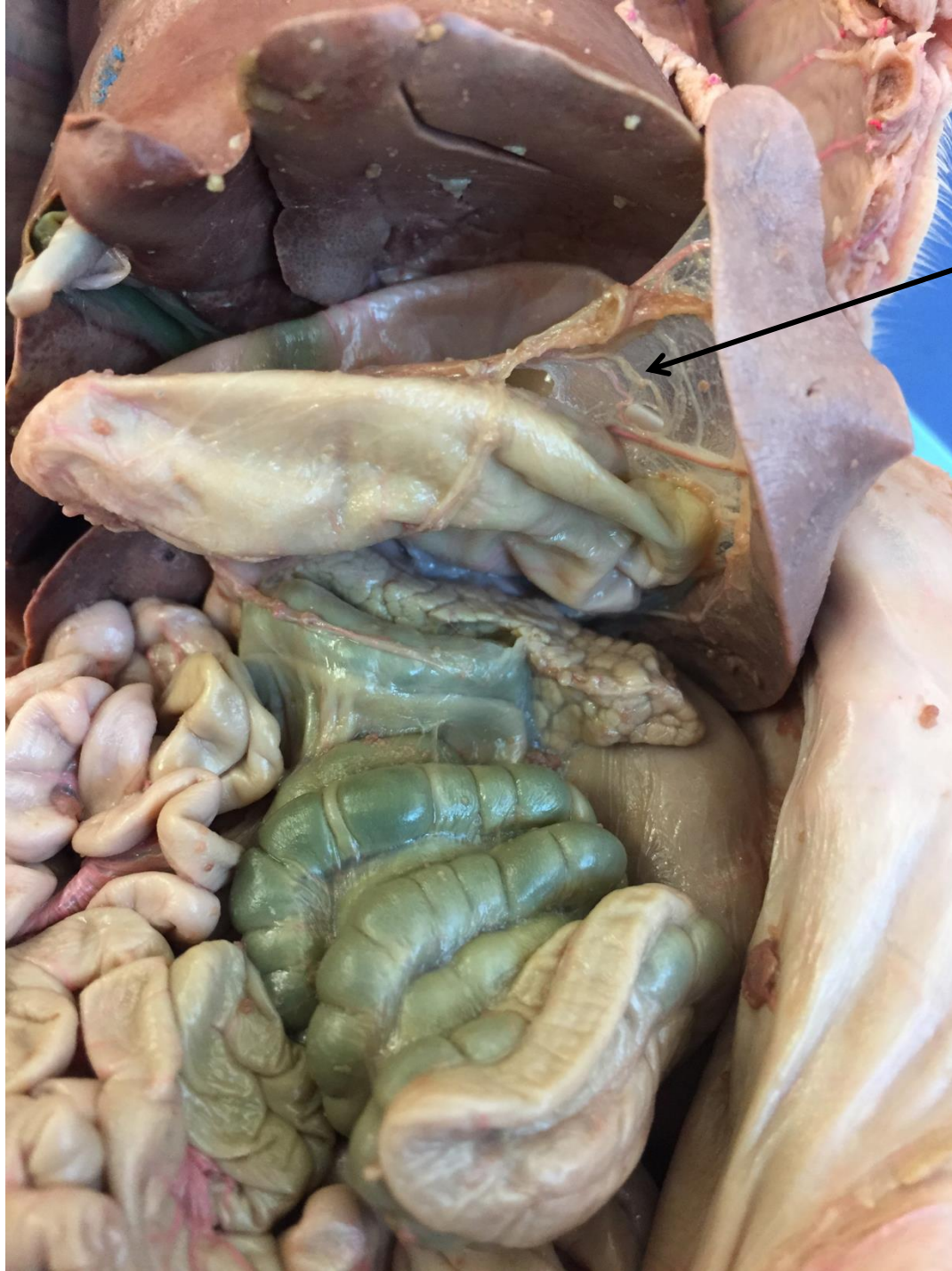descending aorta



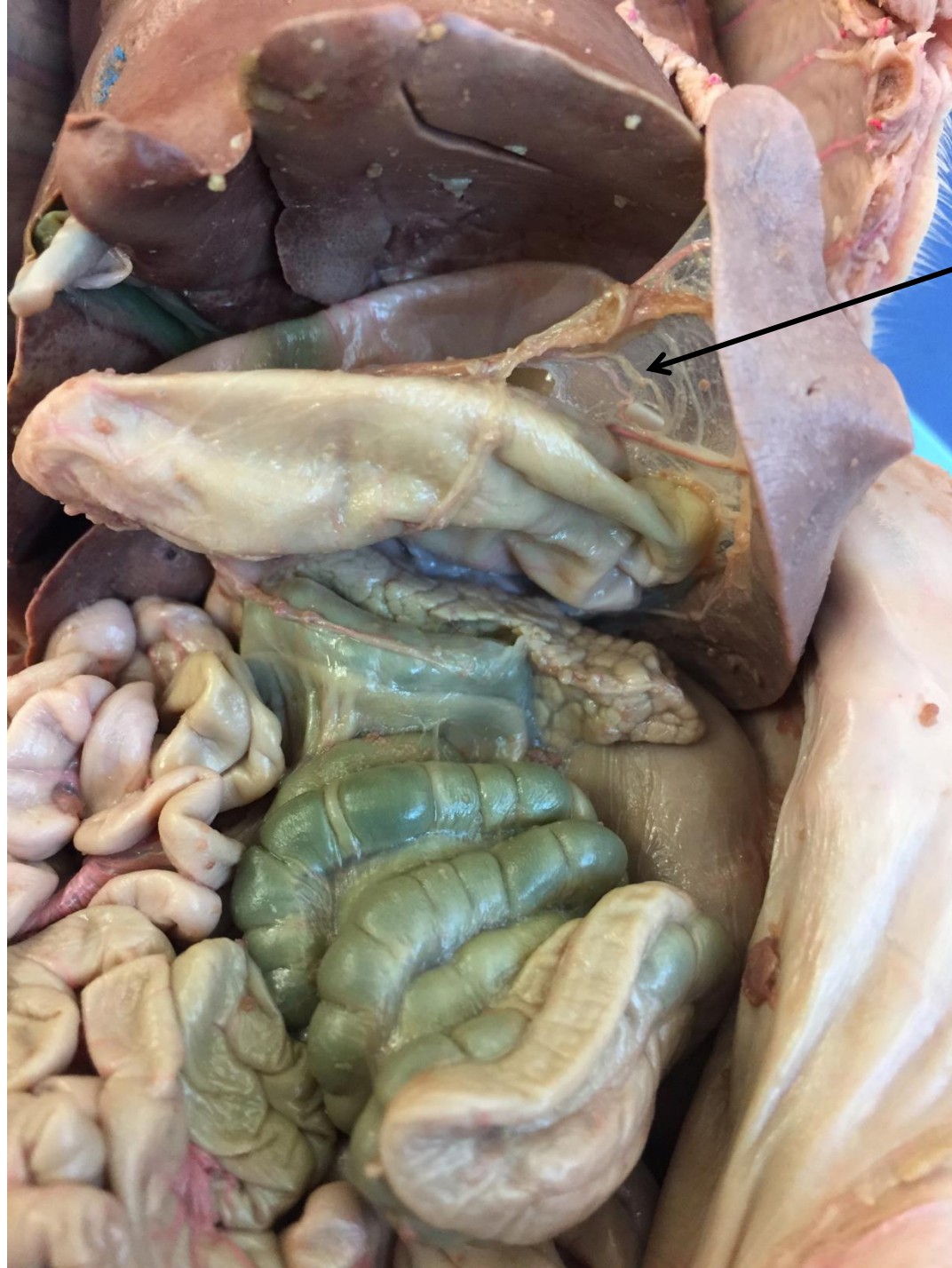*scroll to the next slide to check your answer

liver

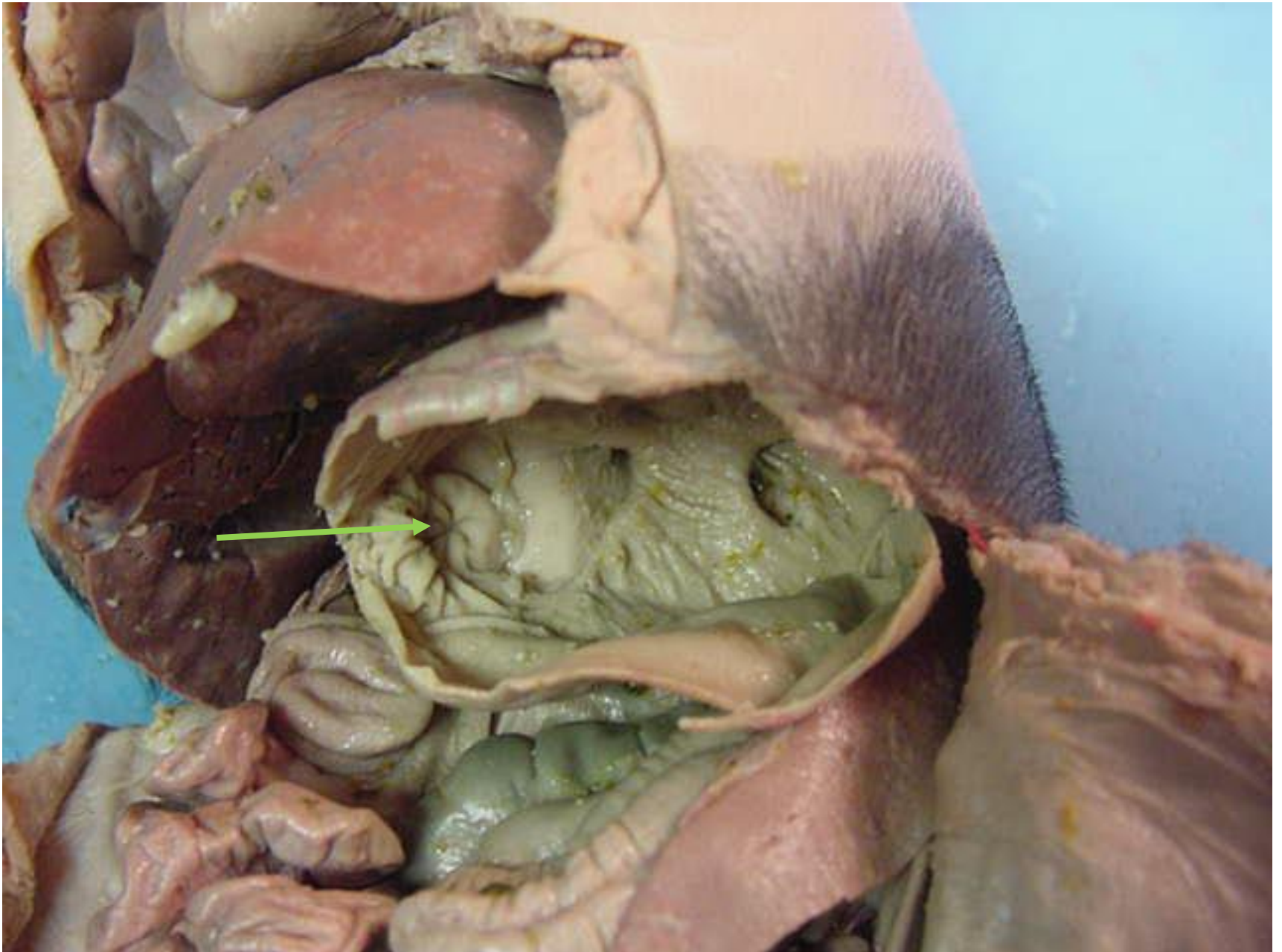



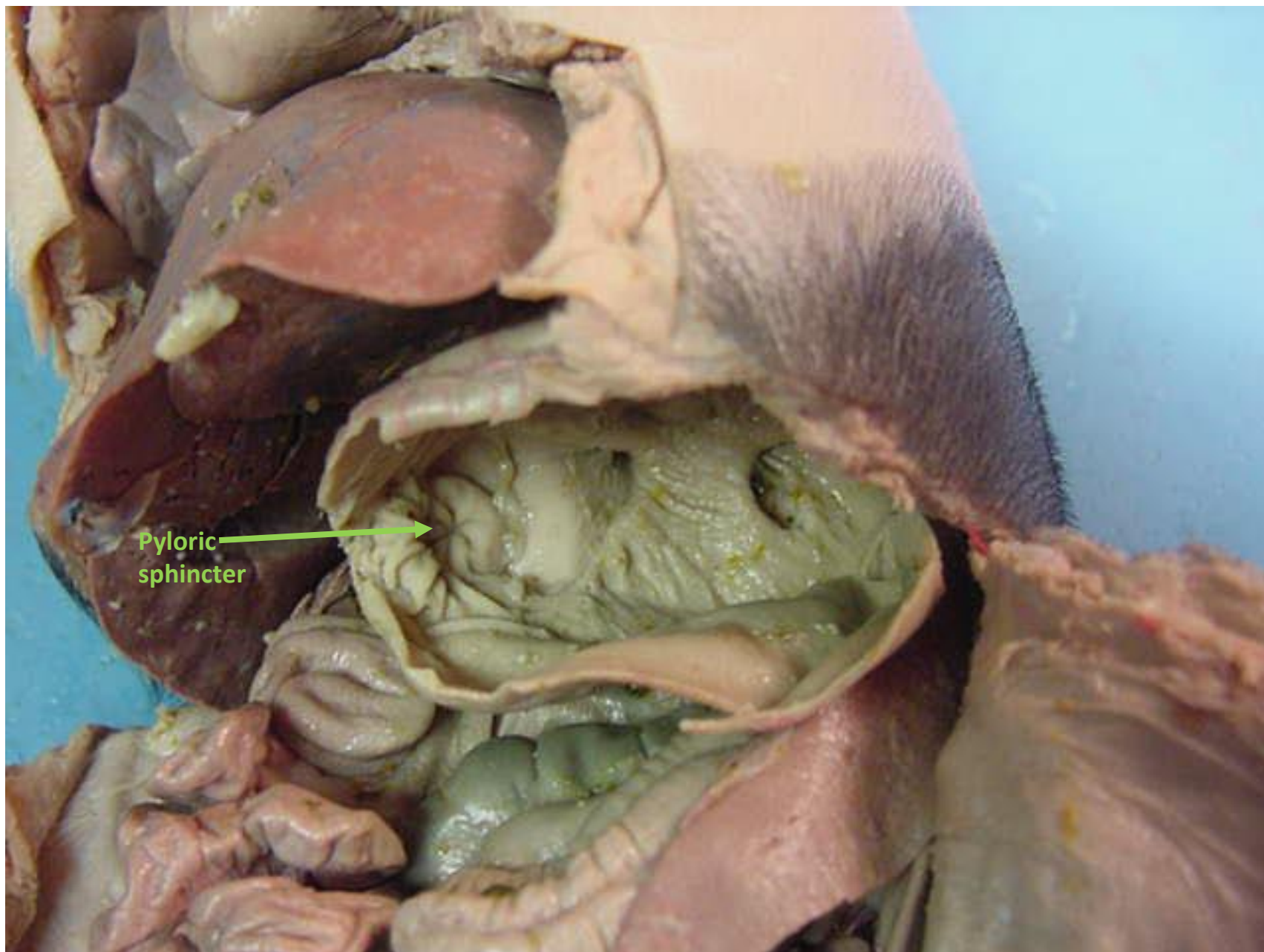
*scroll to the next slide to check your answer



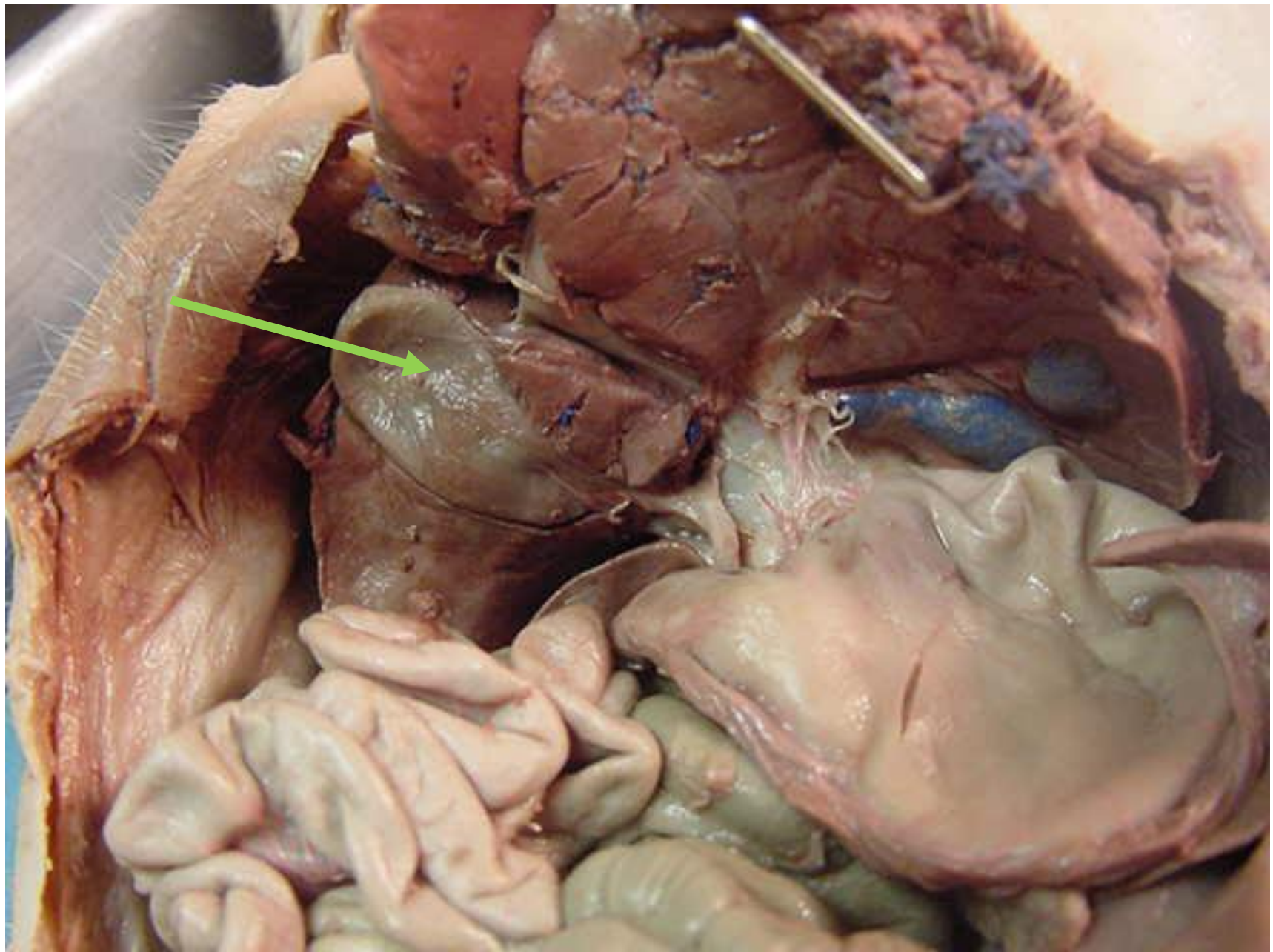
greater omentum



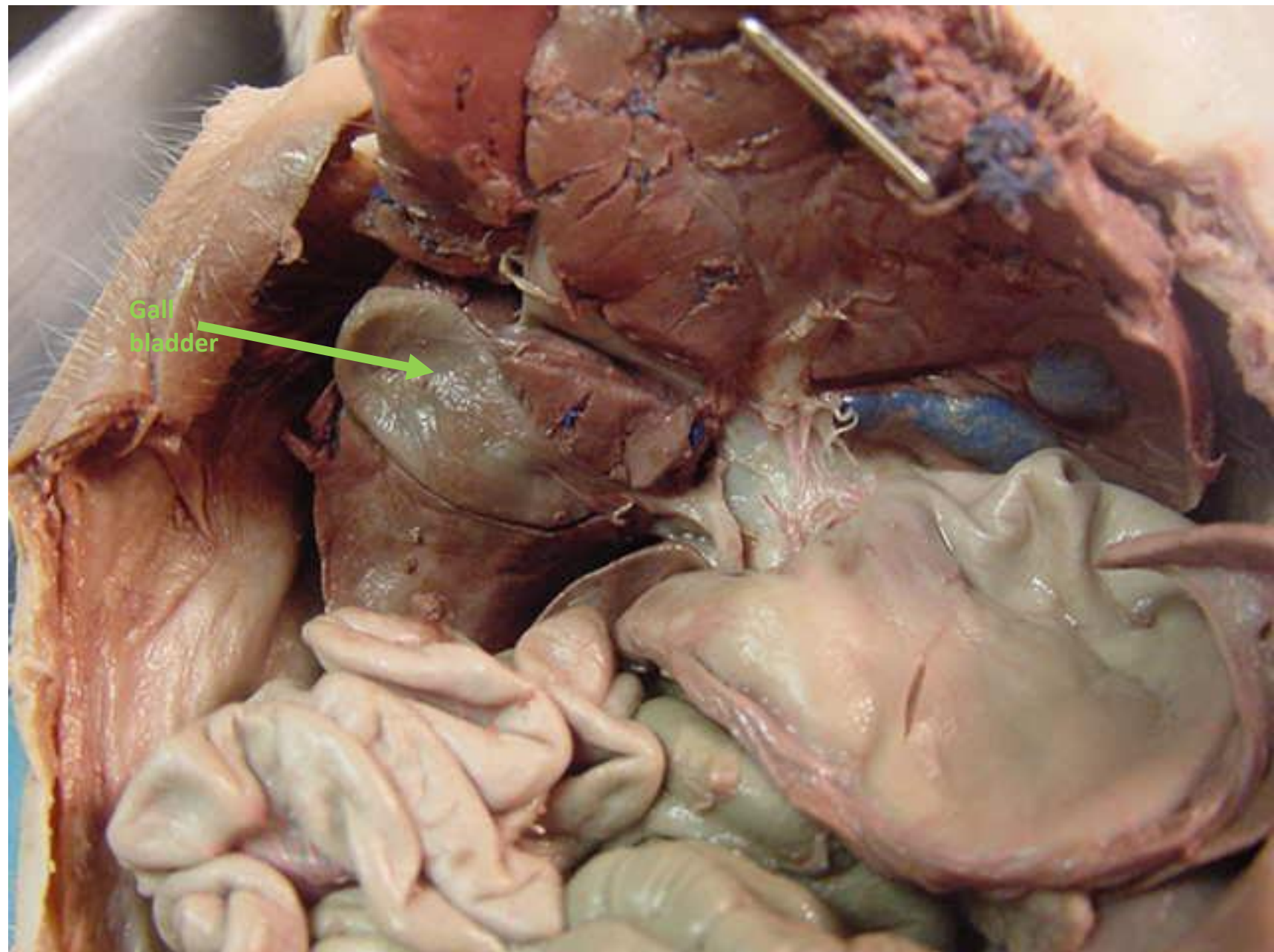
*scroll to the next slide to check your answer

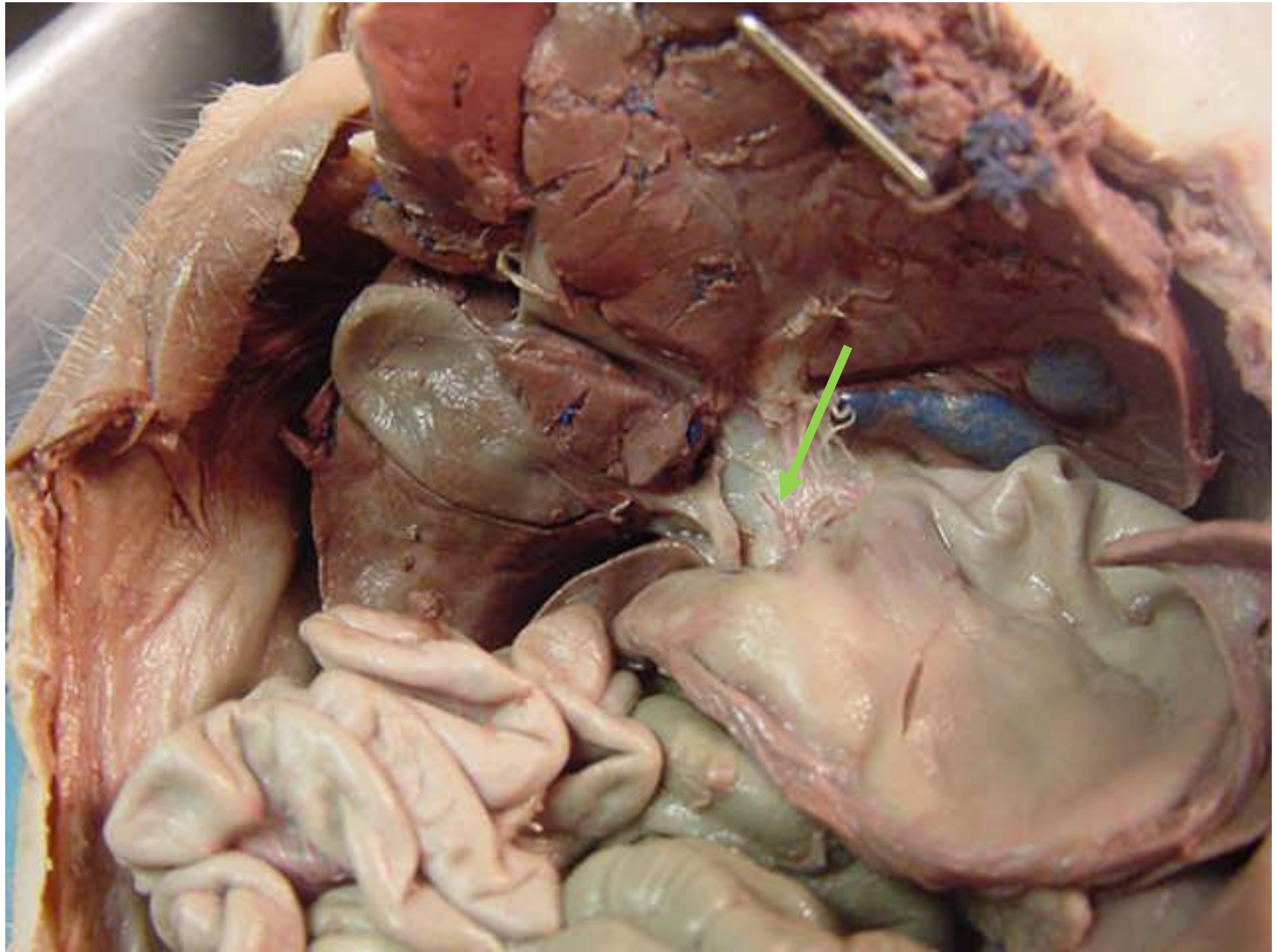


Pyloric
sphincter

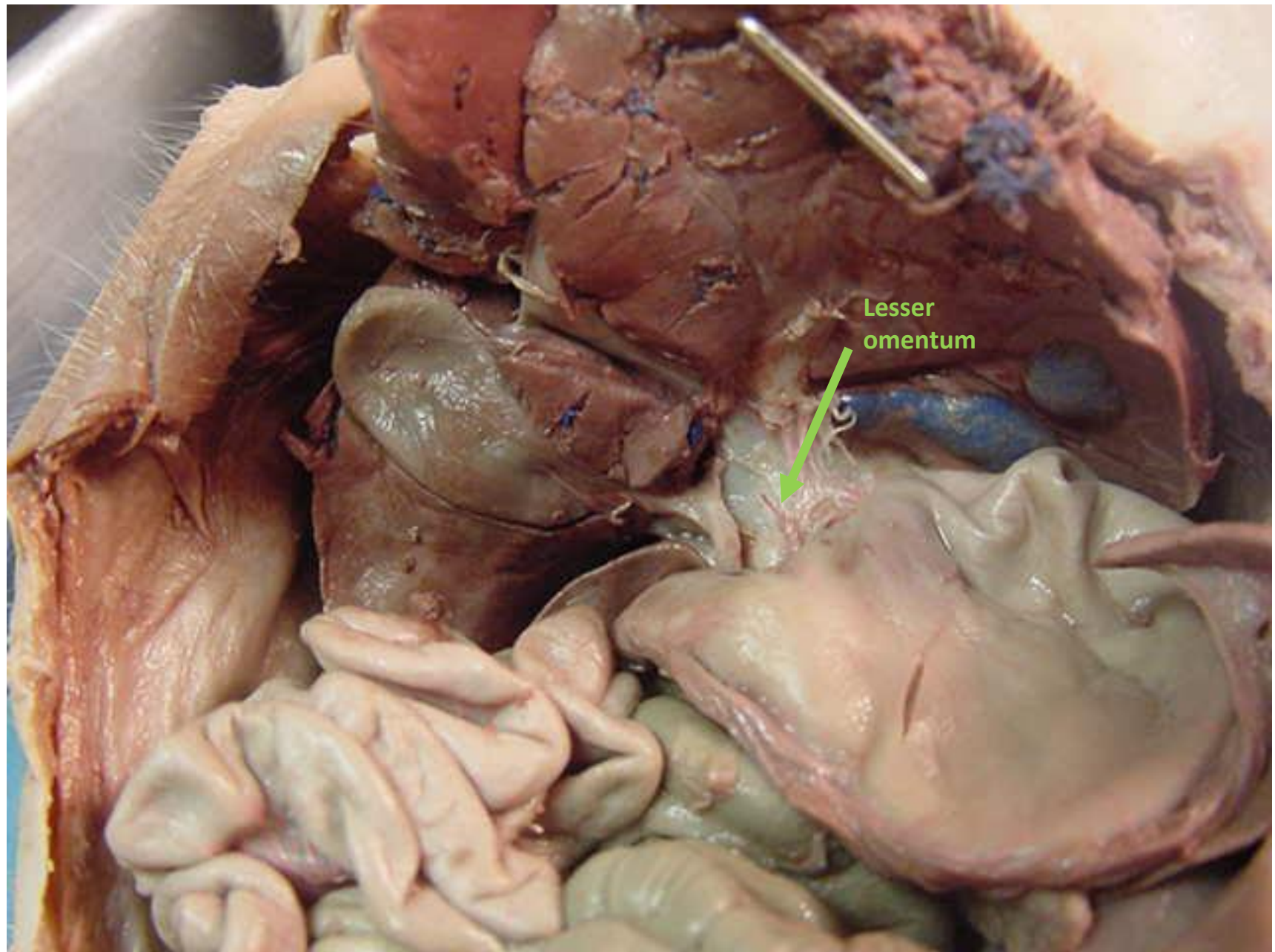


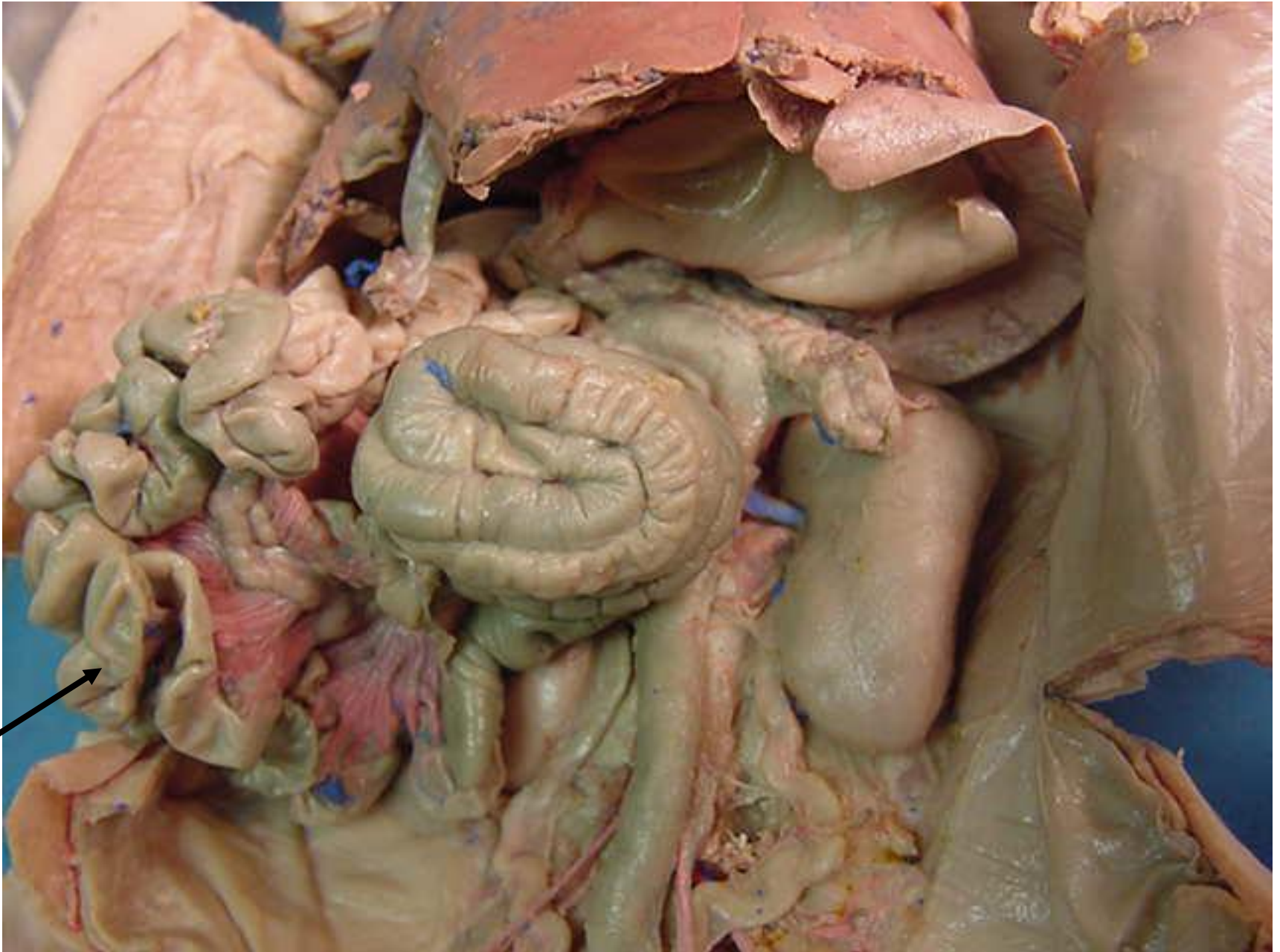*scroll to the next slide to check your answer



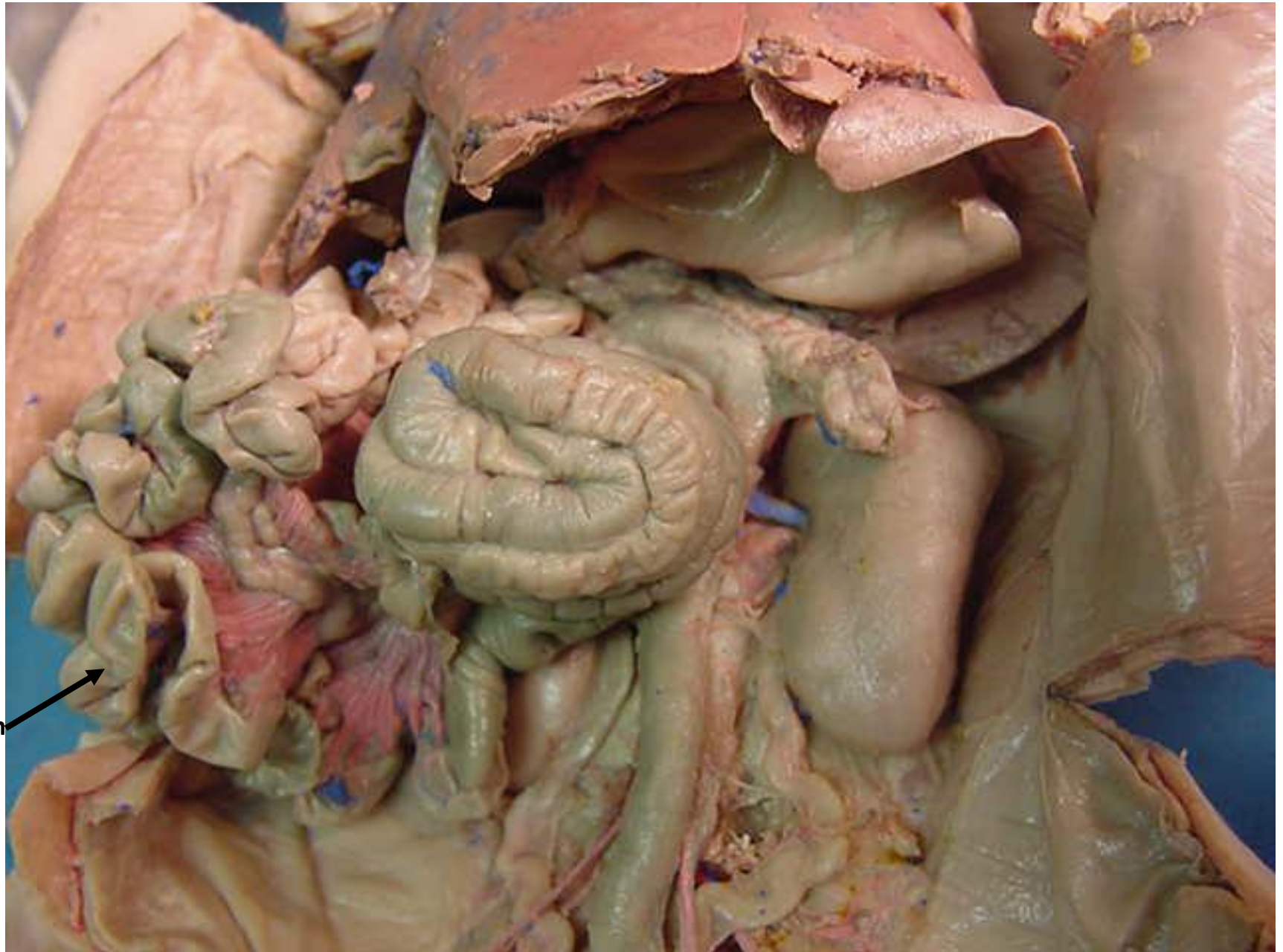

*scroll to the next slide to check your answer

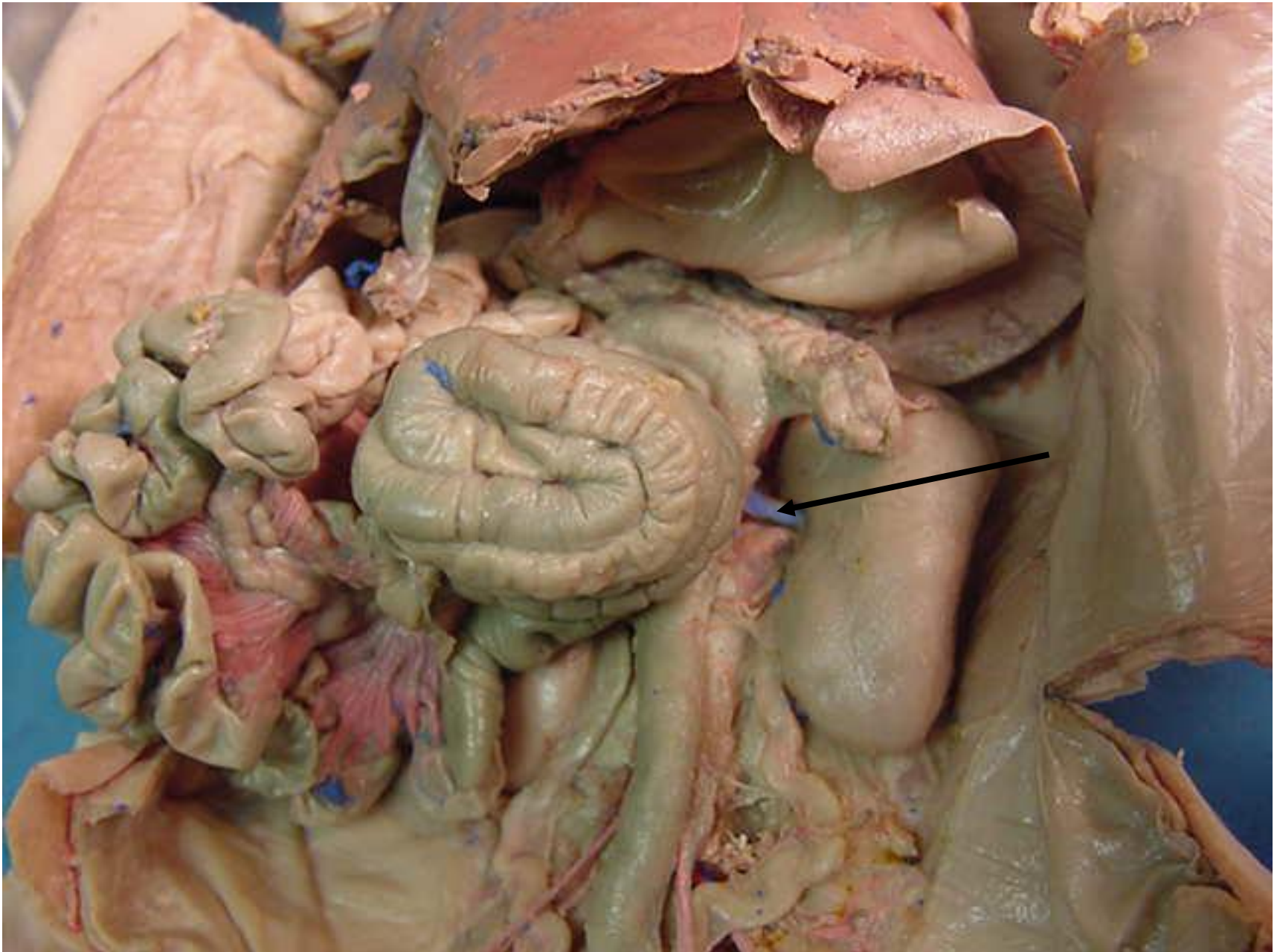




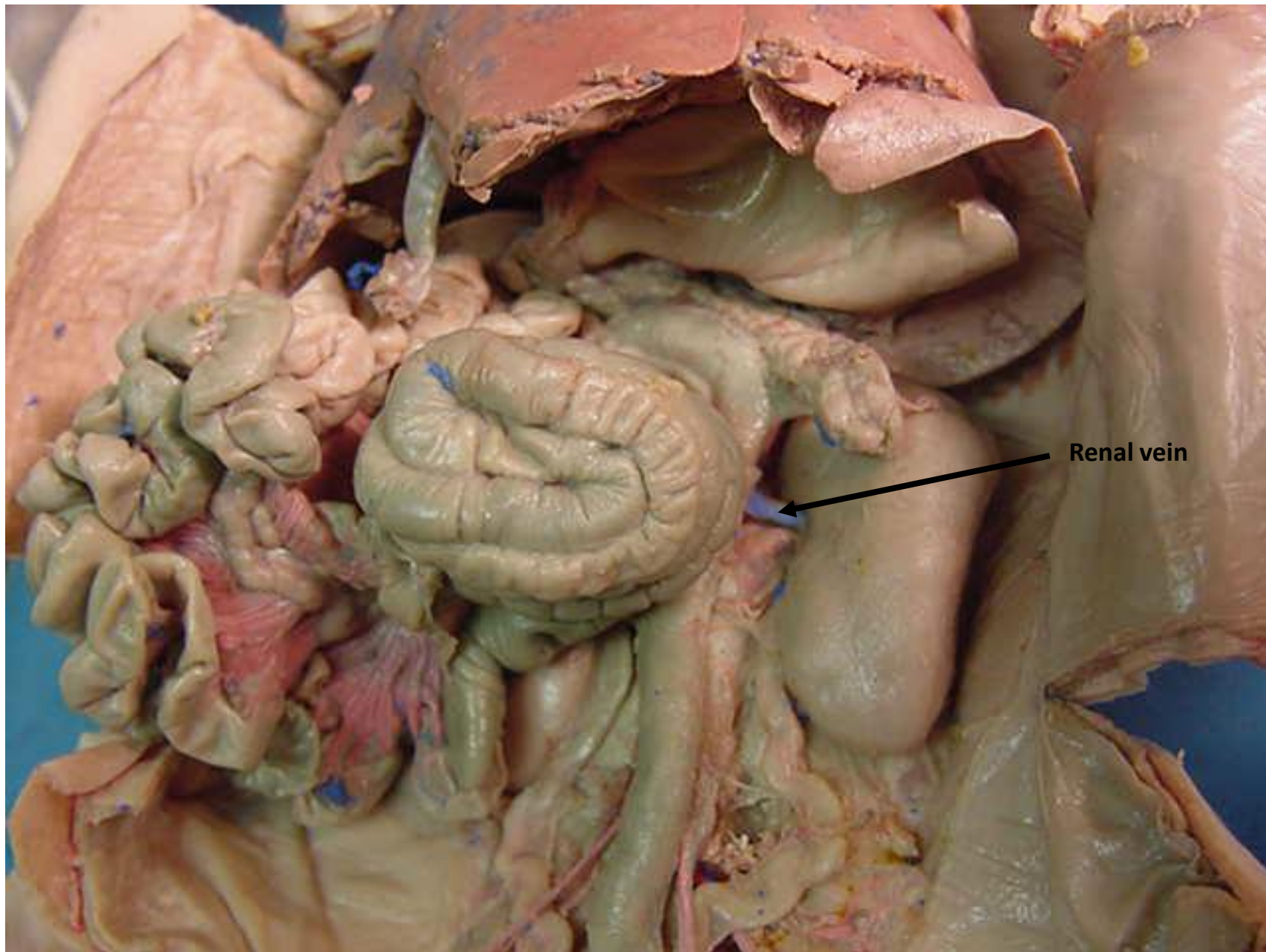
*scroll to the next slide to check your answer



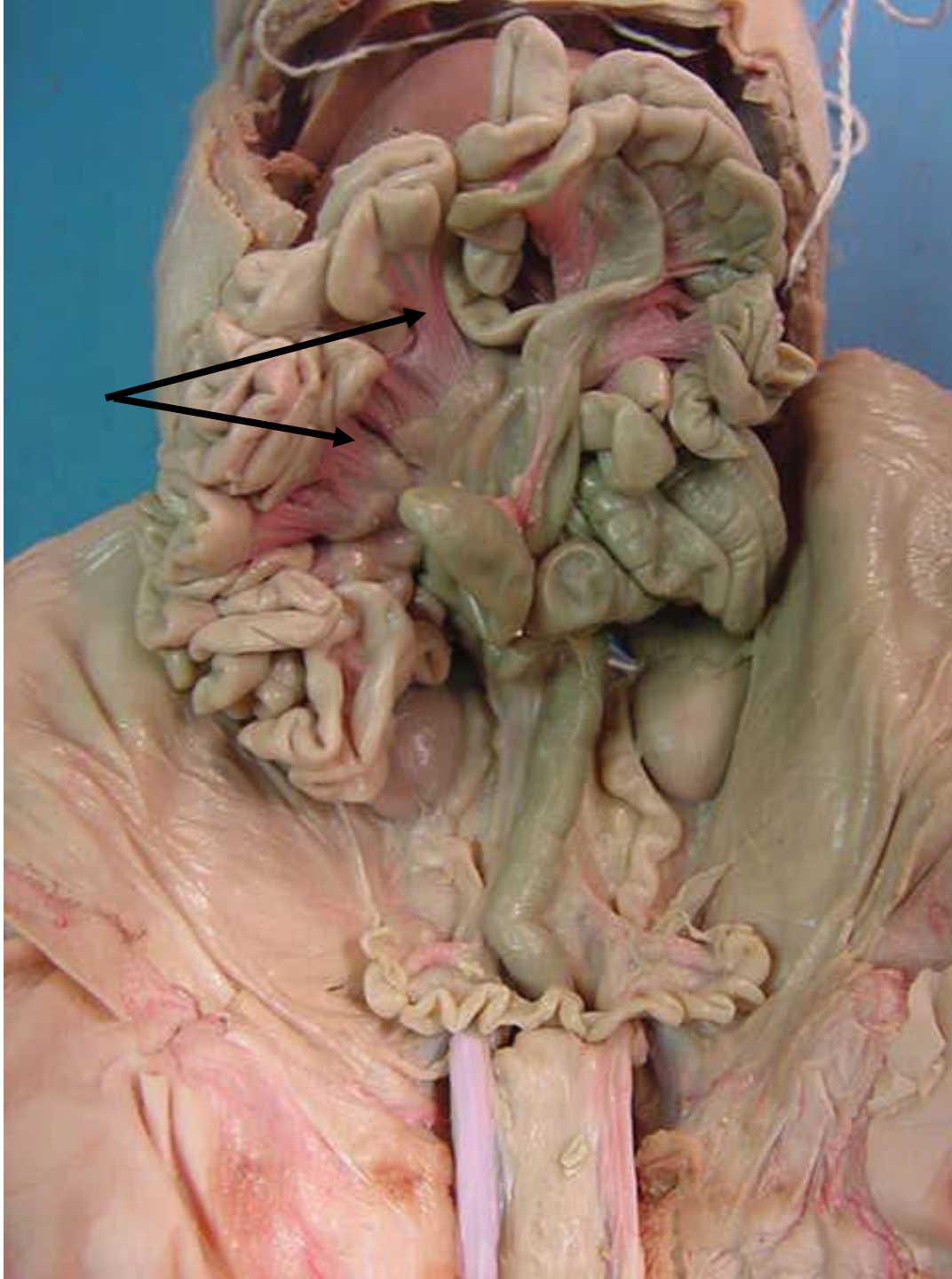
ileum



*scroll to the next slide to check your answer

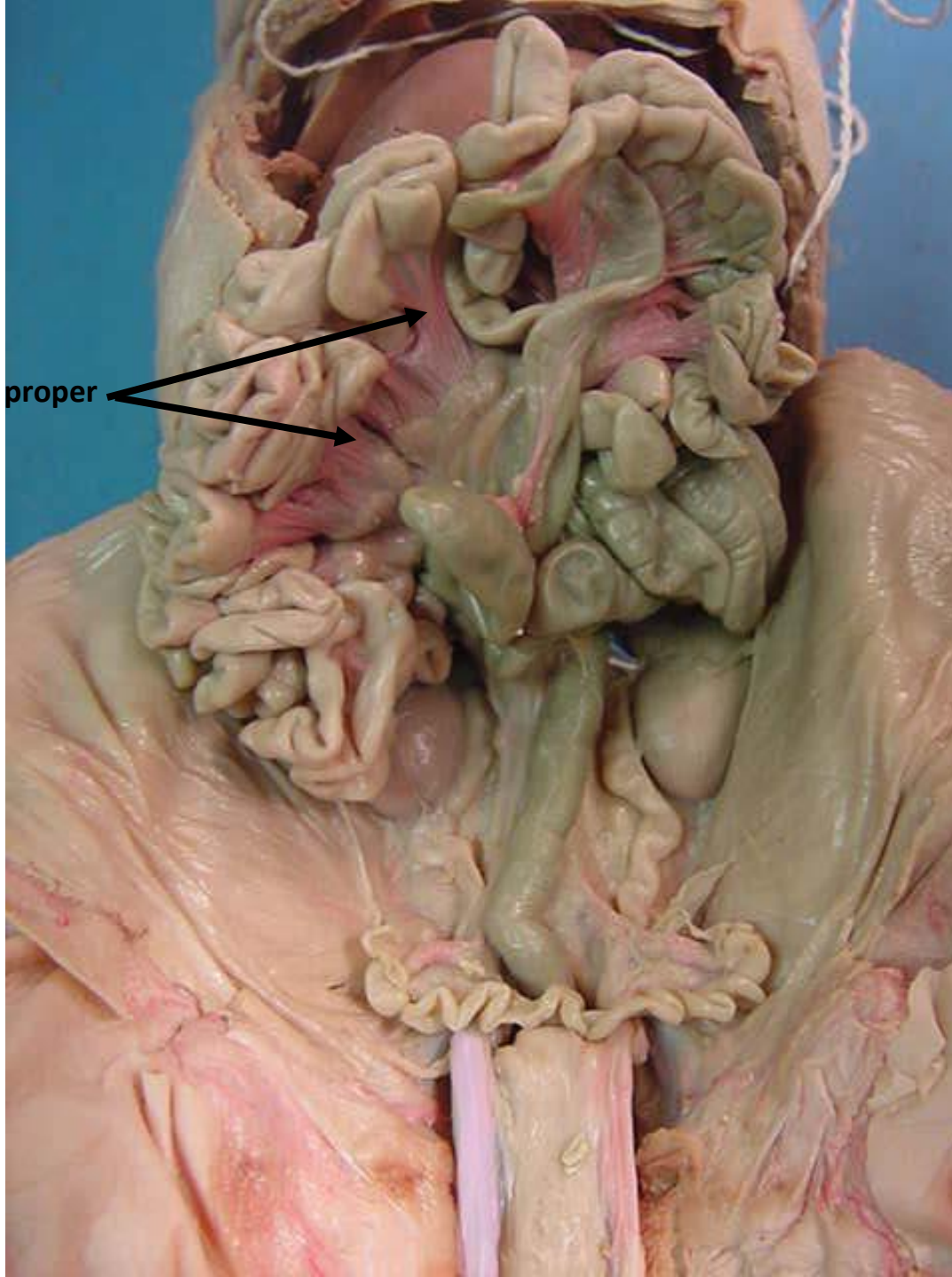


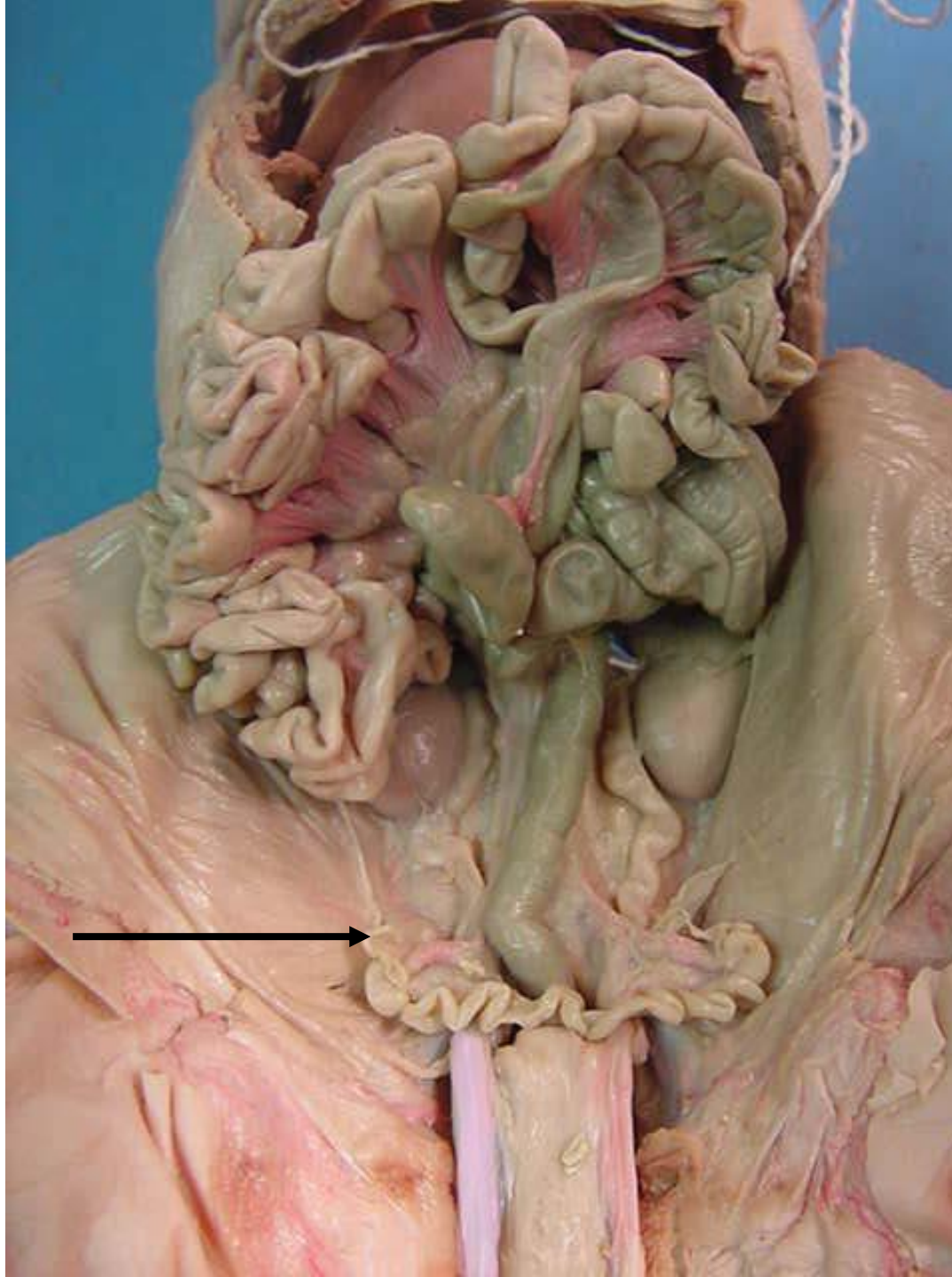
Renal vein



*scroll to the next slide to check your answer

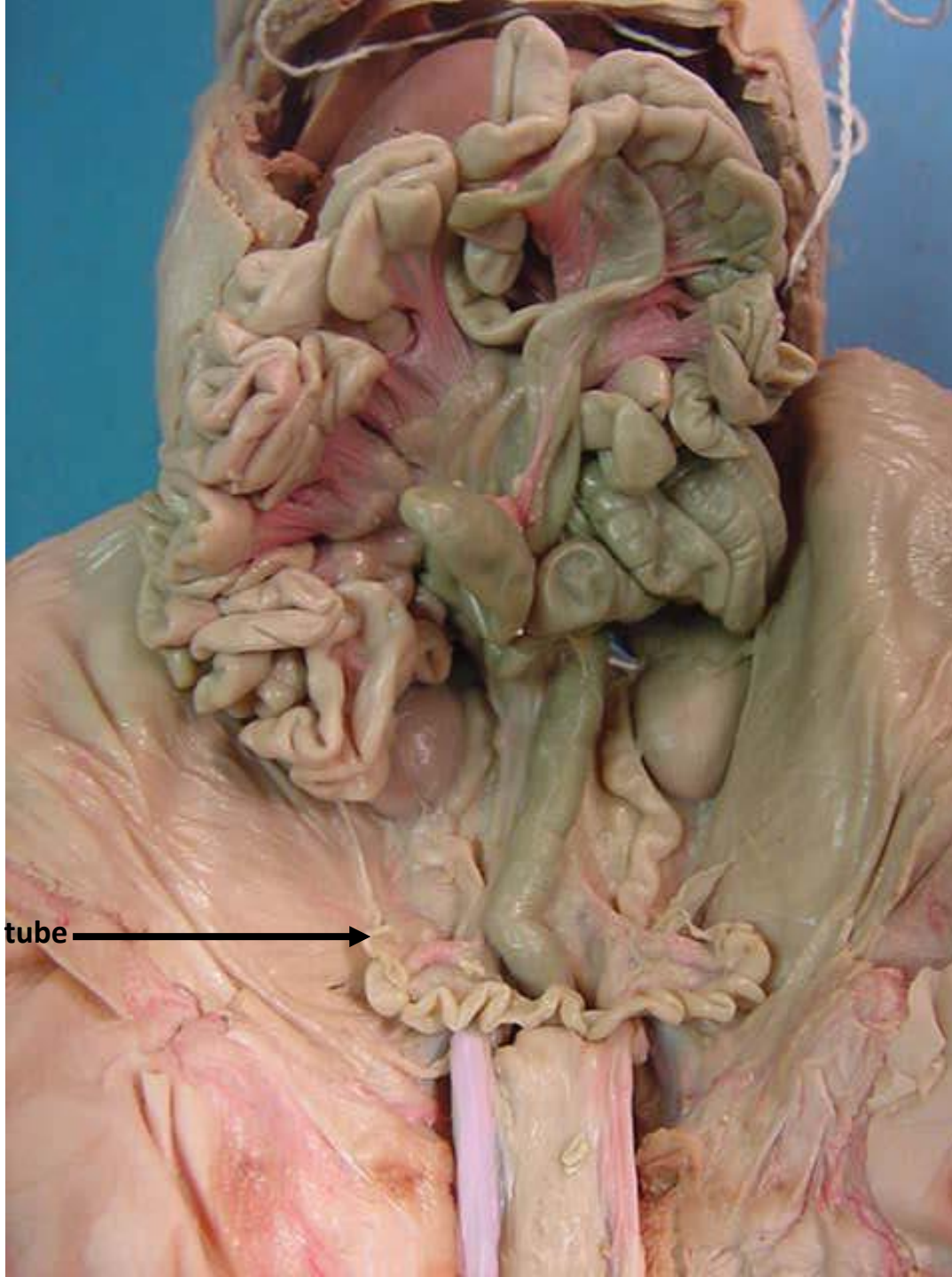
Mesentery proper

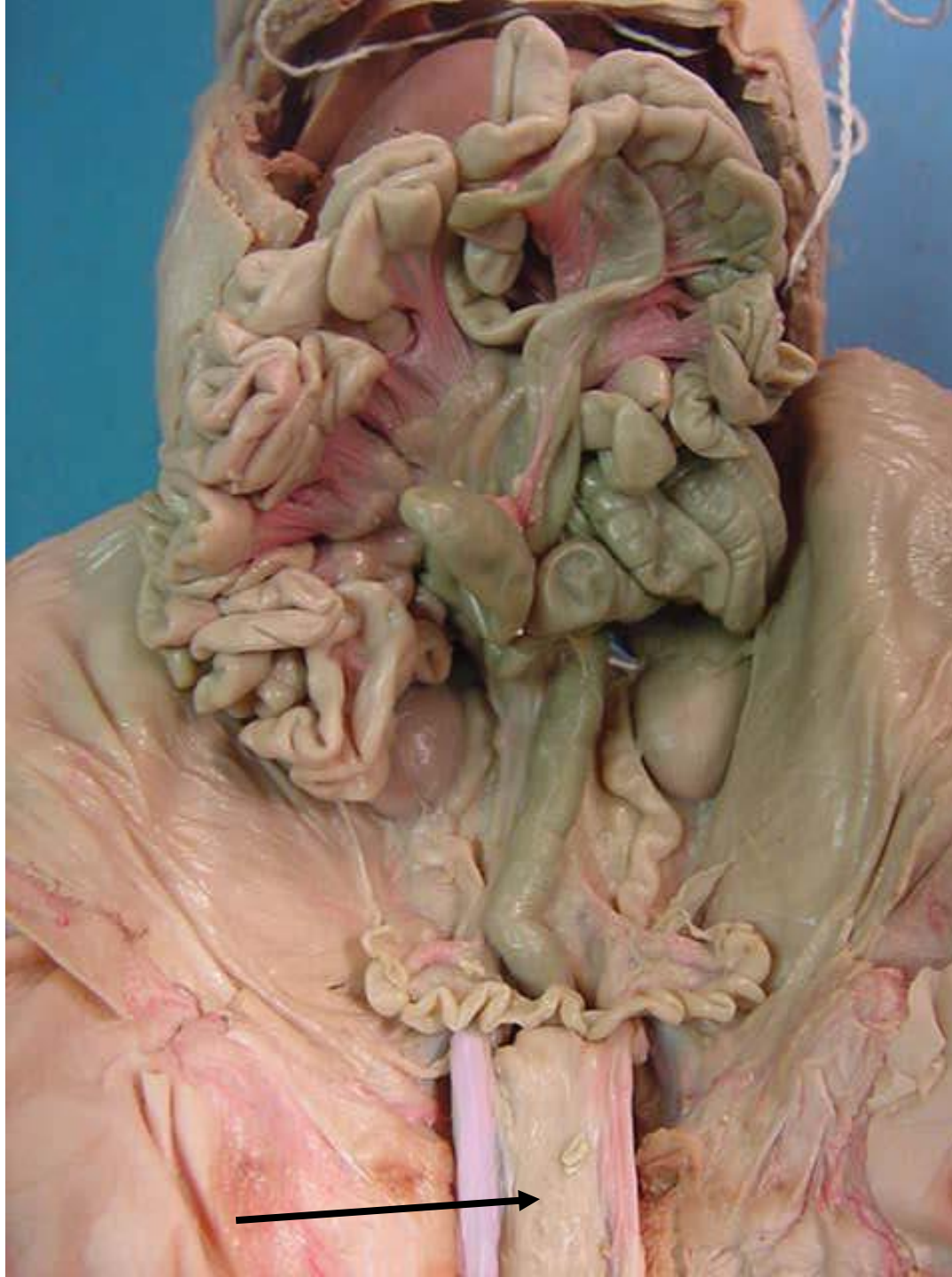



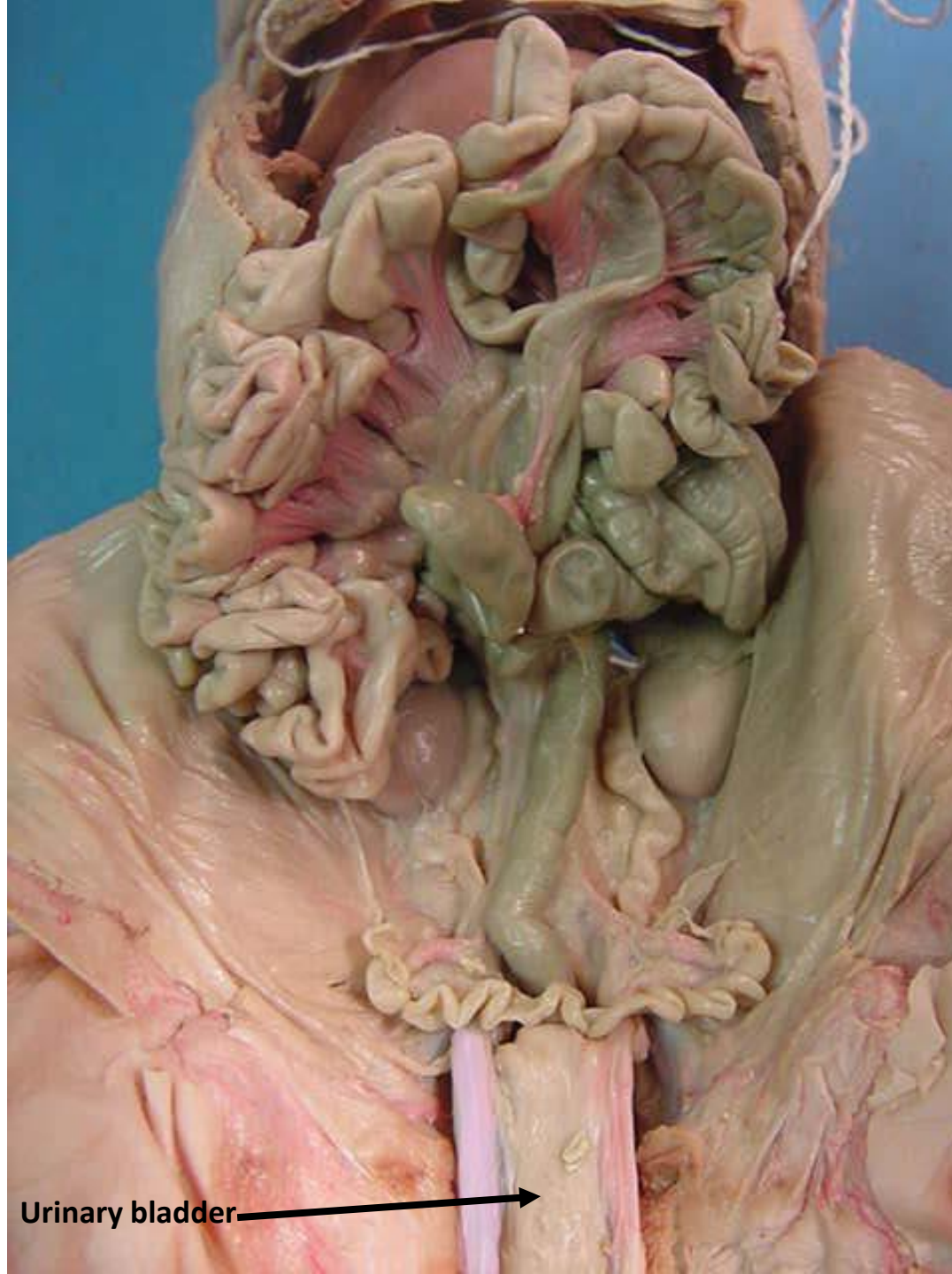*scroll to the next slide to check your answer

Fallopian tube →

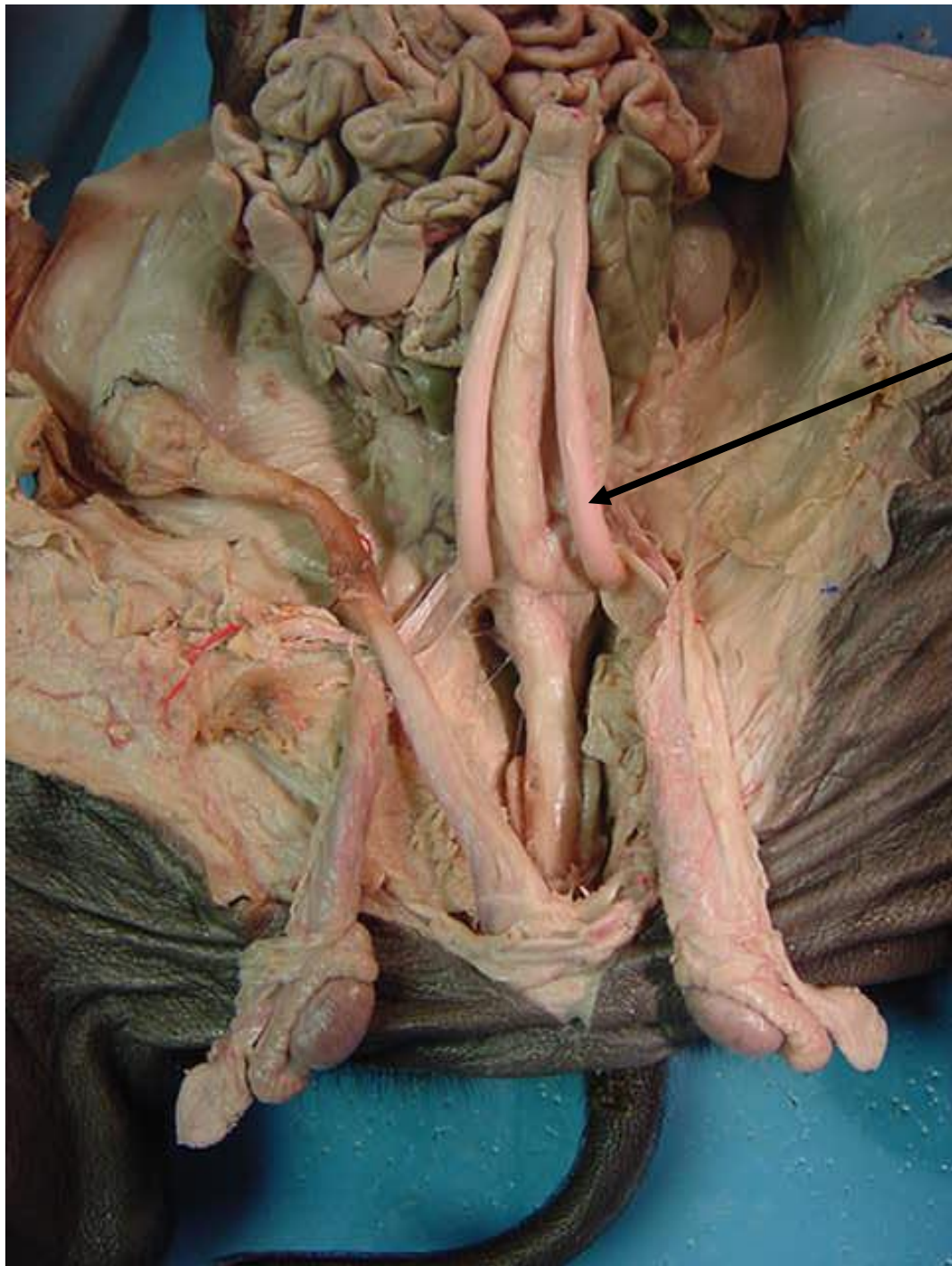




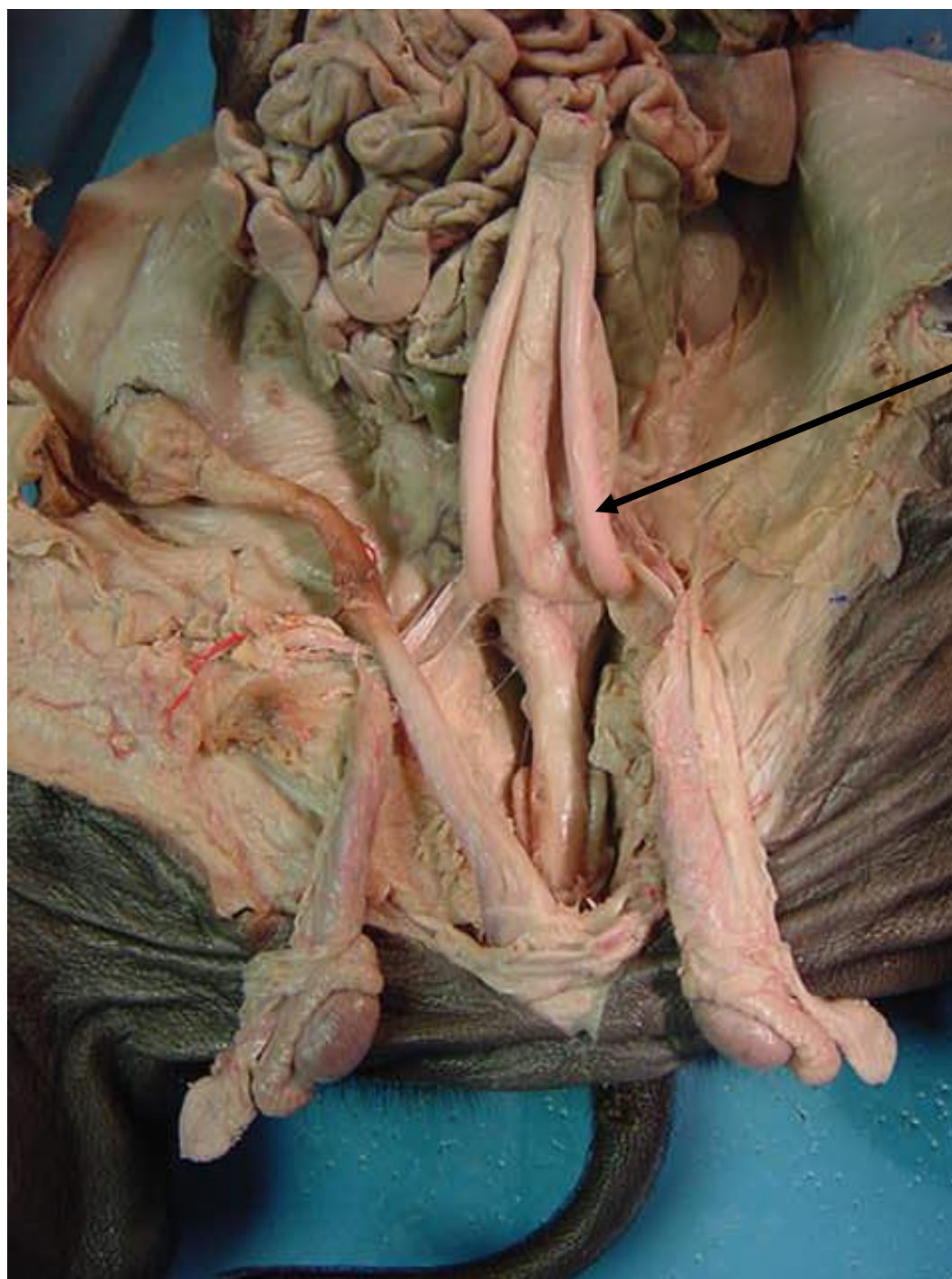
*scroll to the
next slide to
check your
answer



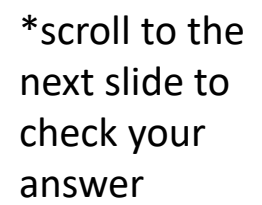
Urinary bladder

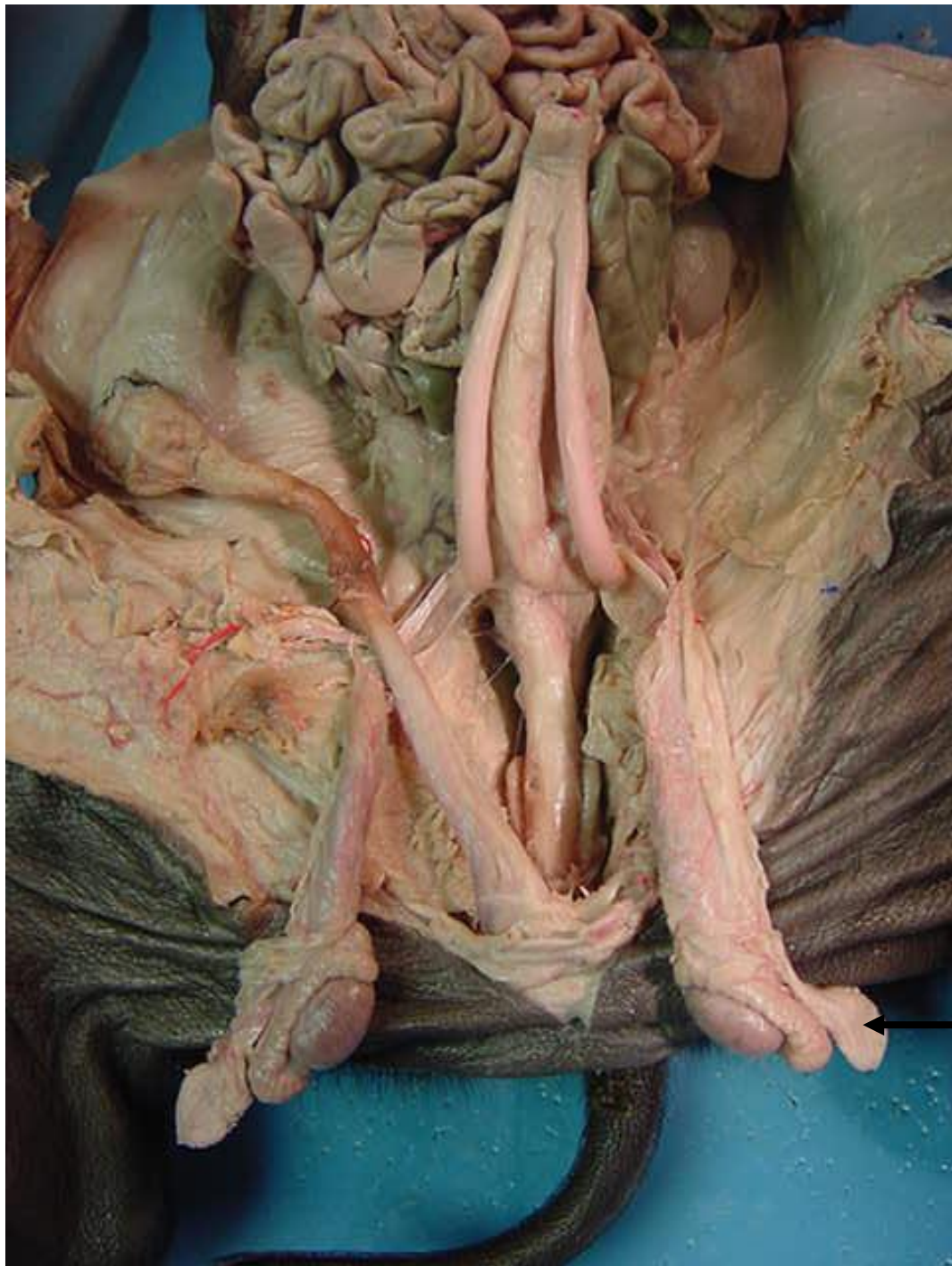

*scroll to the next slide to check your answer

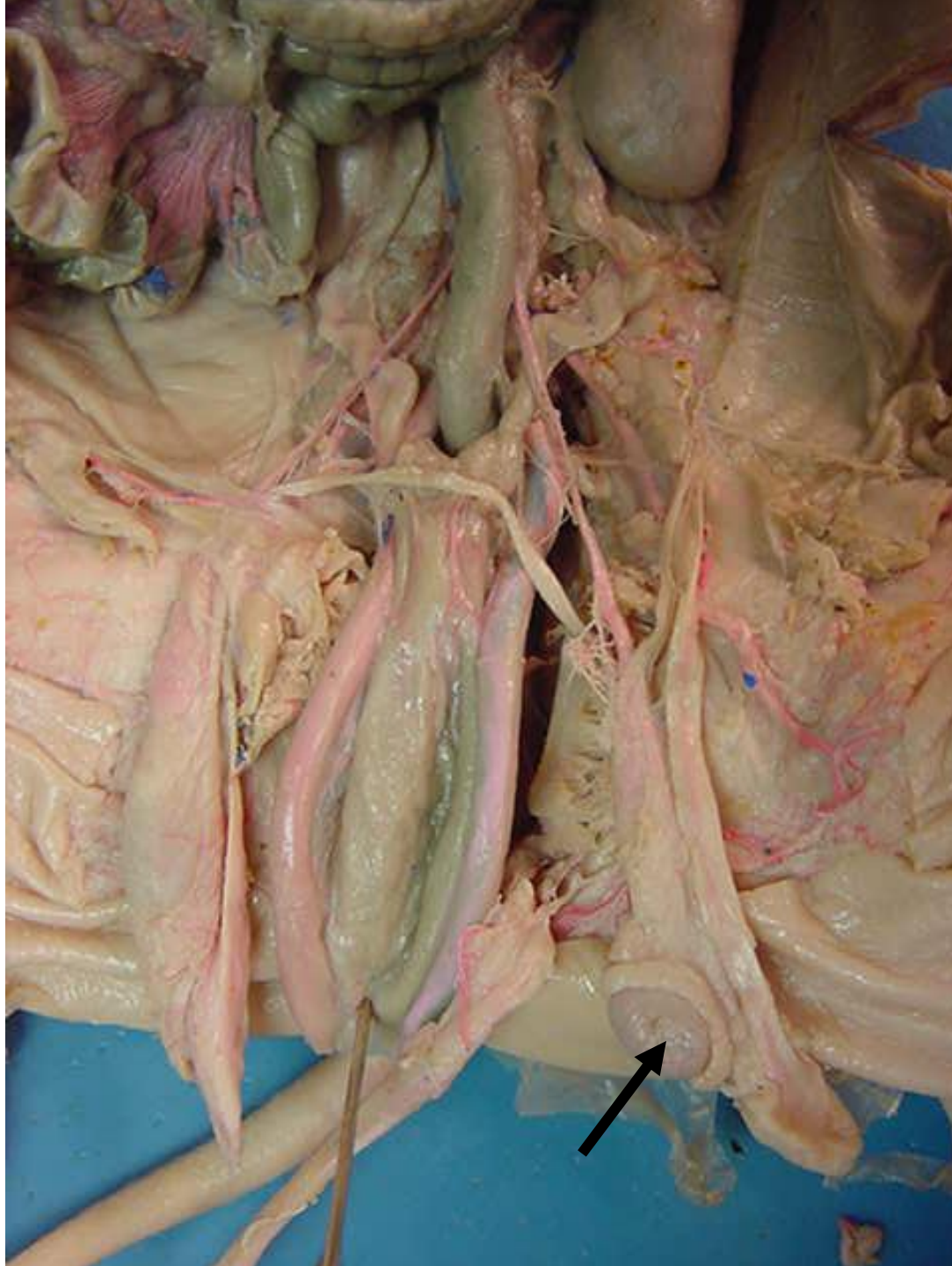


Umbilical artery

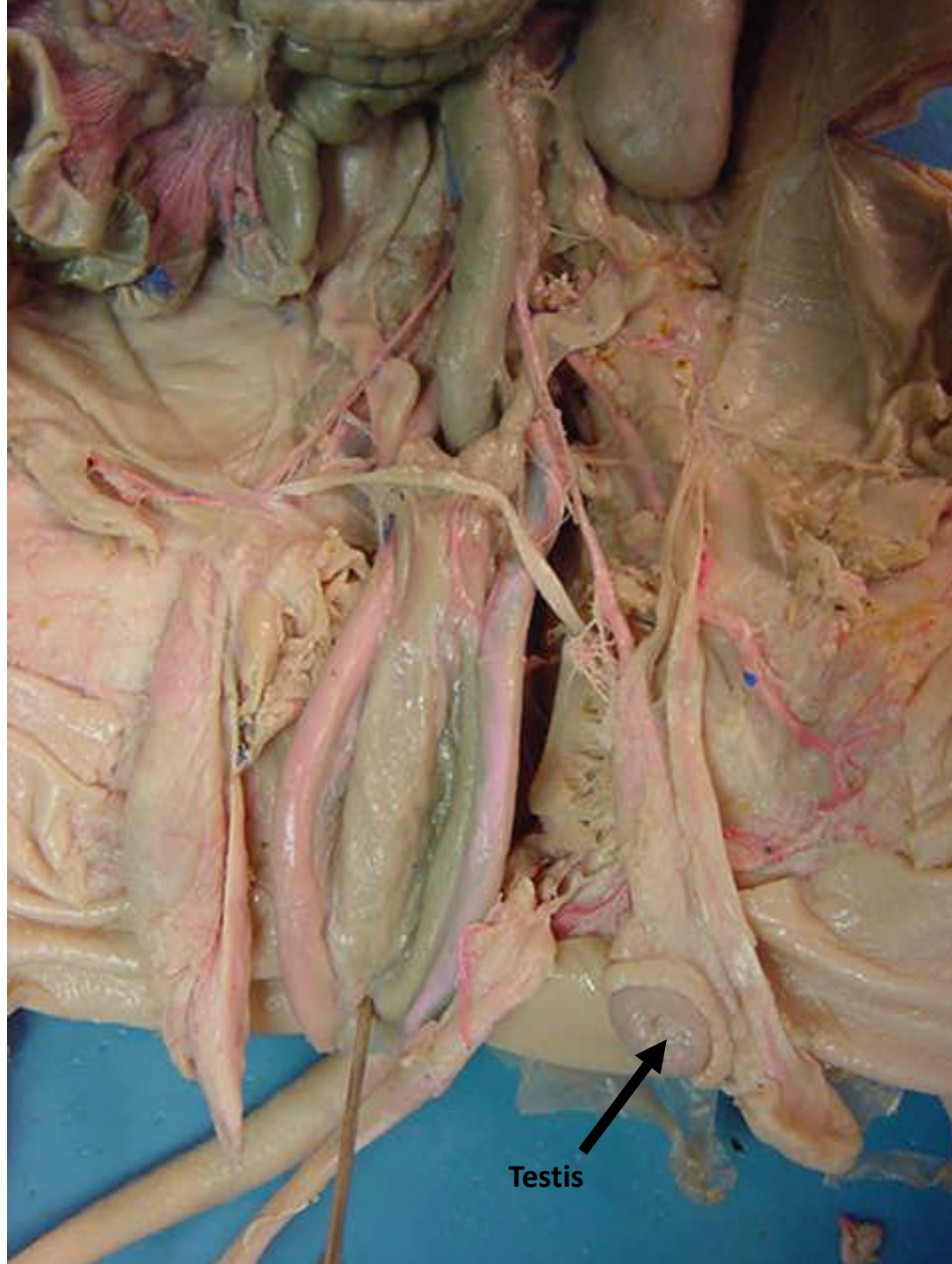




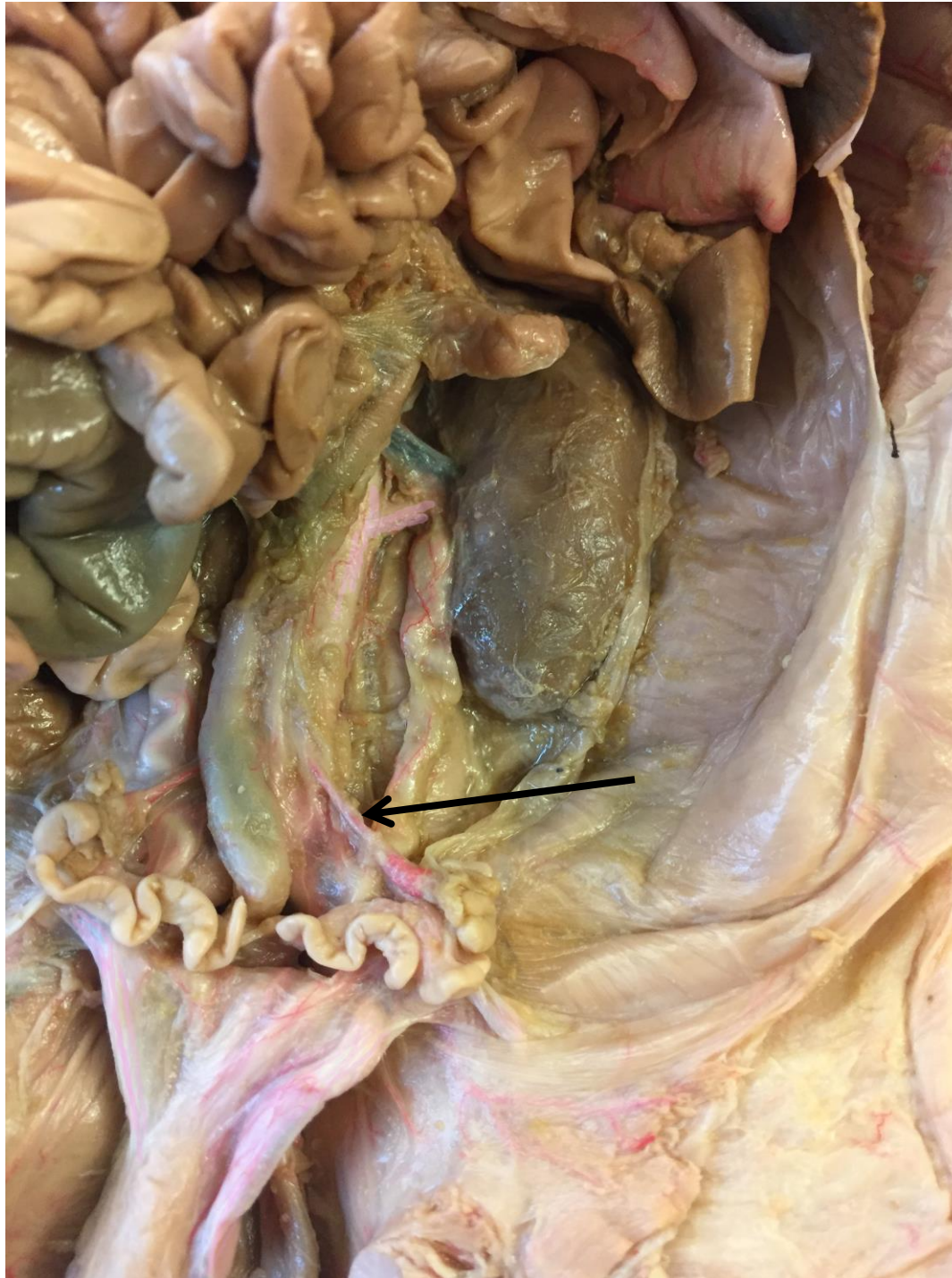Processus
vaginalis



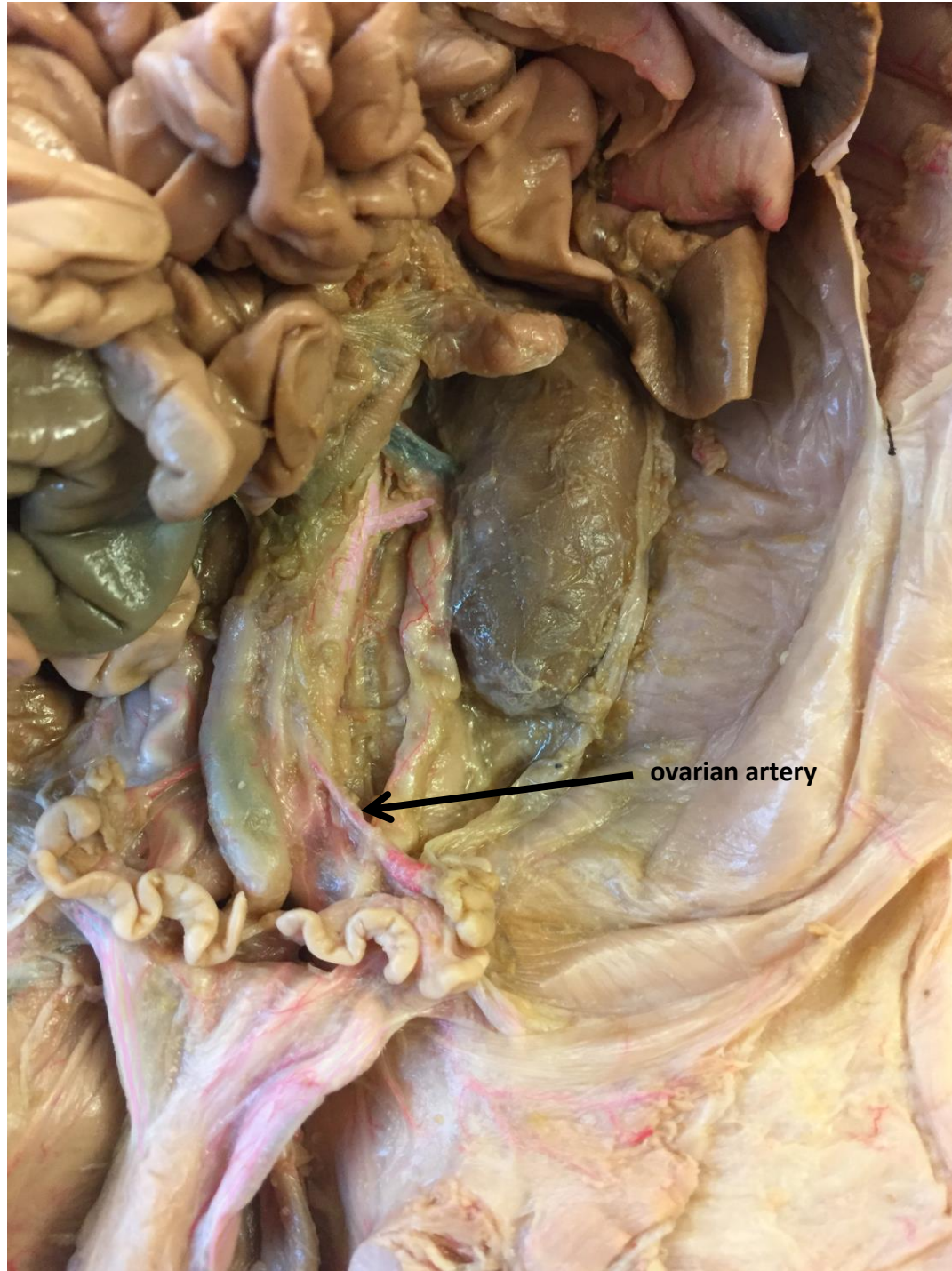*scroll to the next slide to check your answer



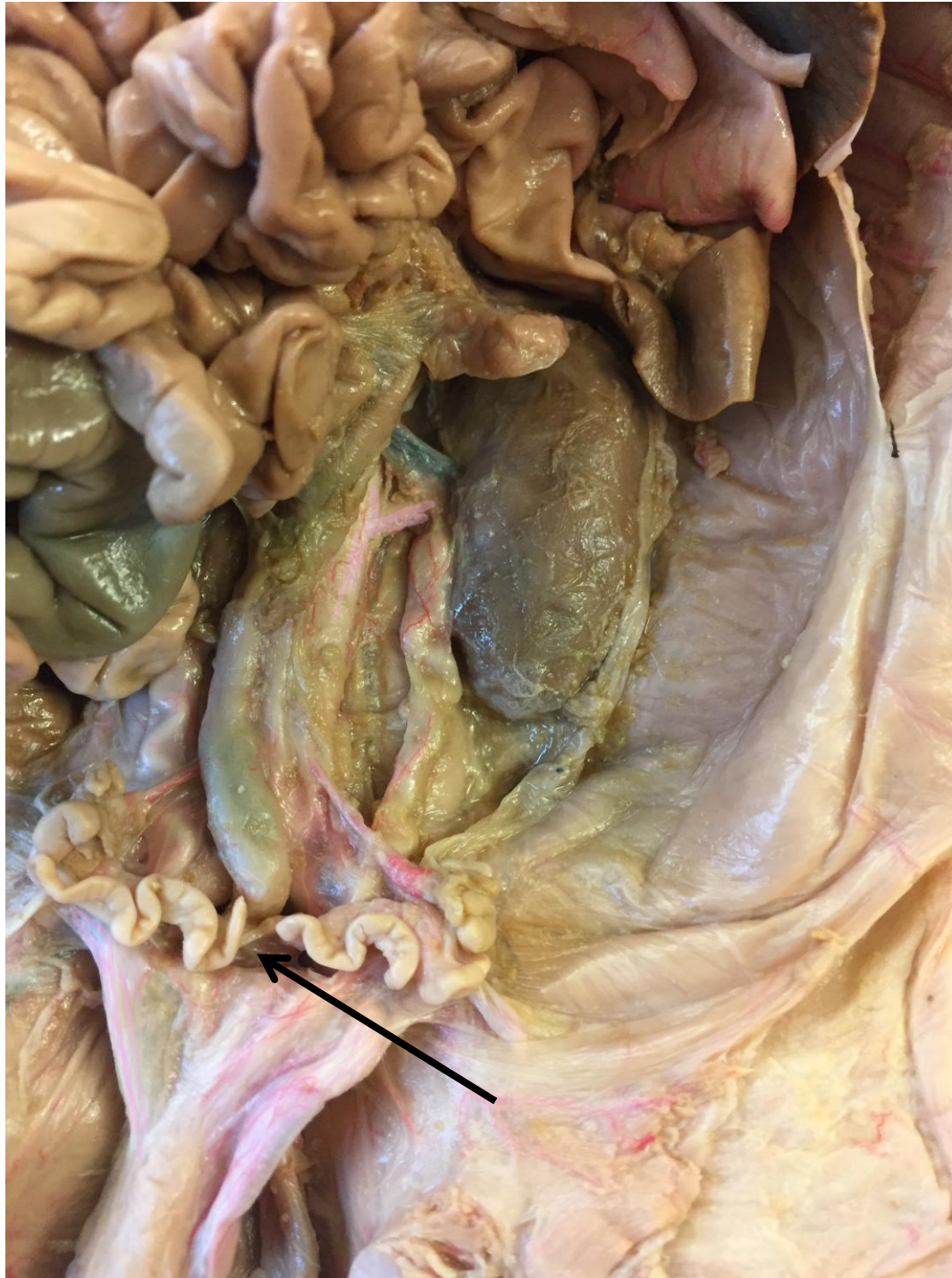Testis



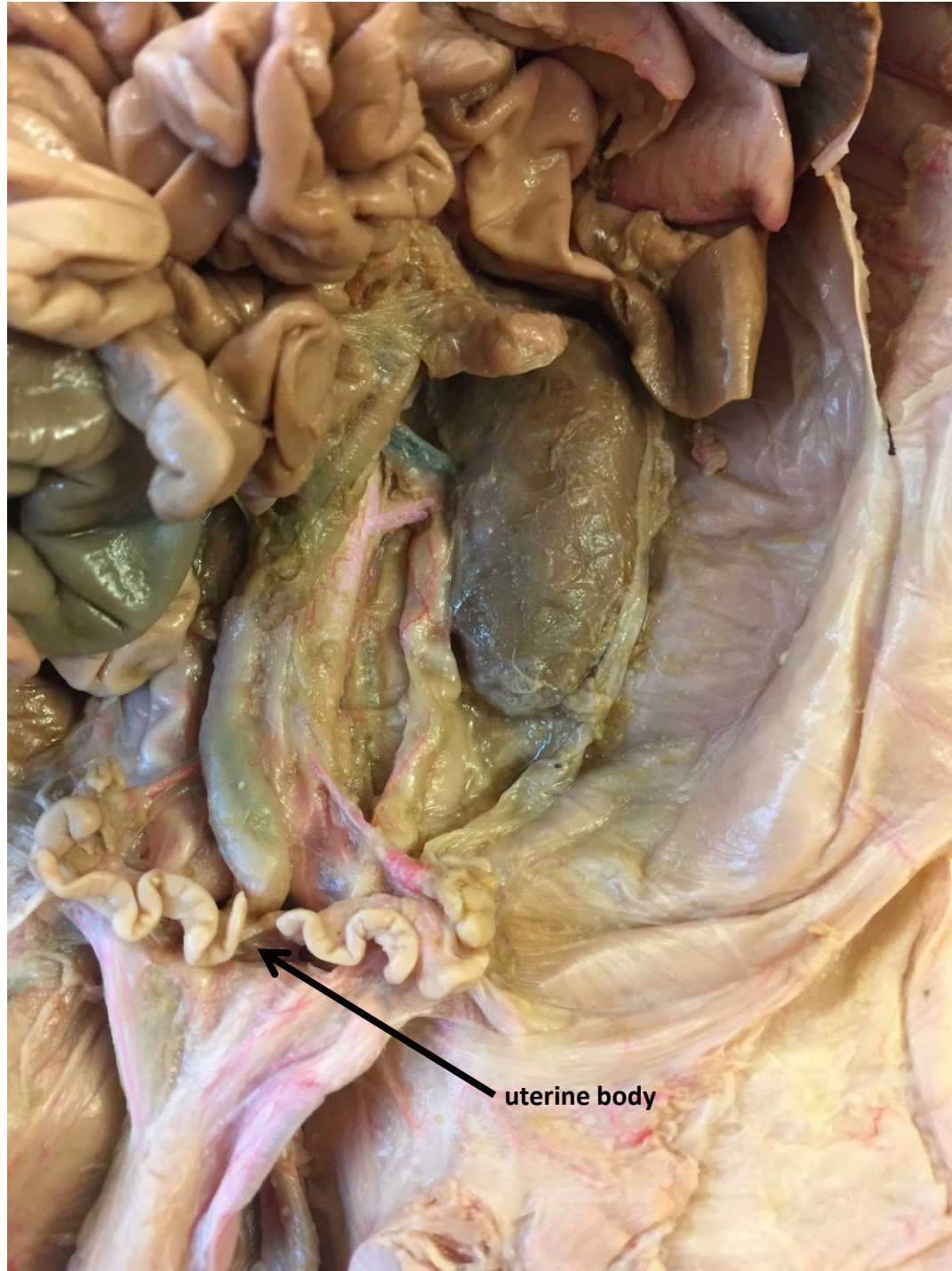*scroll to the next slide to check your answer



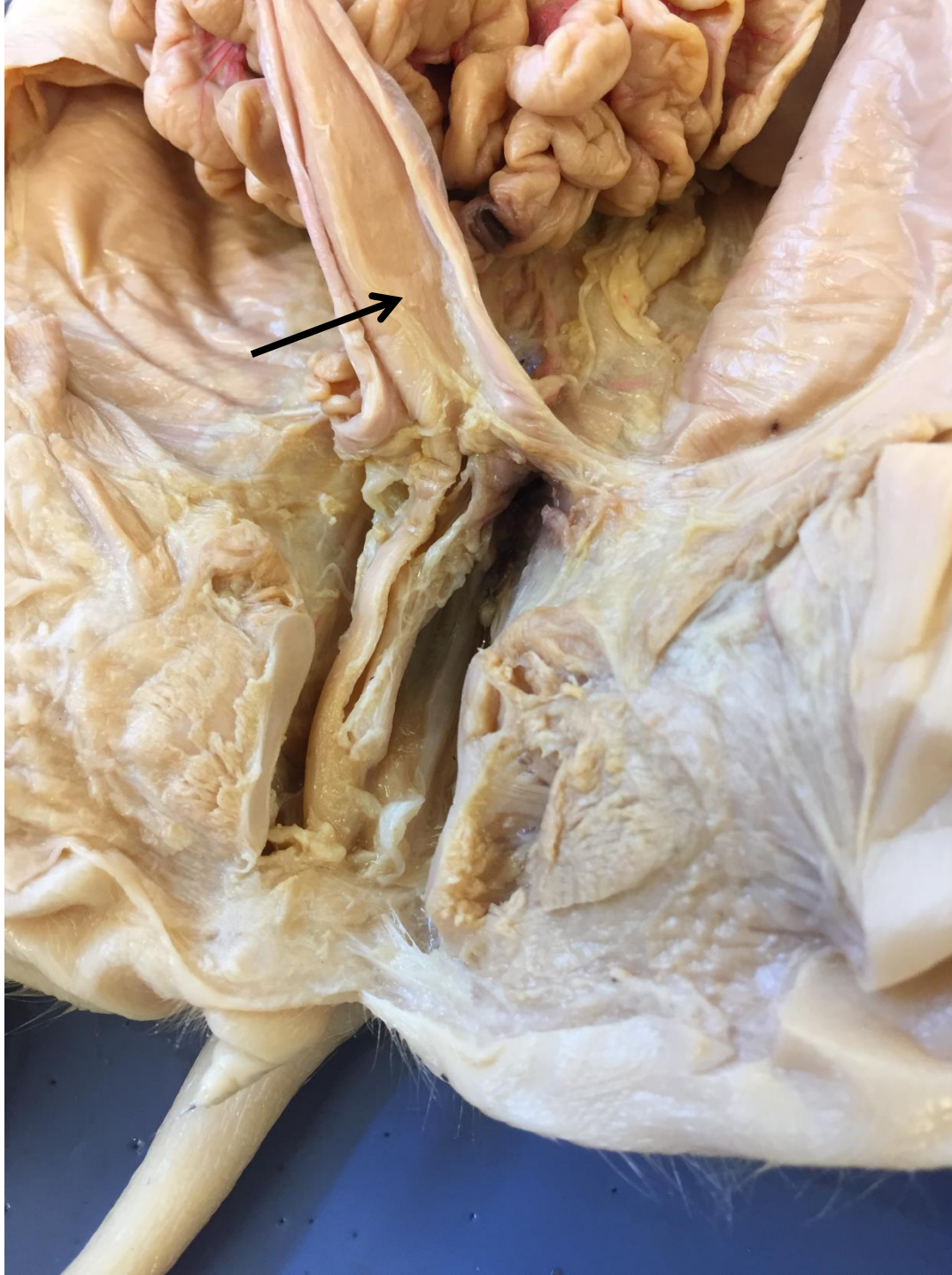ovarian artery



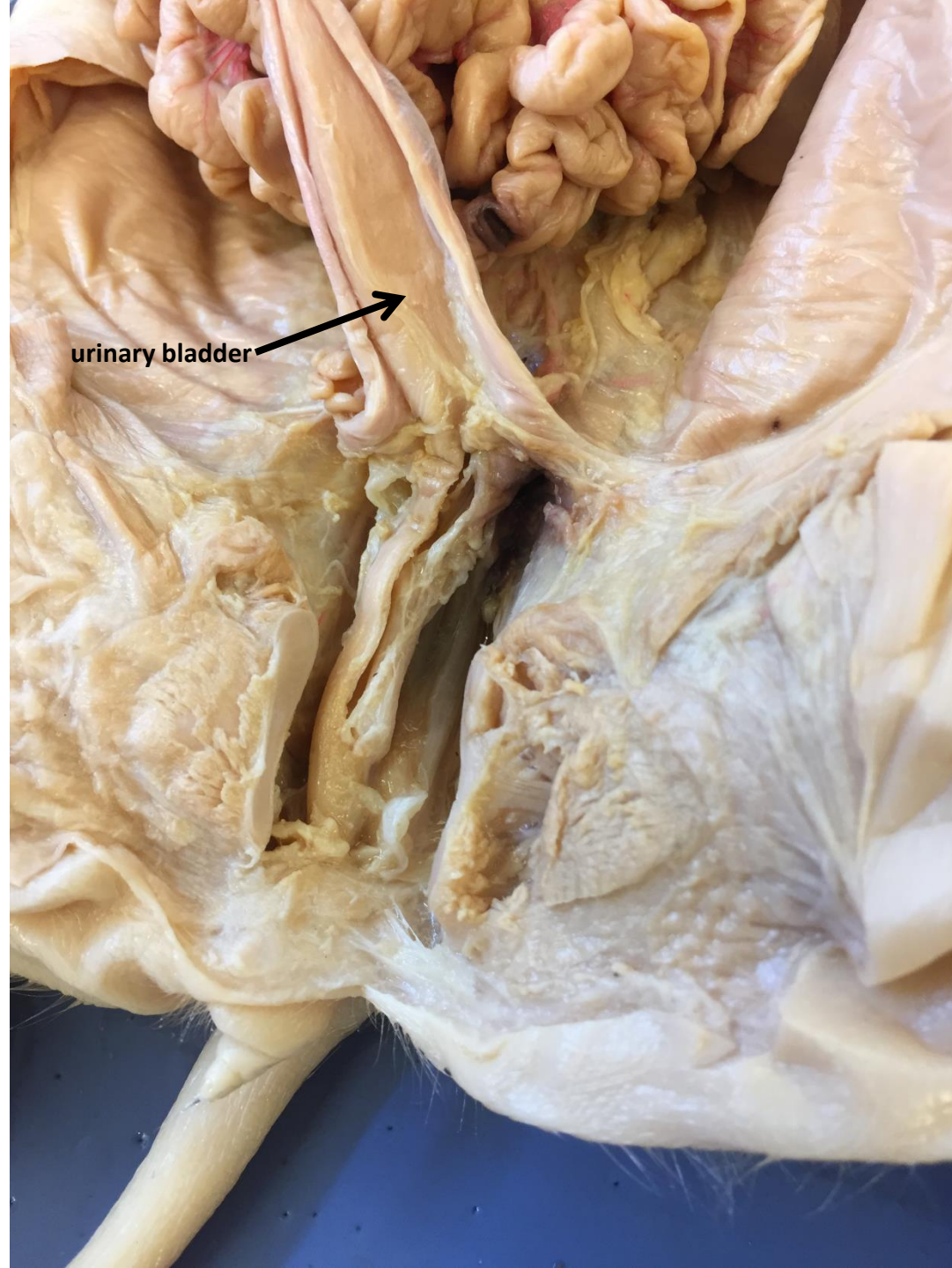*scroll to the next slide to check your answer



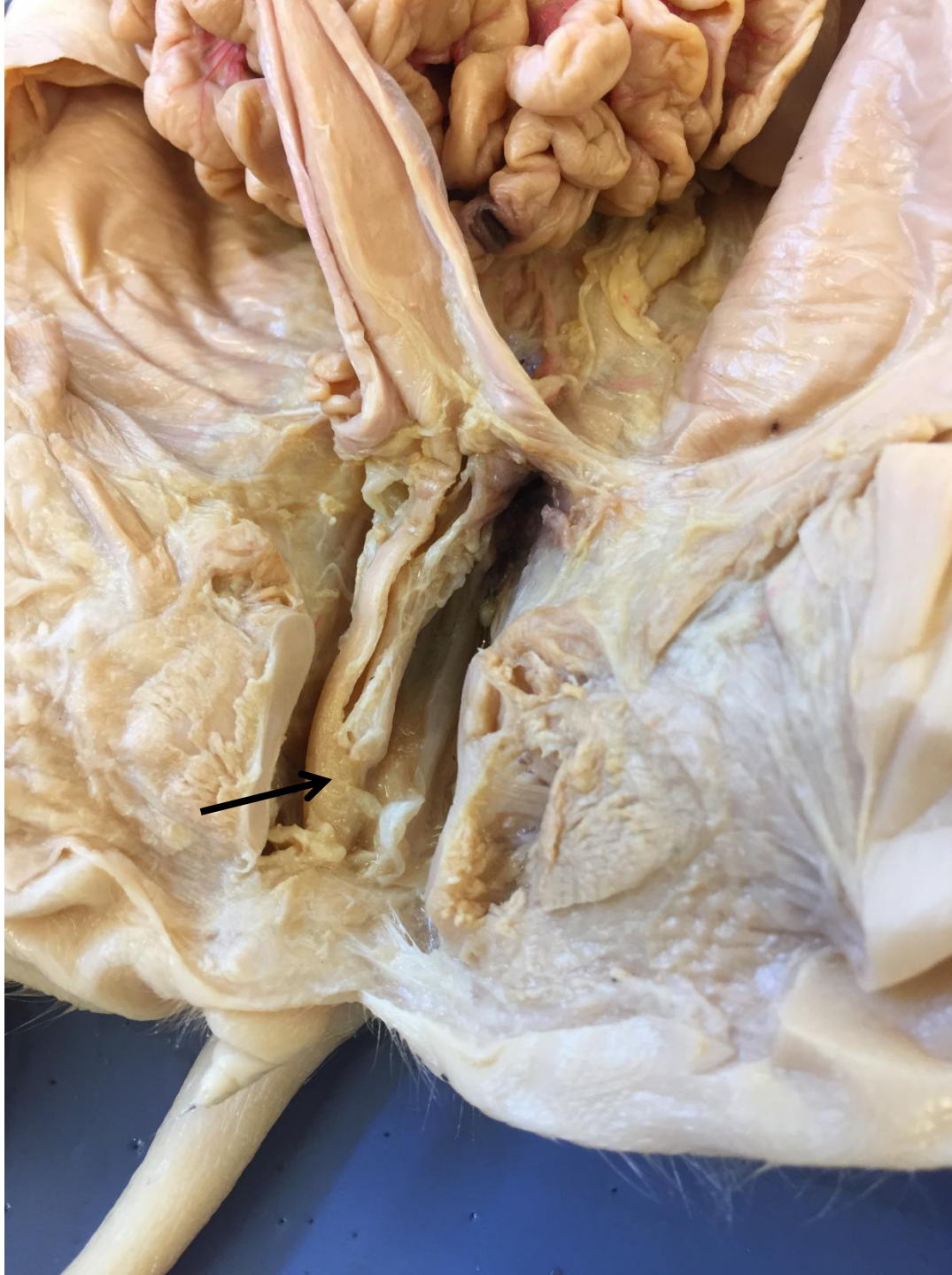
uterine body



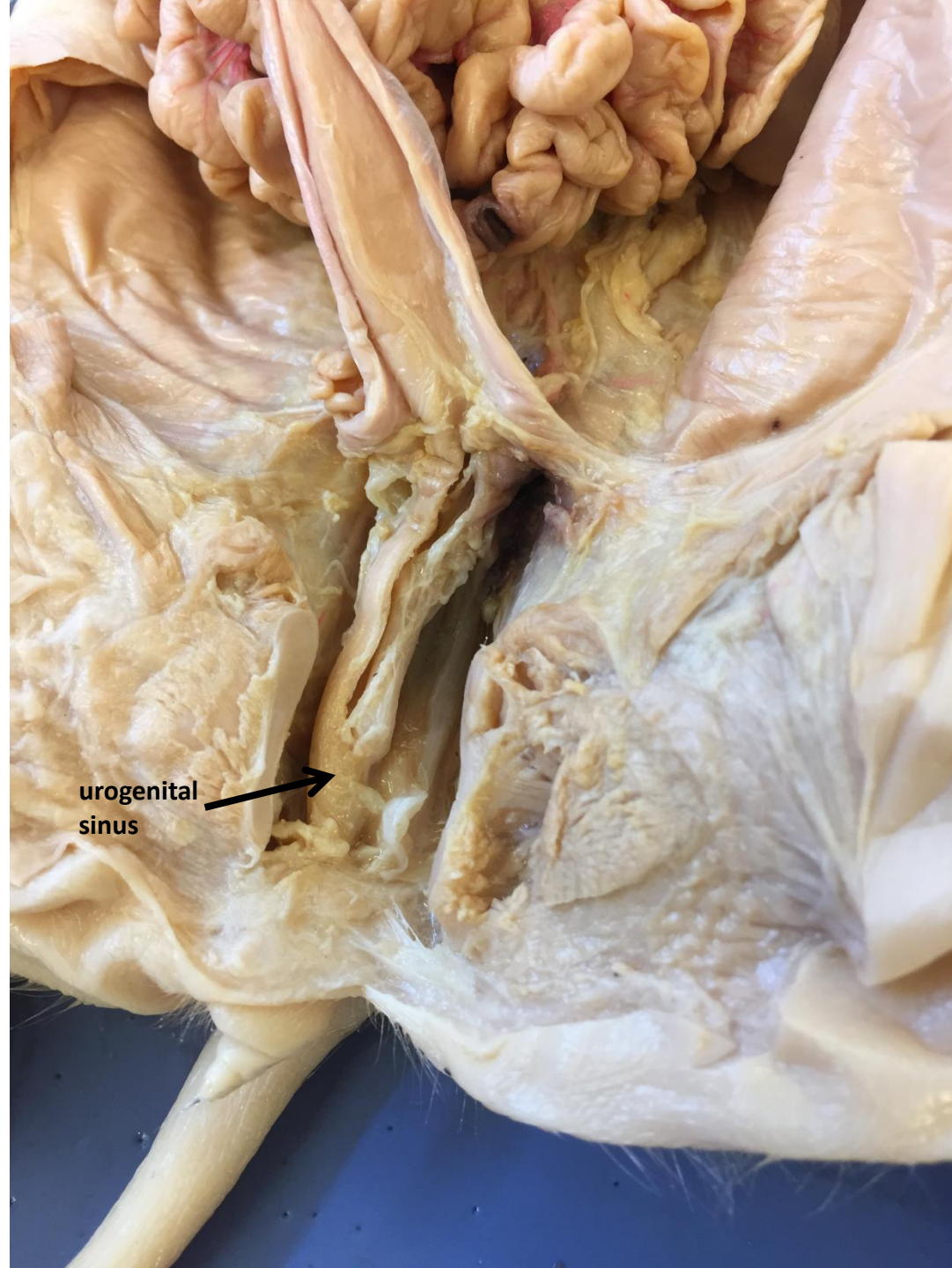*scroll to the next slide to check your answer



urinary bladder



*scroll to the
next slide to
check your
answer



urogenital
sinus