

Fetal Pig Practice Exam

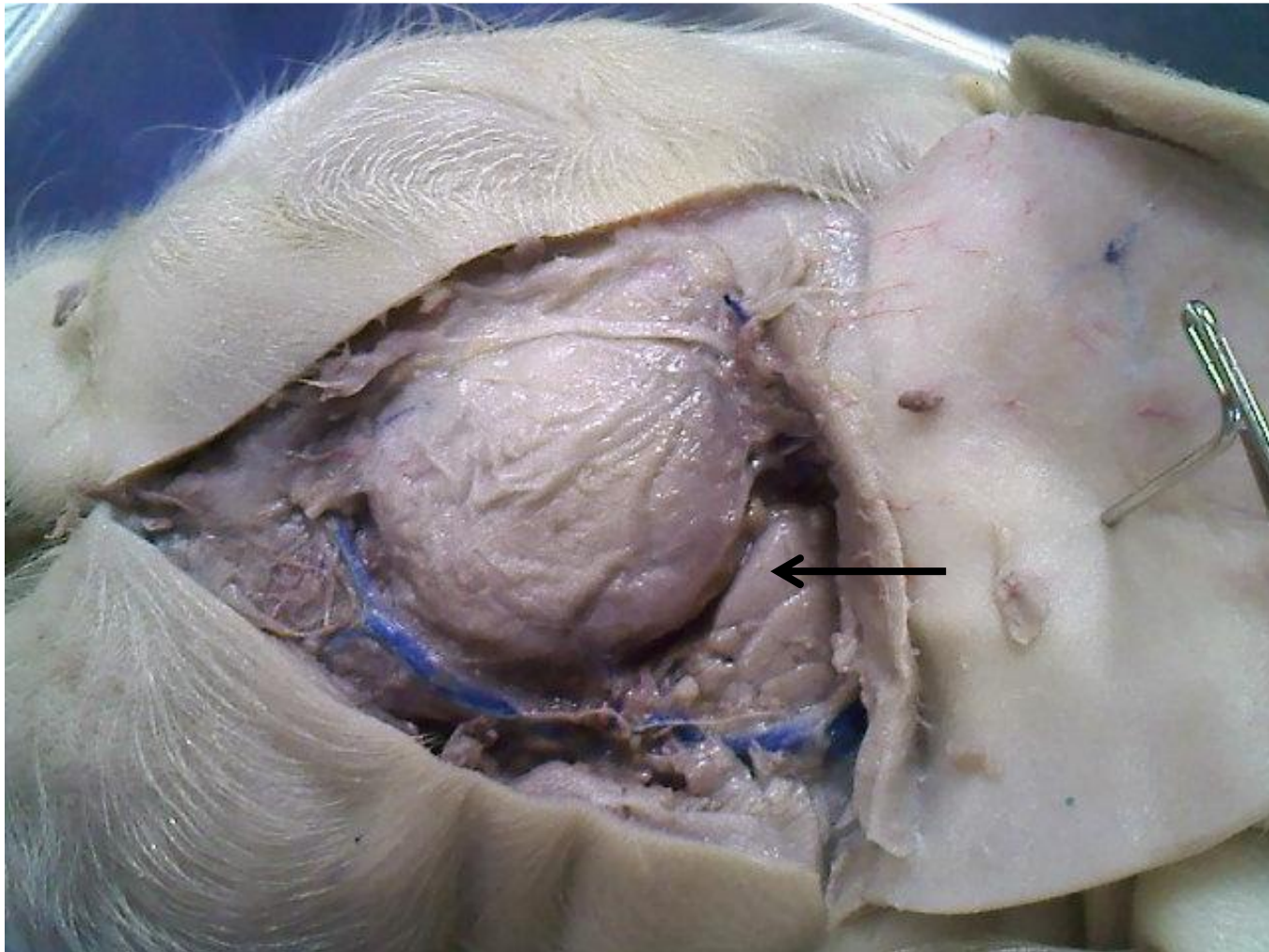
#3

Name the following structures indicated by the arrows.

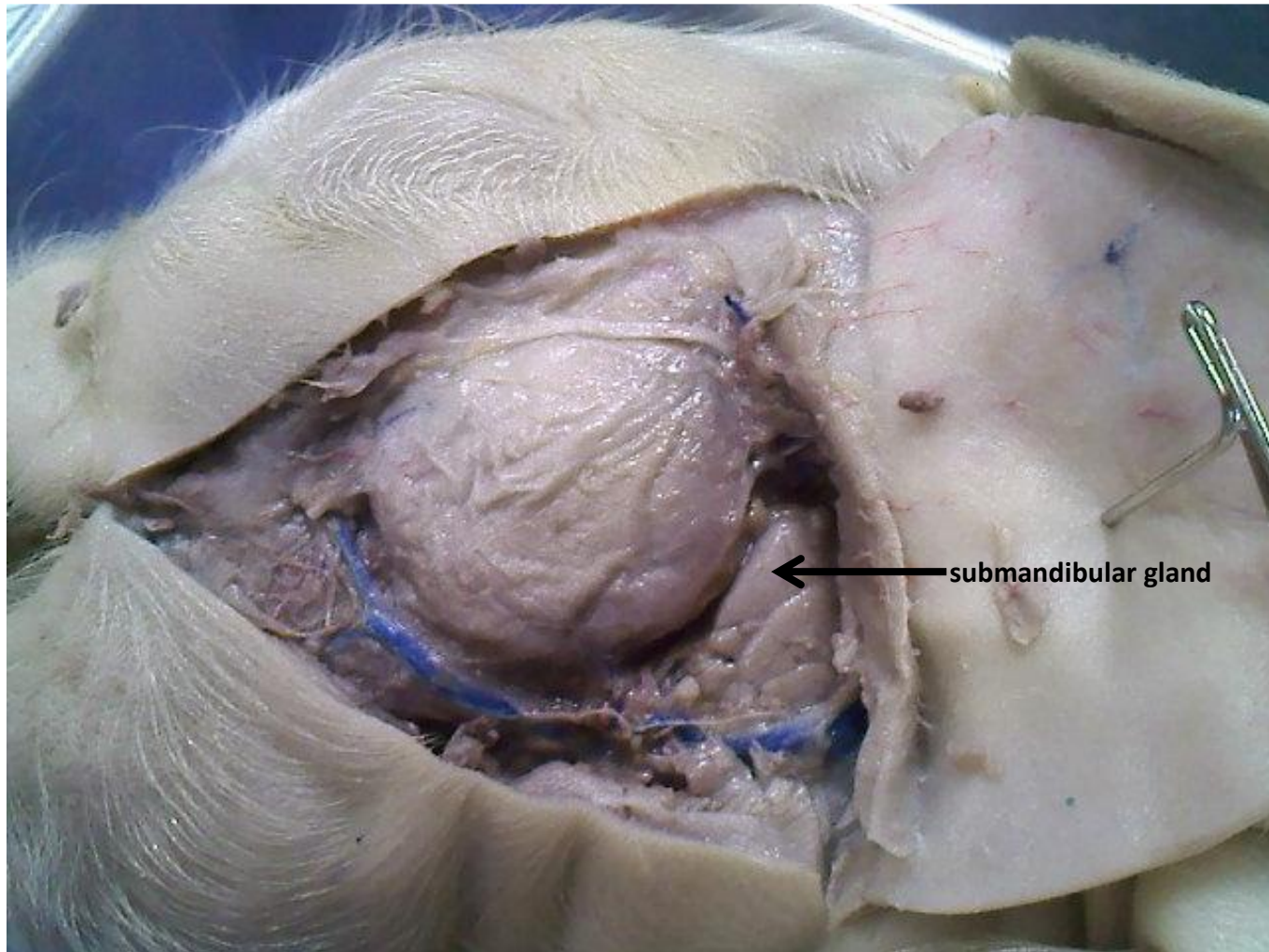
Scroll to the next slide to see the answer.

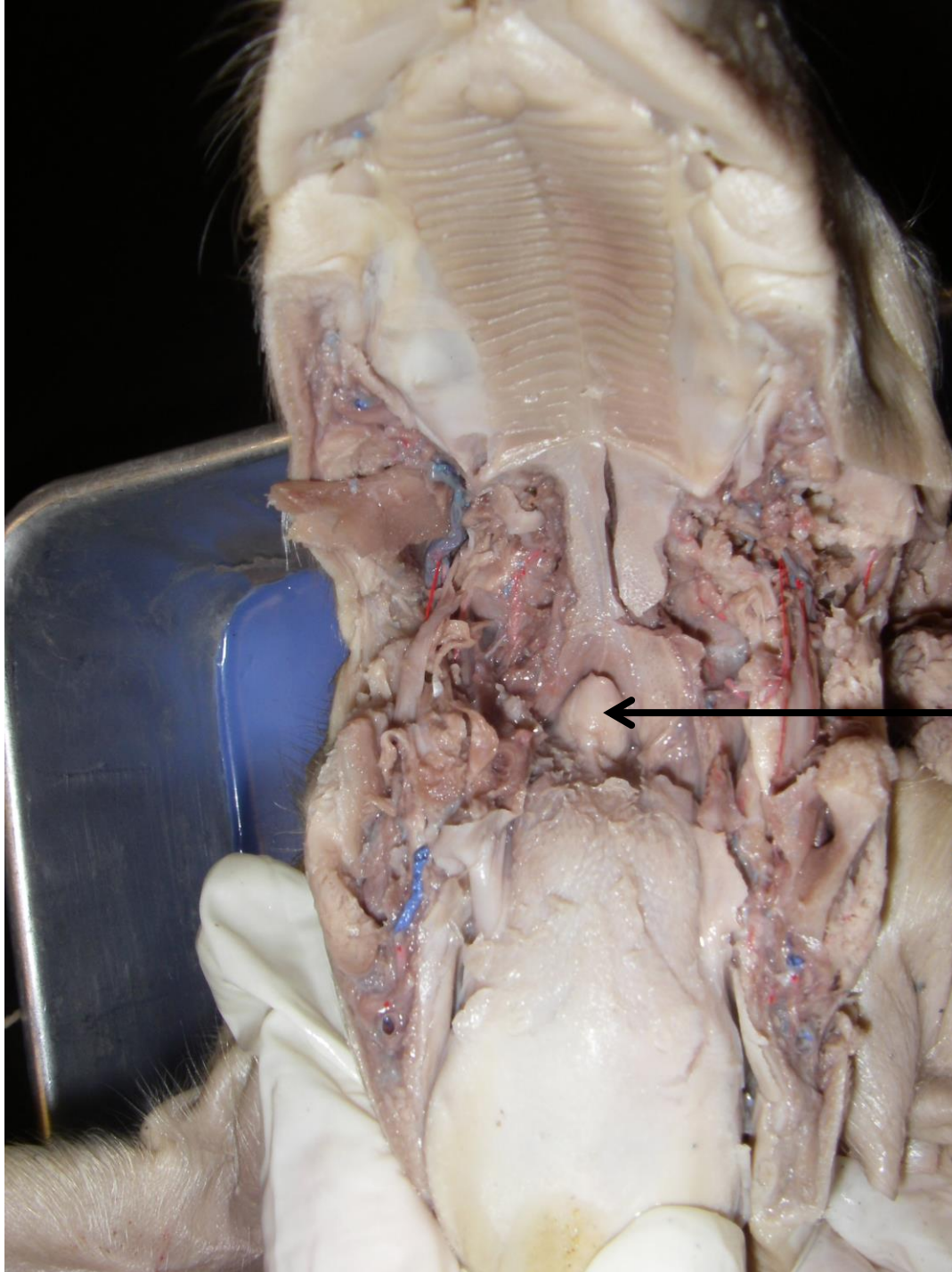
*For best results on these practice exams, write your answers on paper before scrolling to see the correct answer. Try to answer within a minute (remember your lab exams will be timed) and make sure to check your spelling!

*note: not every structure you are required to know will be on this practice exercise so make sure you review the checklist of structures (p. 178-179 in your lab manual) when preparing for your lab exam

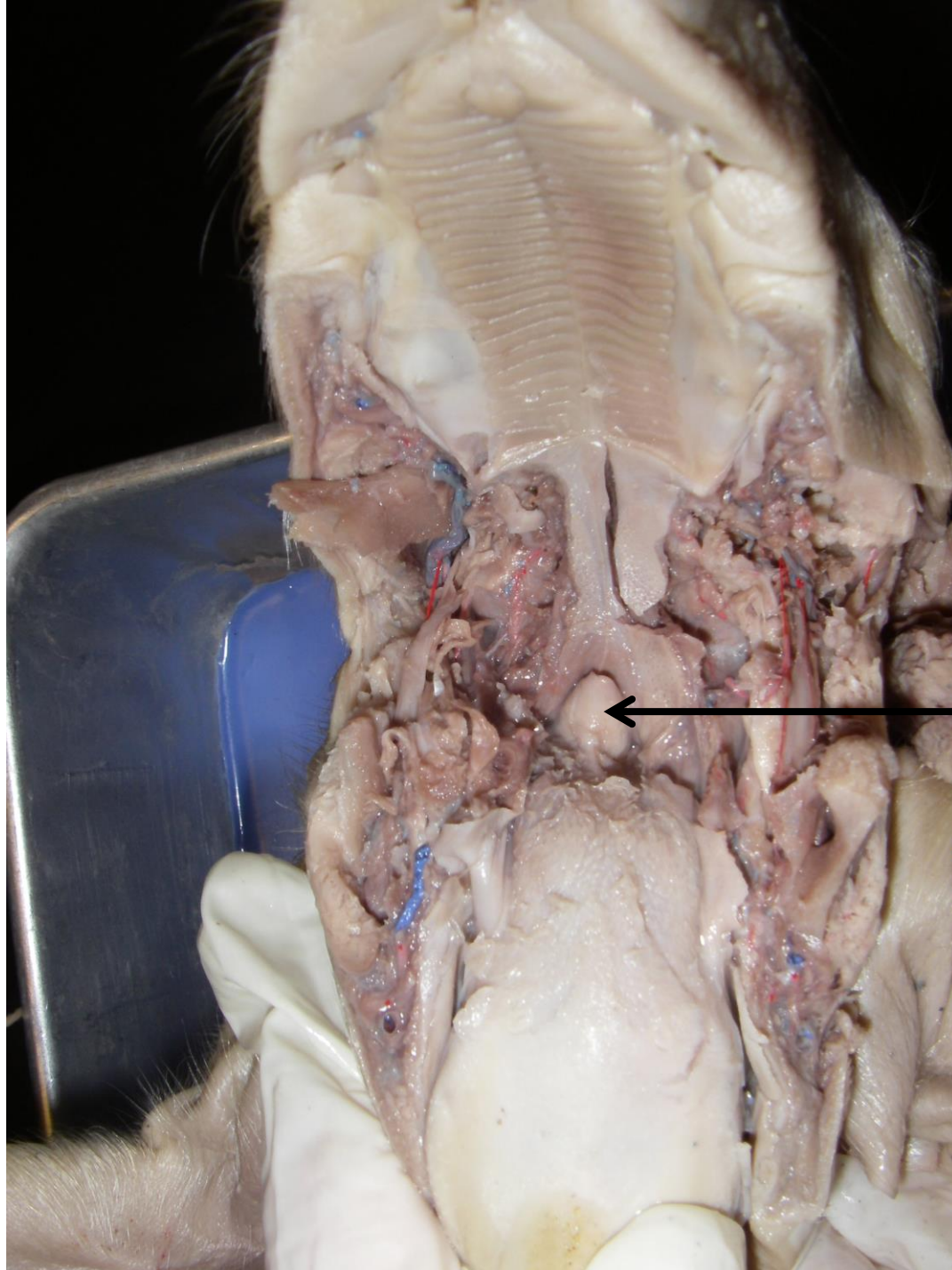


*scroll to the next slide
to check your answer

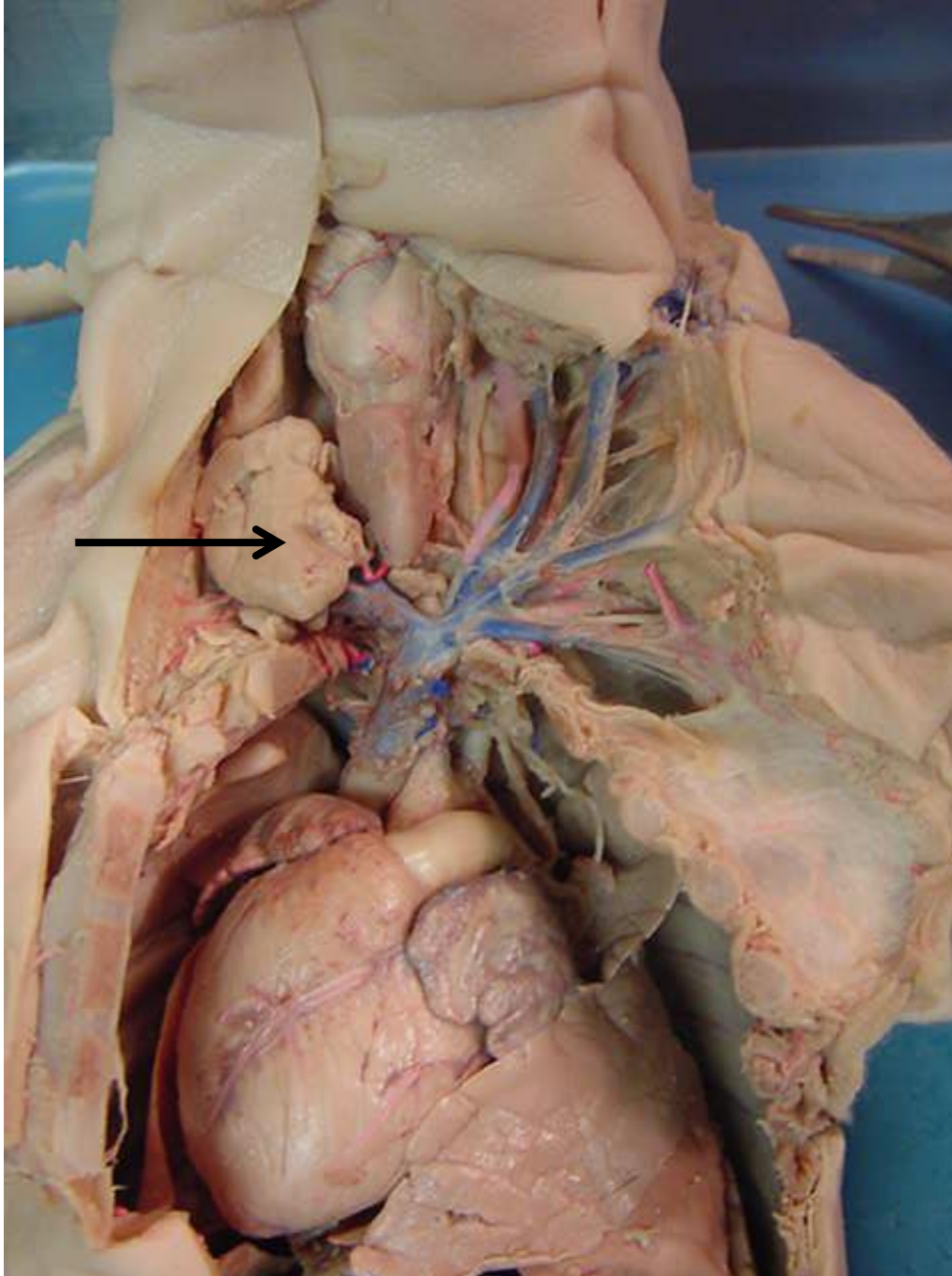




*scroll to the next slide
to check your answer

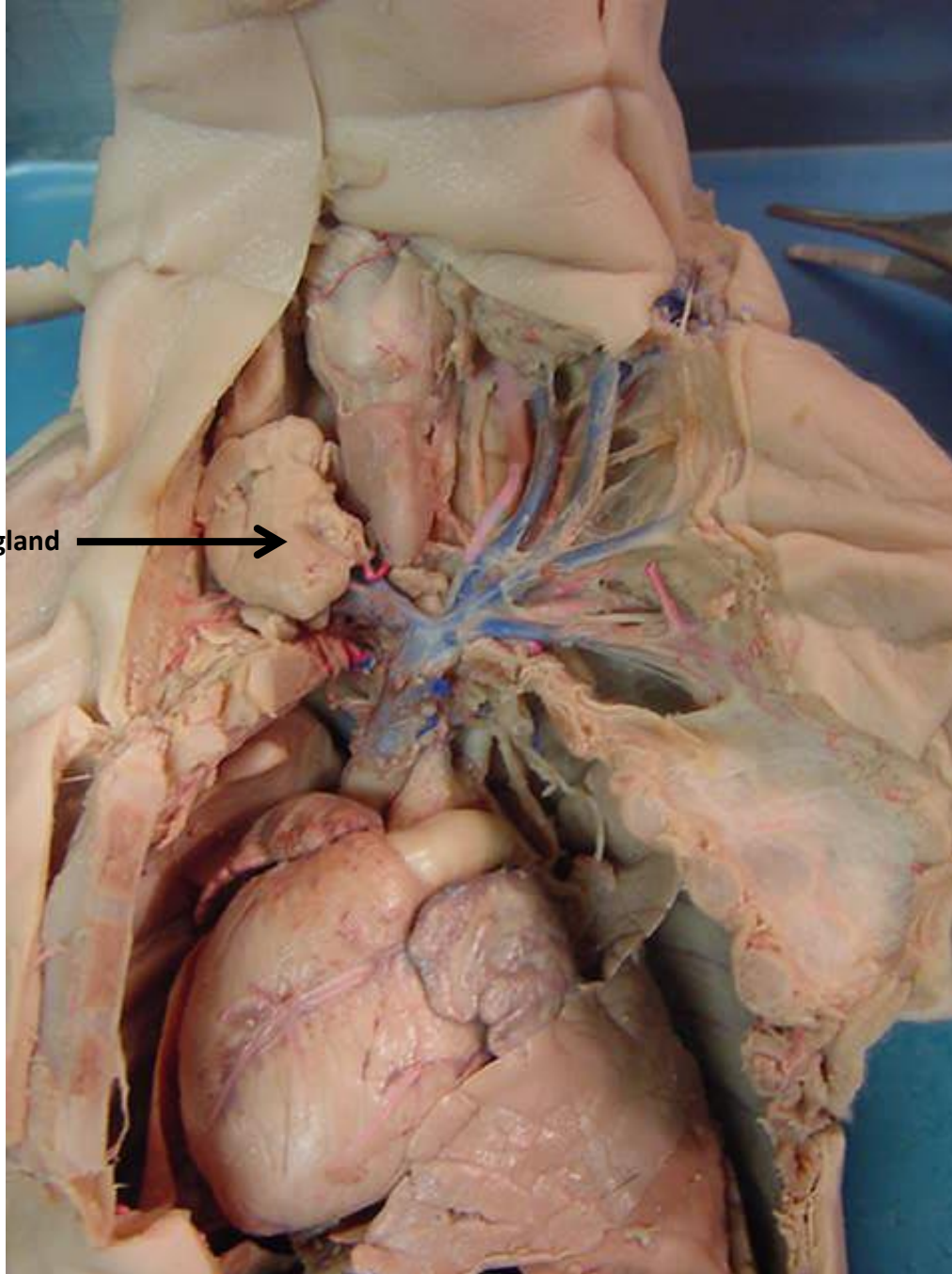


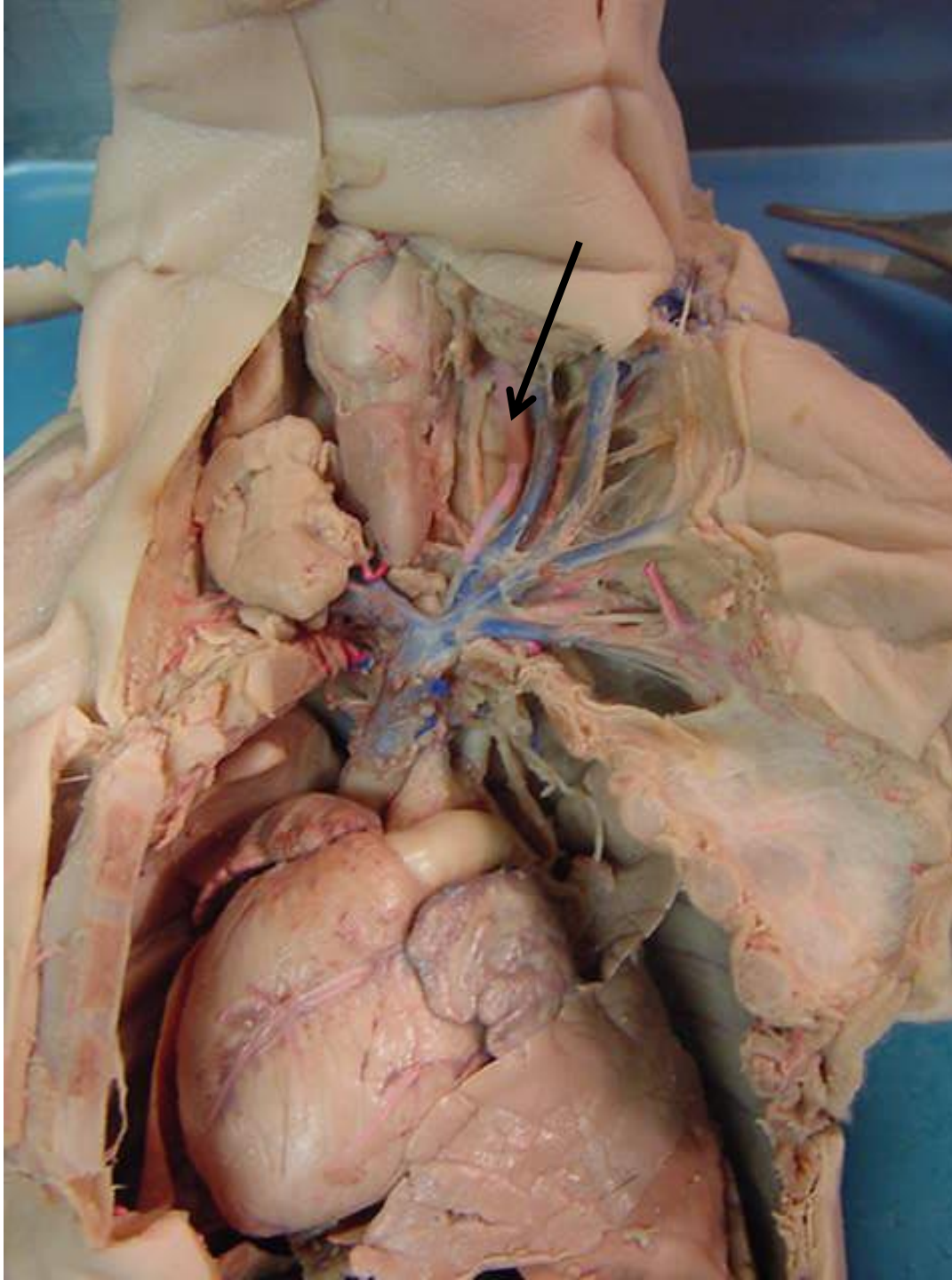
← epiglottis



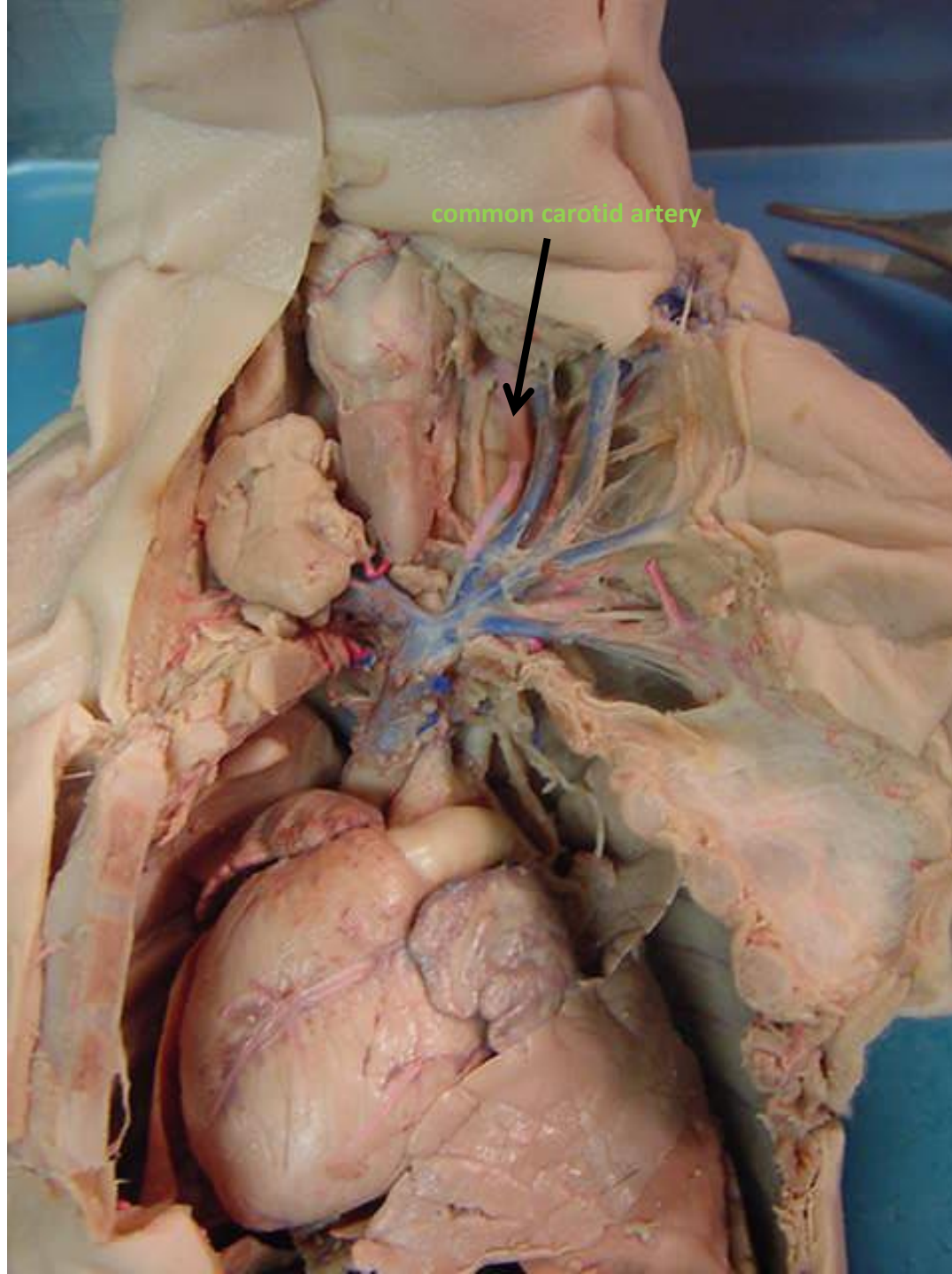
*scroll to the next slide
to check your answer

thymus gland →



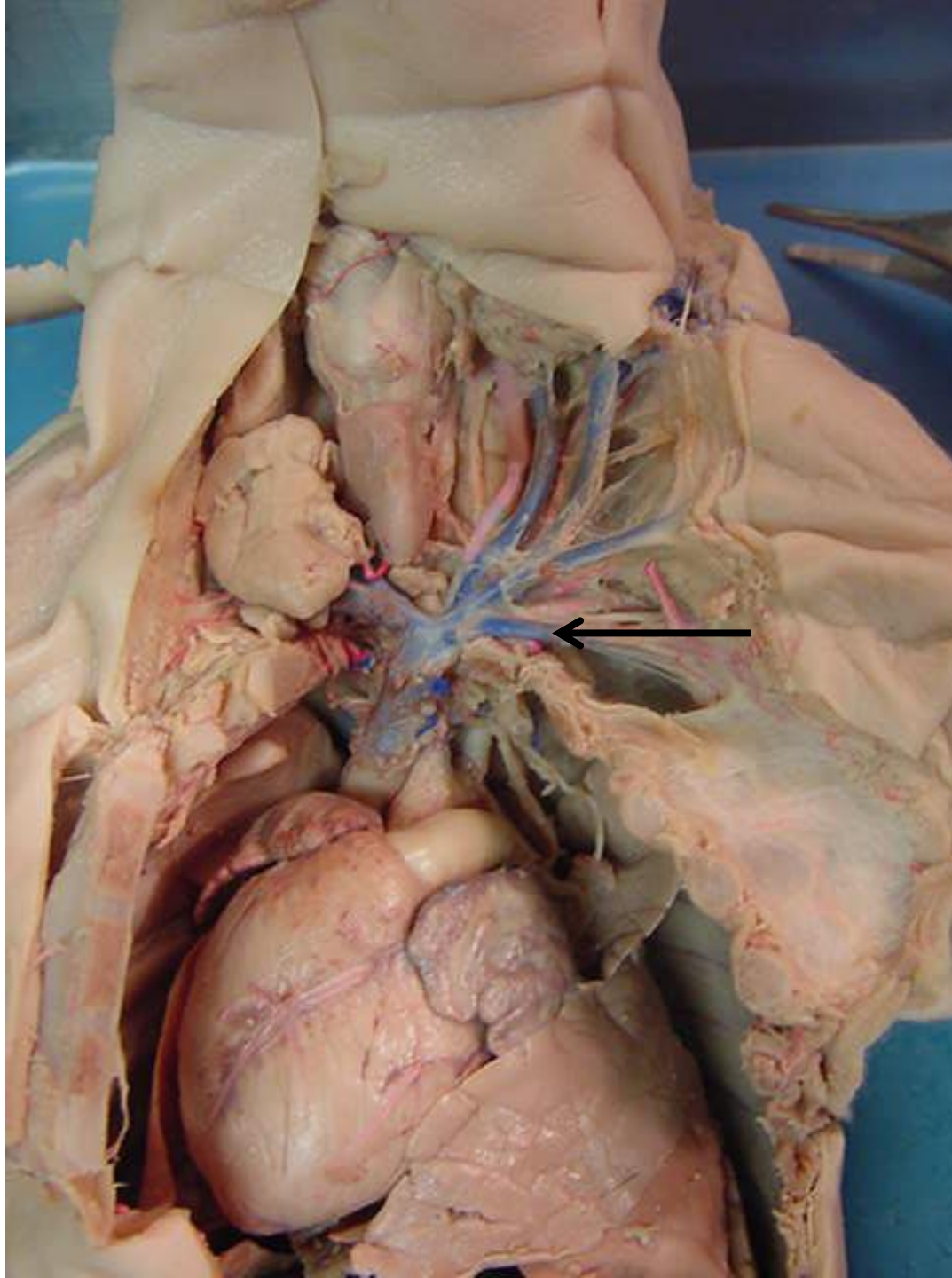


*scroll to the next slide
to check your answer

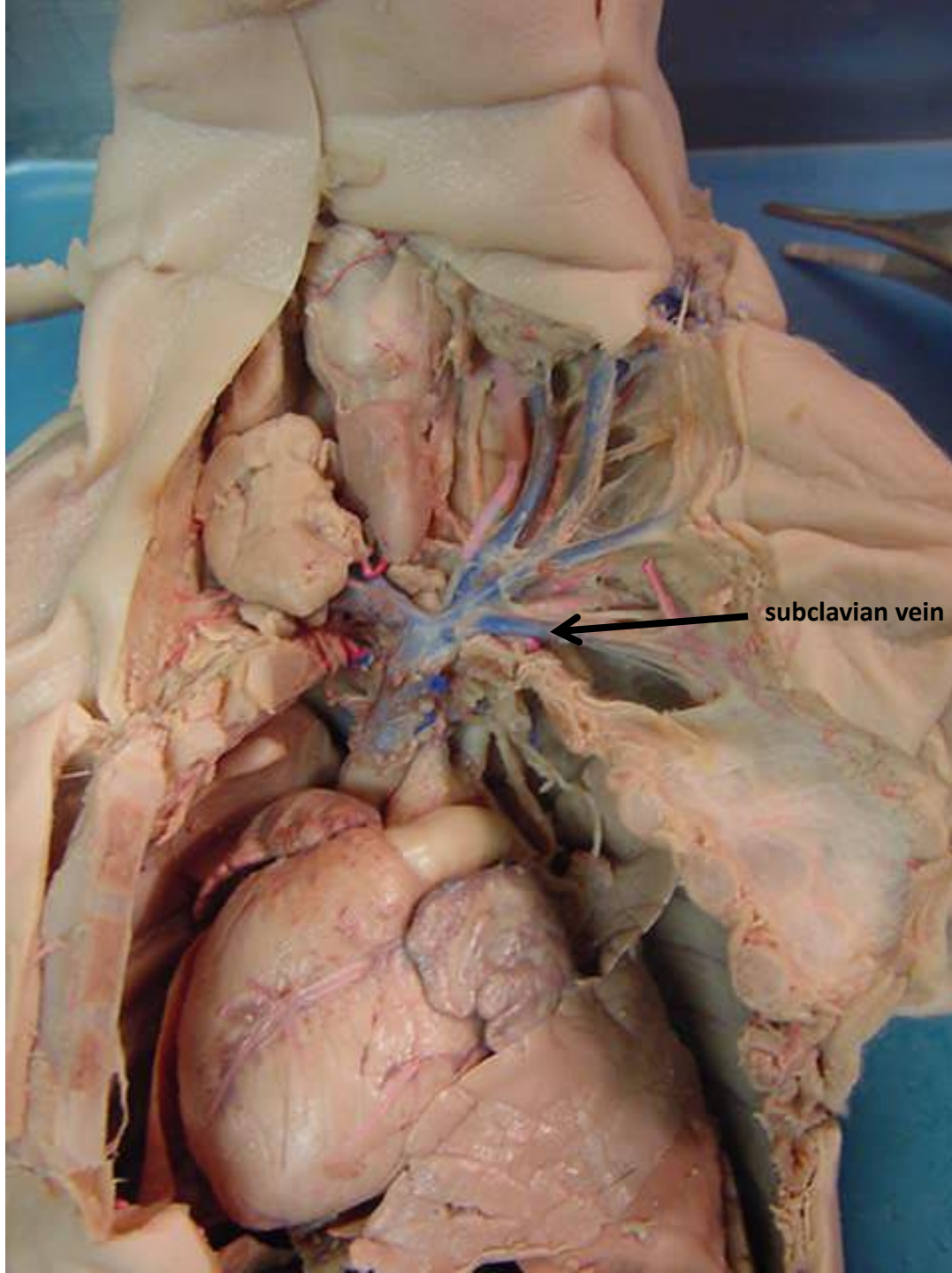


common carotid artery

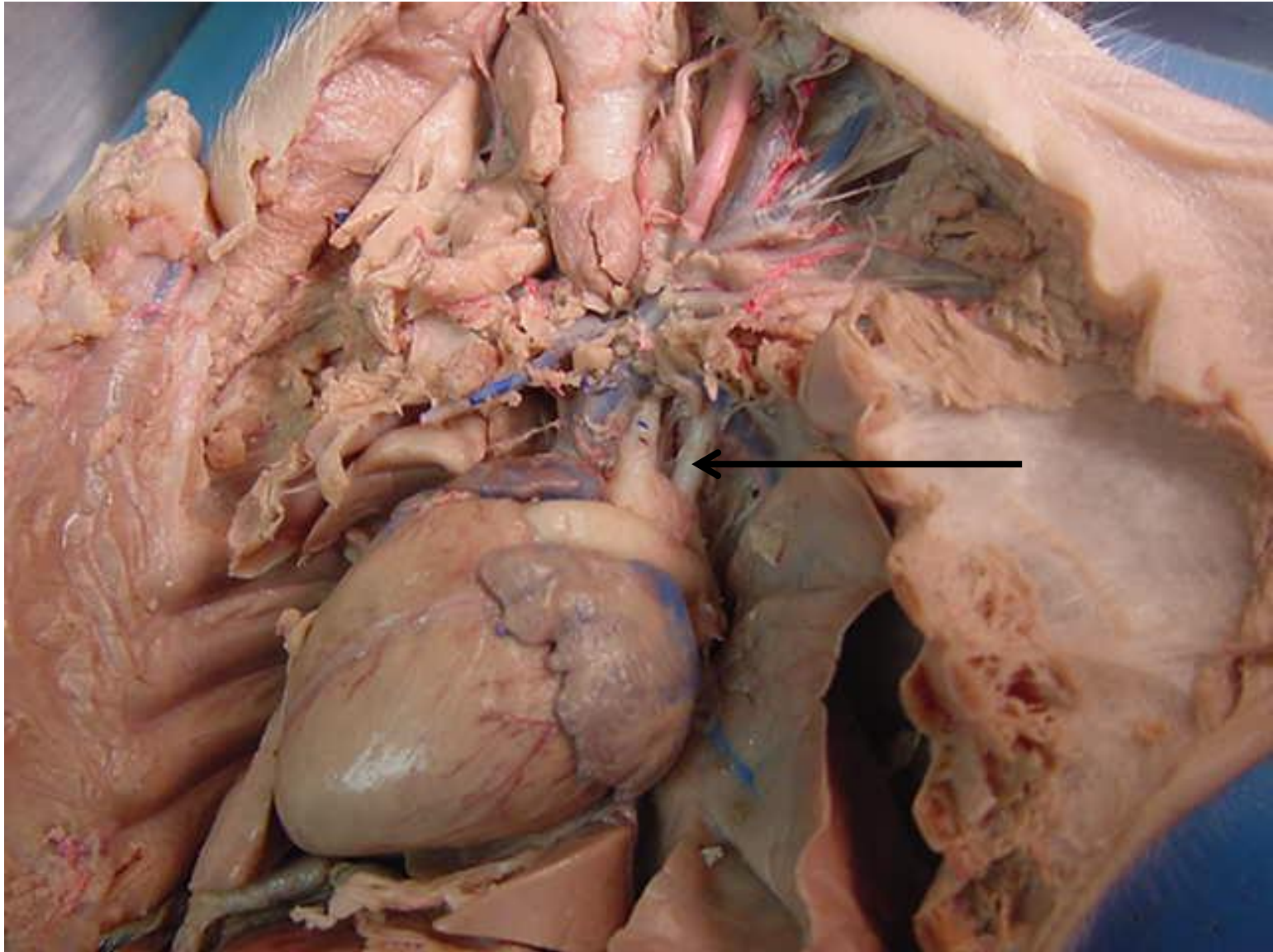




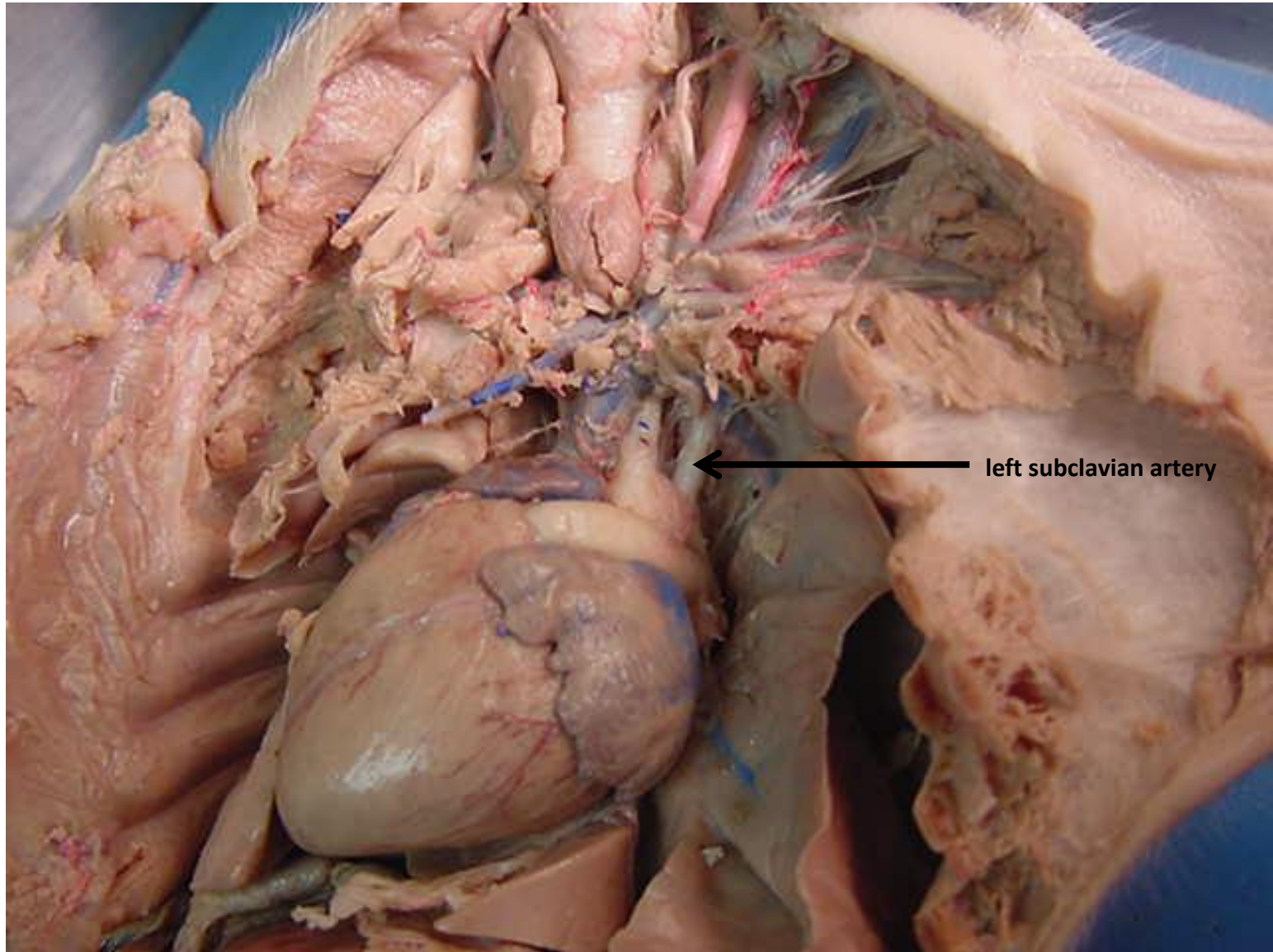
*scroll to the next slide
to check your answer

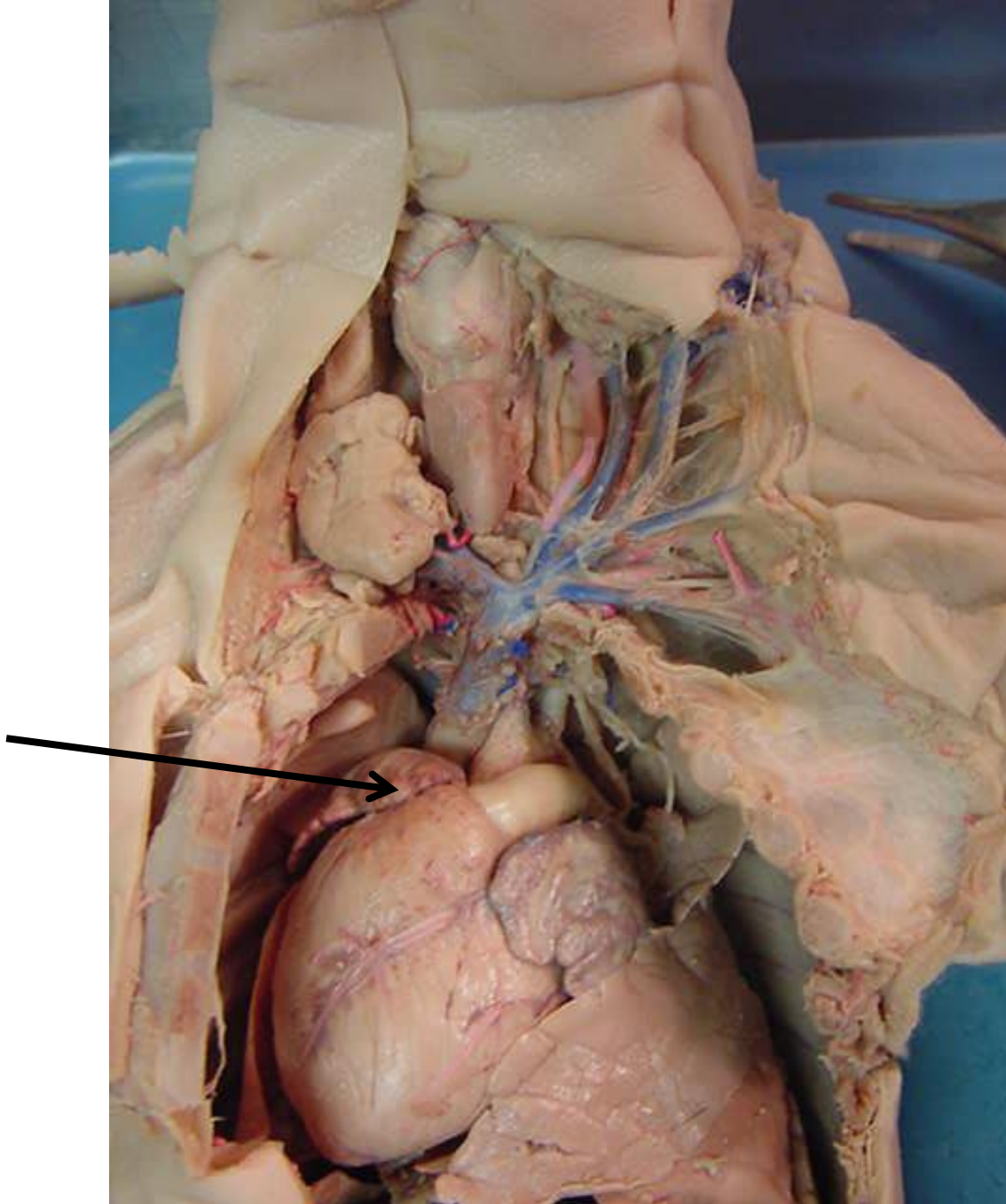


subclavian vein



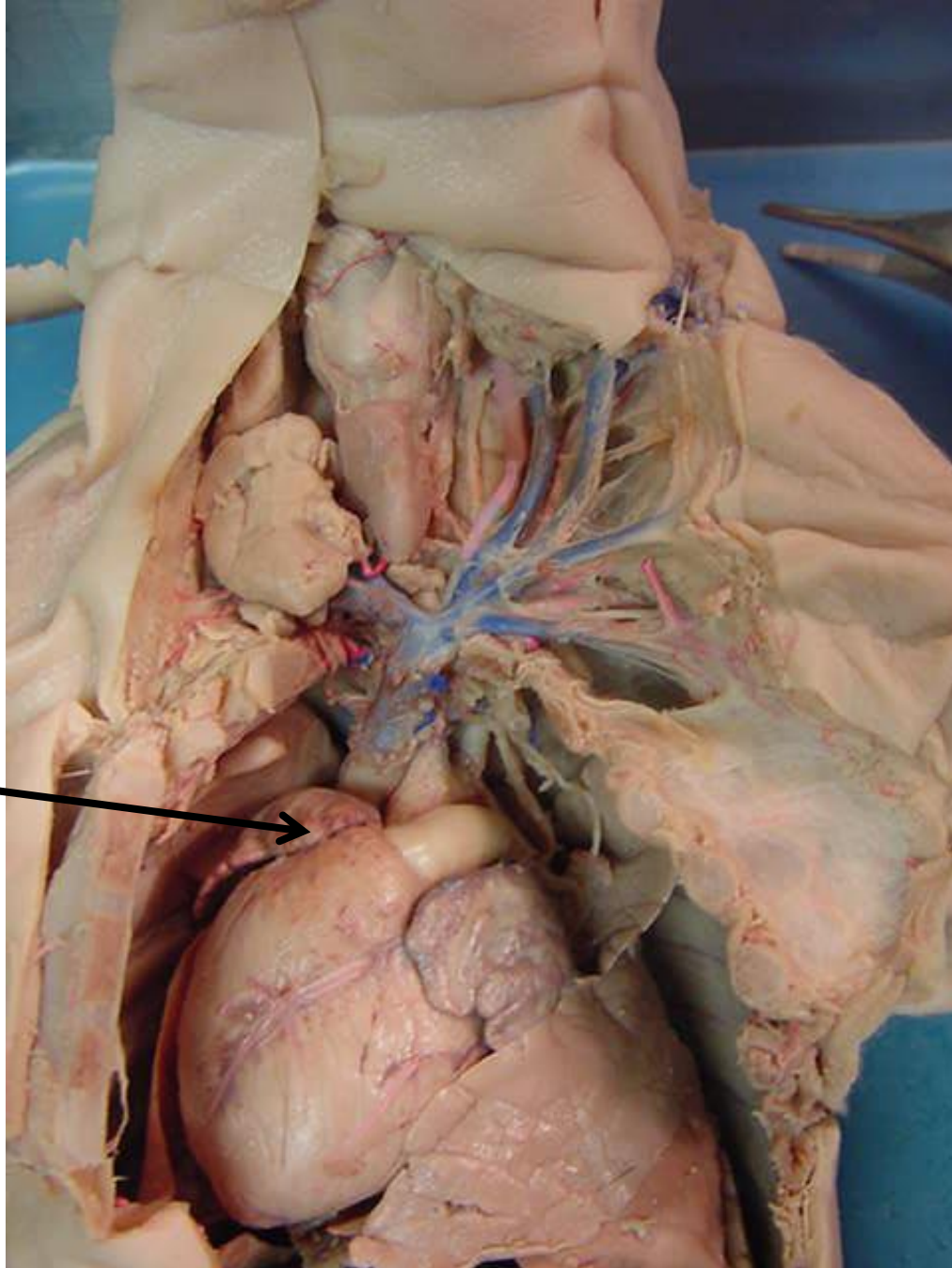
*scroll to the next slide
to check your answer

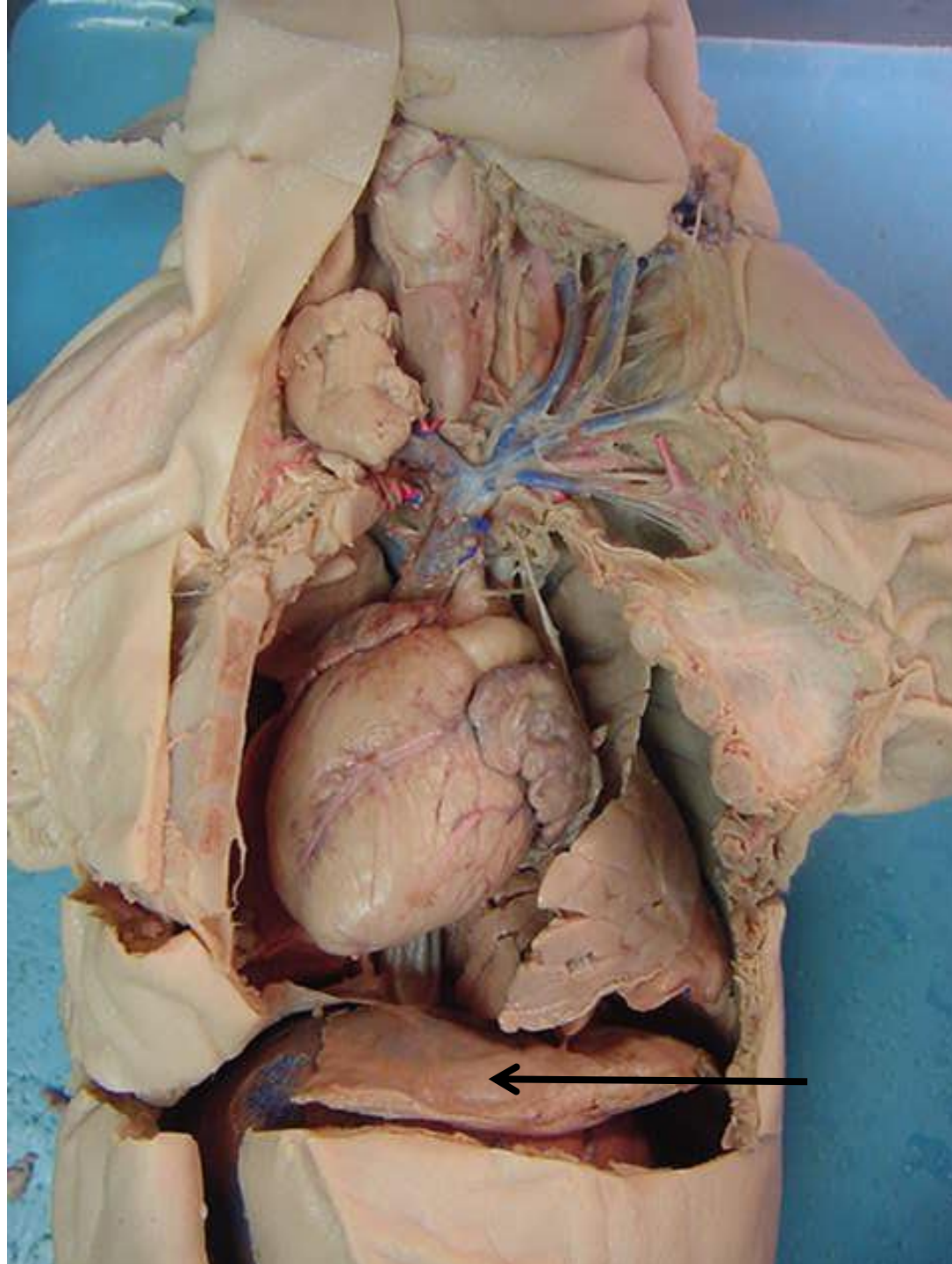




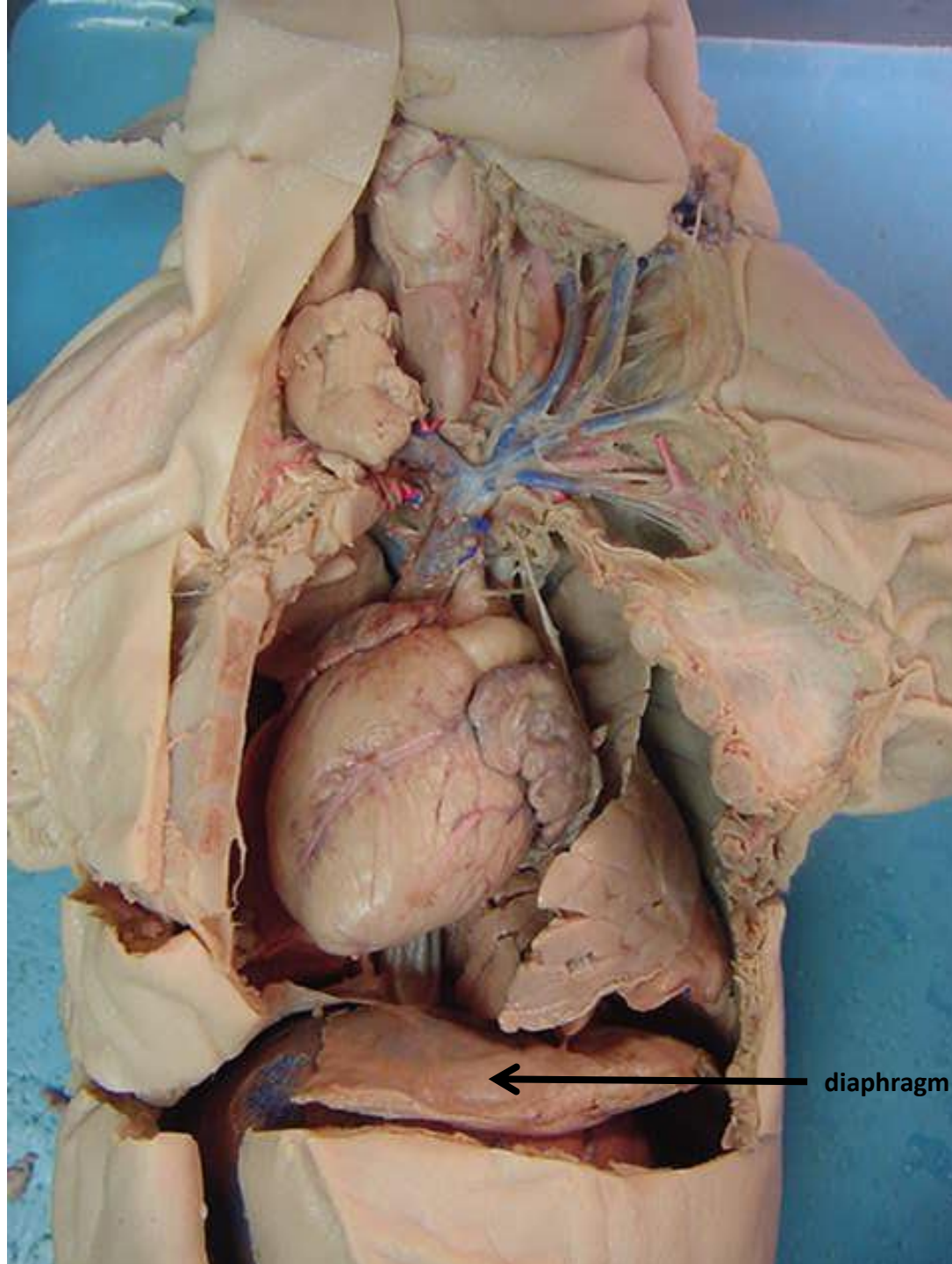
*scroll to the next slide
to check your answer

auricle of
right atrium

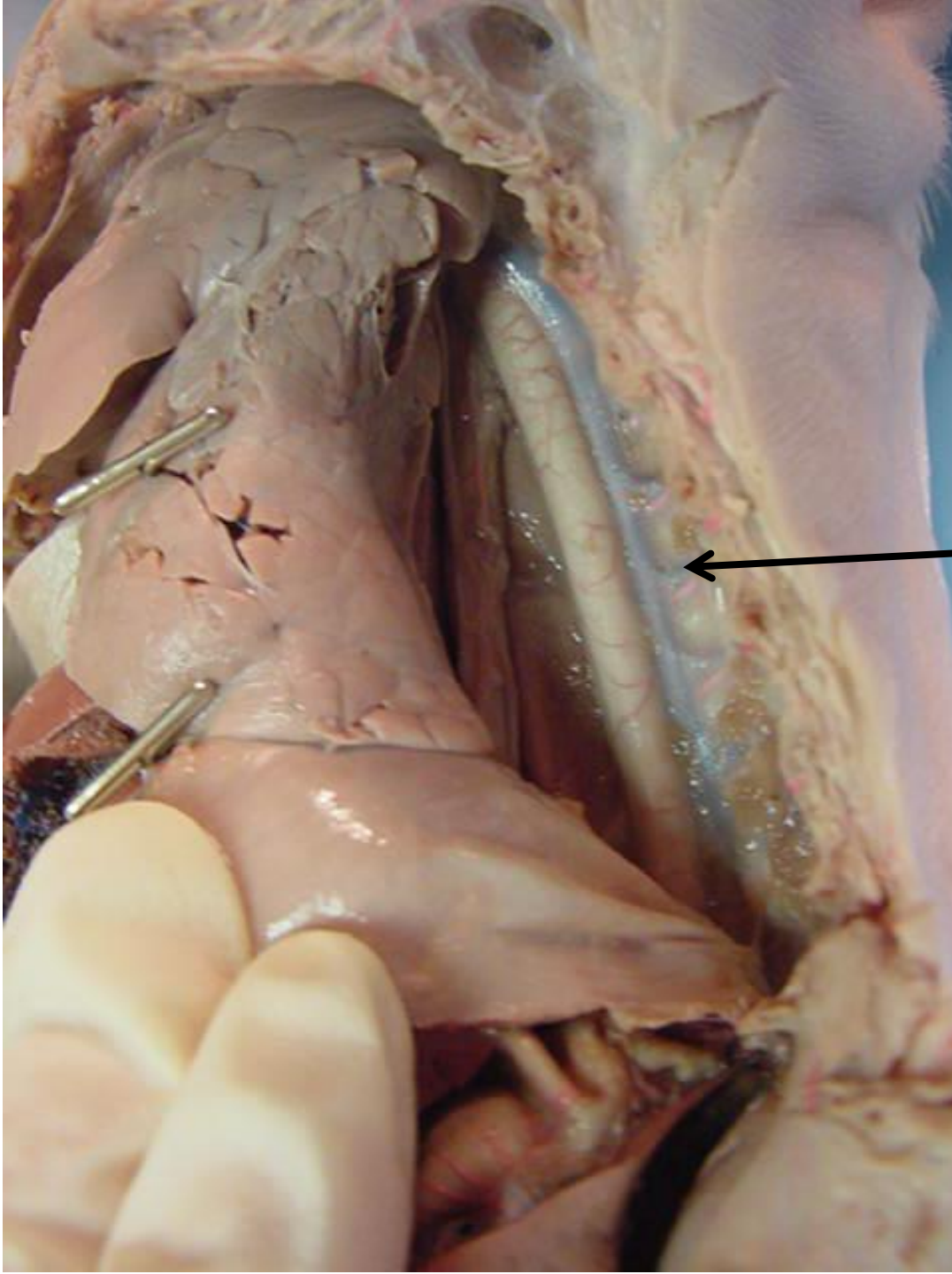




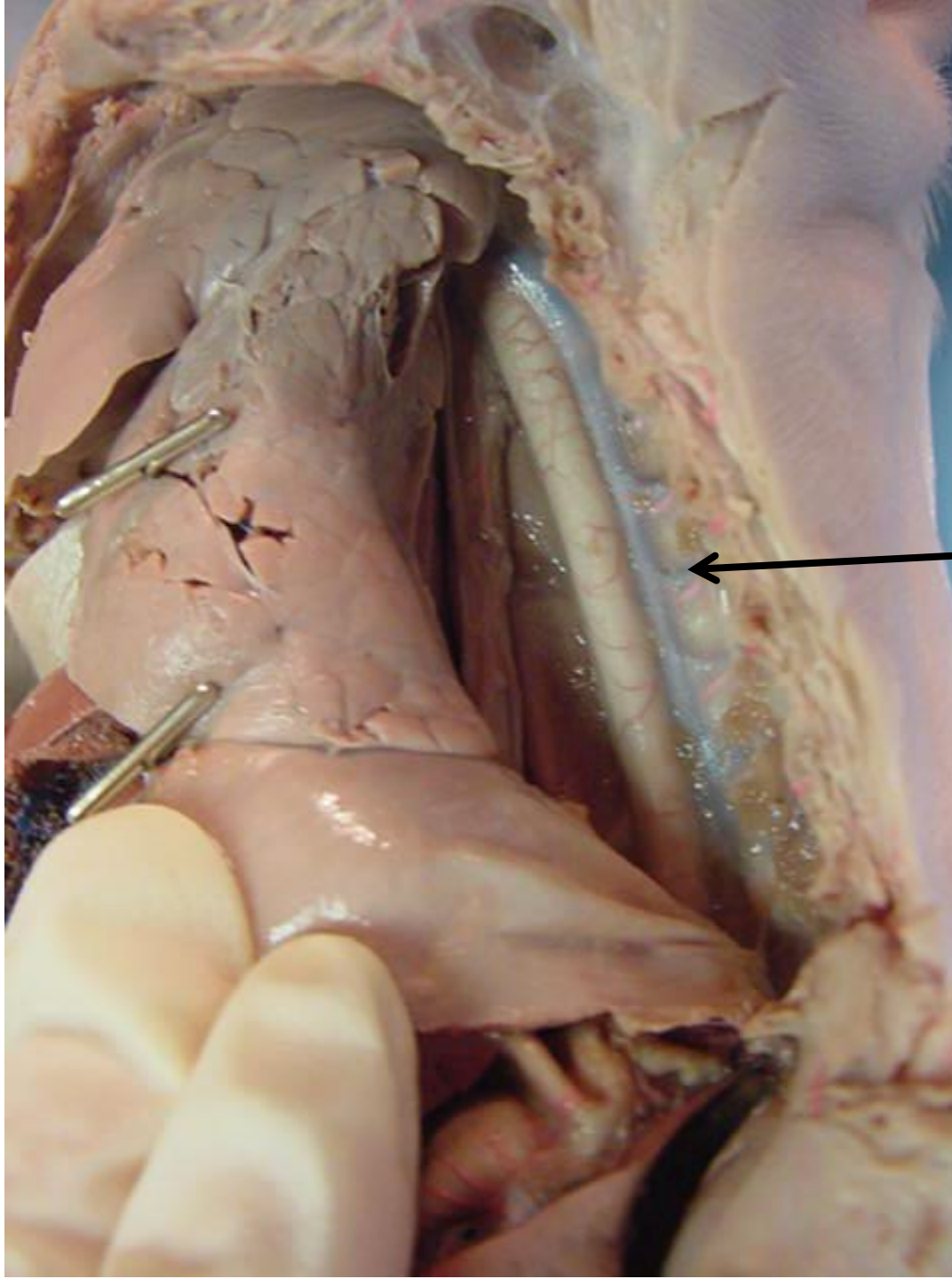
*scroll to the
next slide to
check your
answer



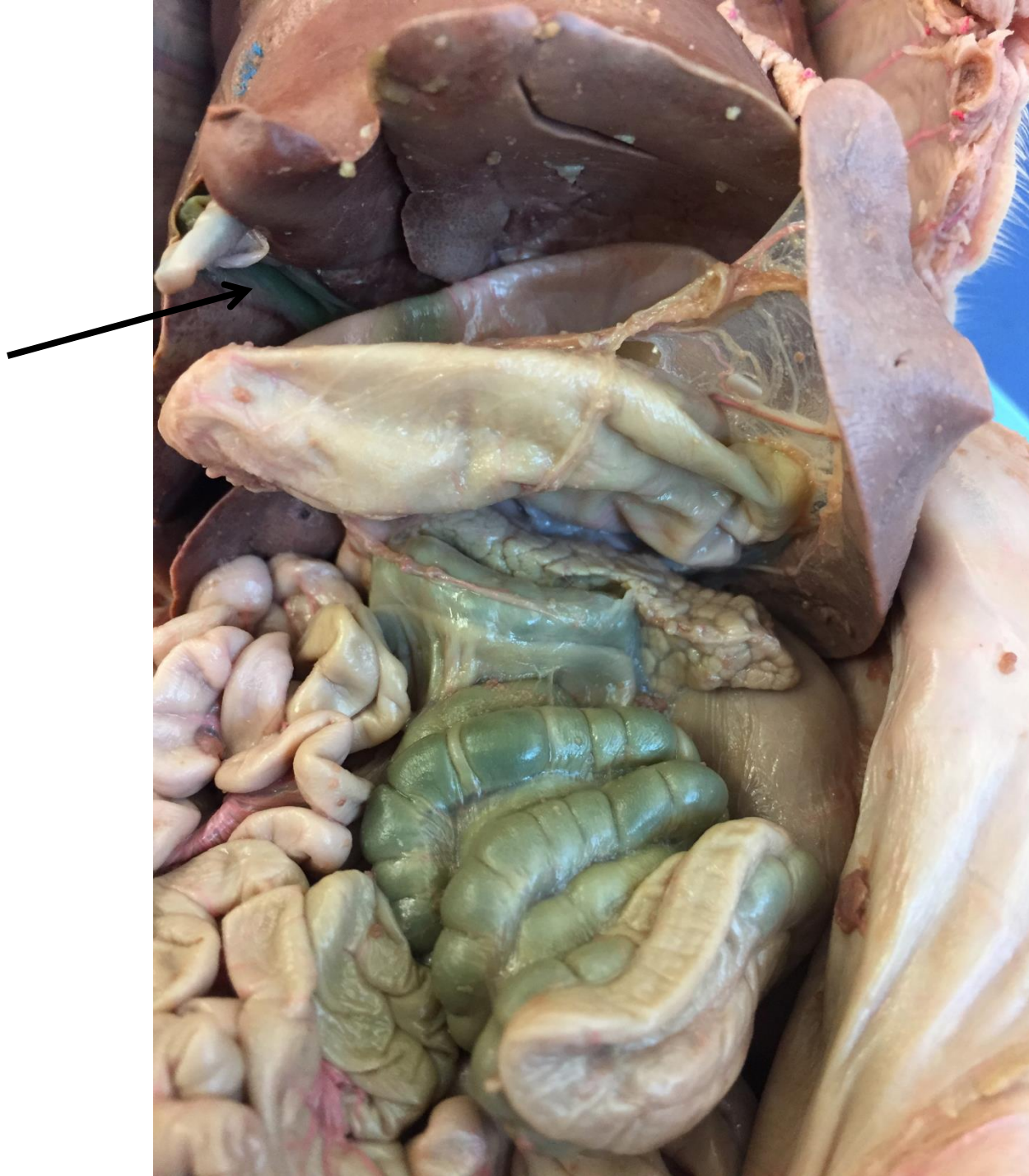
← diaphragm



*scroll to the next slide
to check your answer

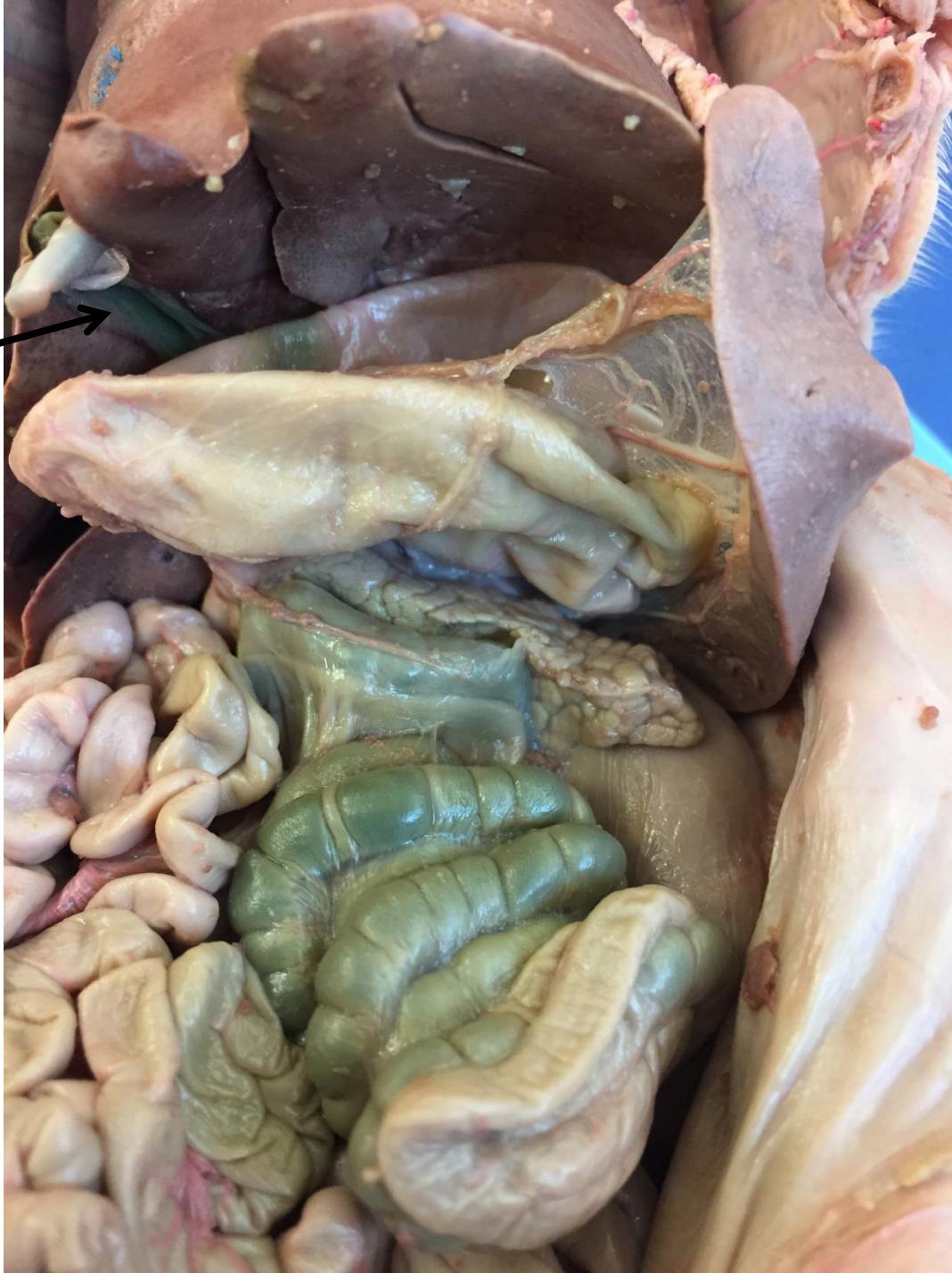

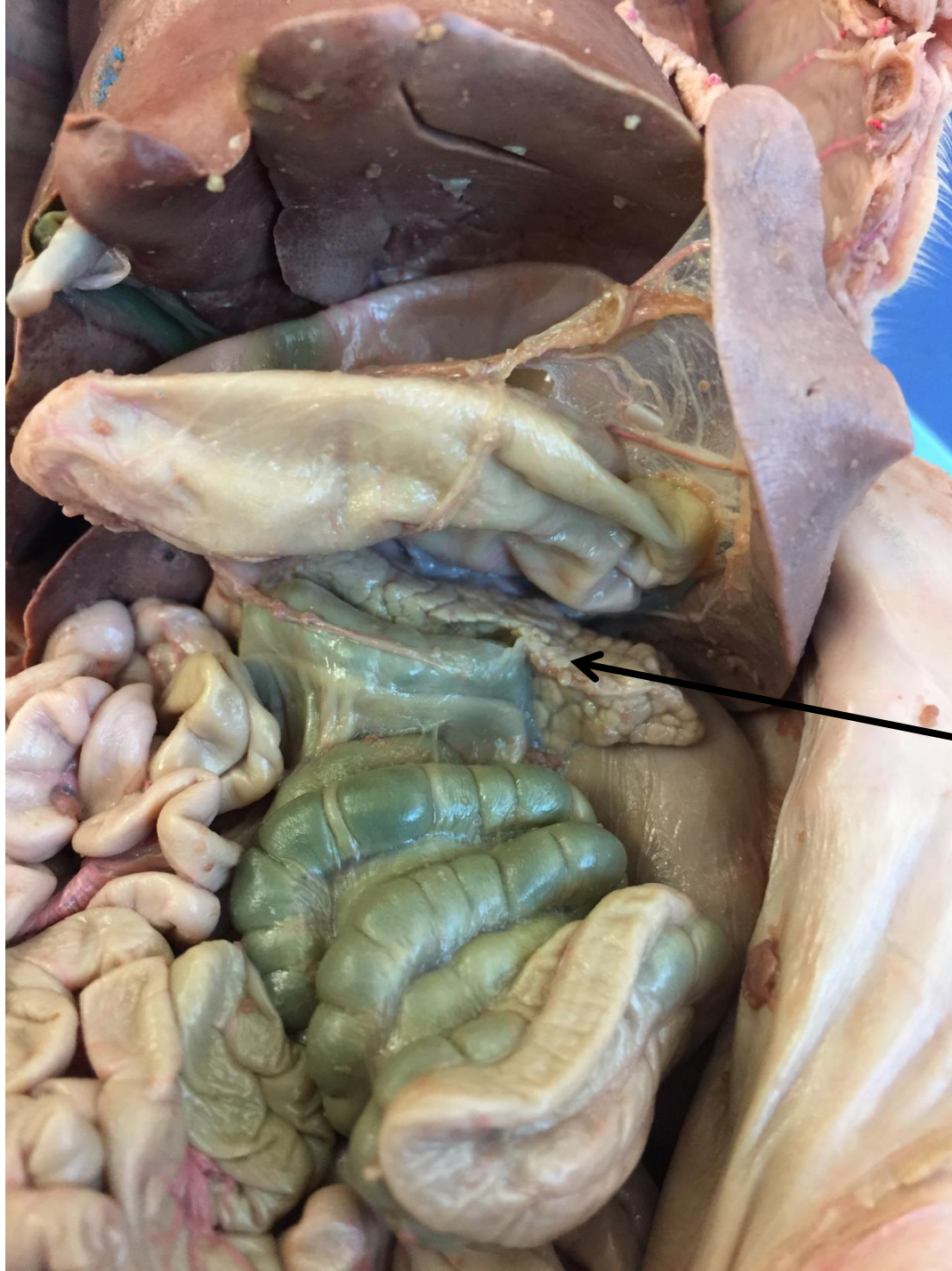intercostal vein



*scroll to the next slide to check your answer

gall bladder

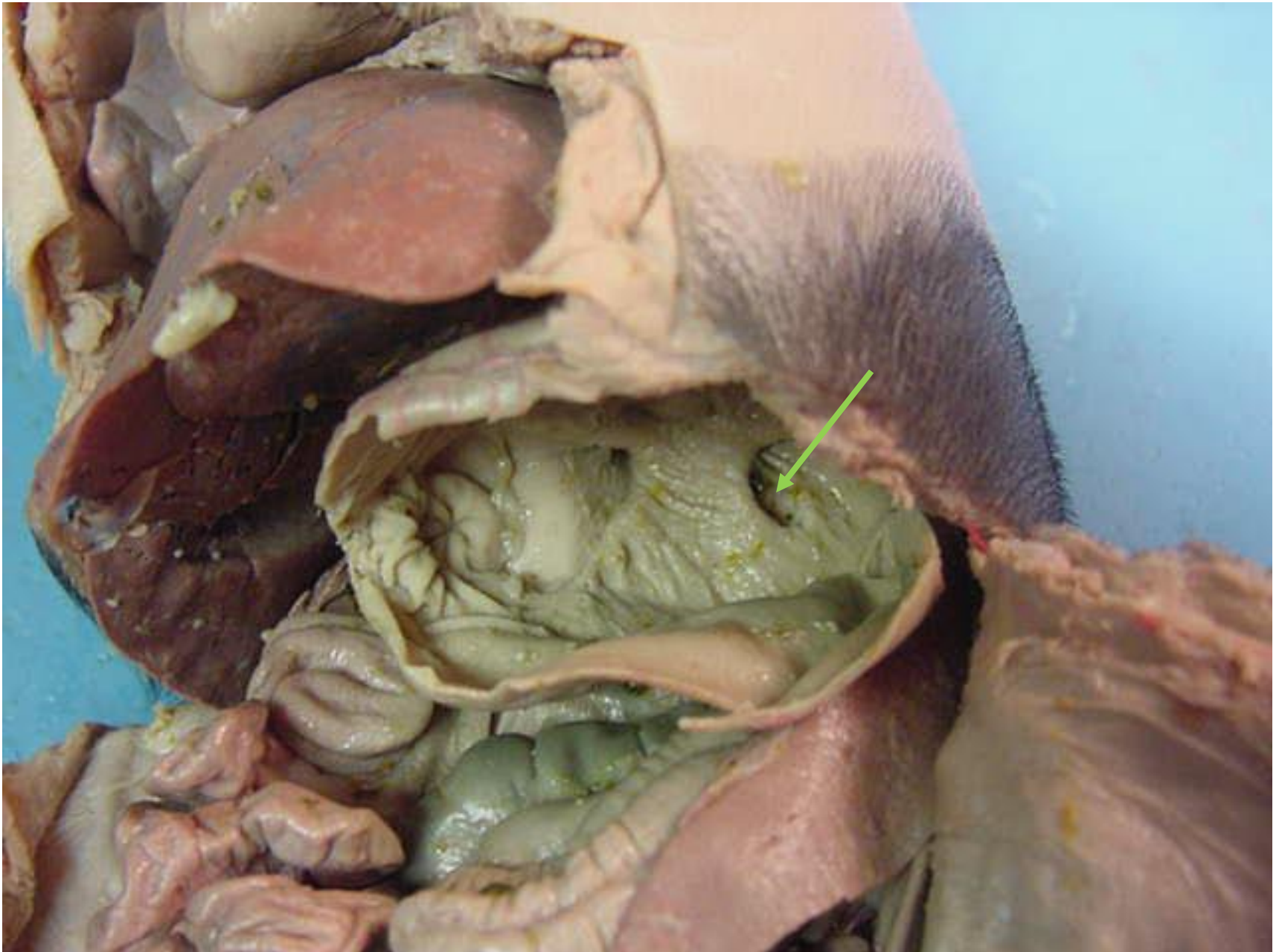



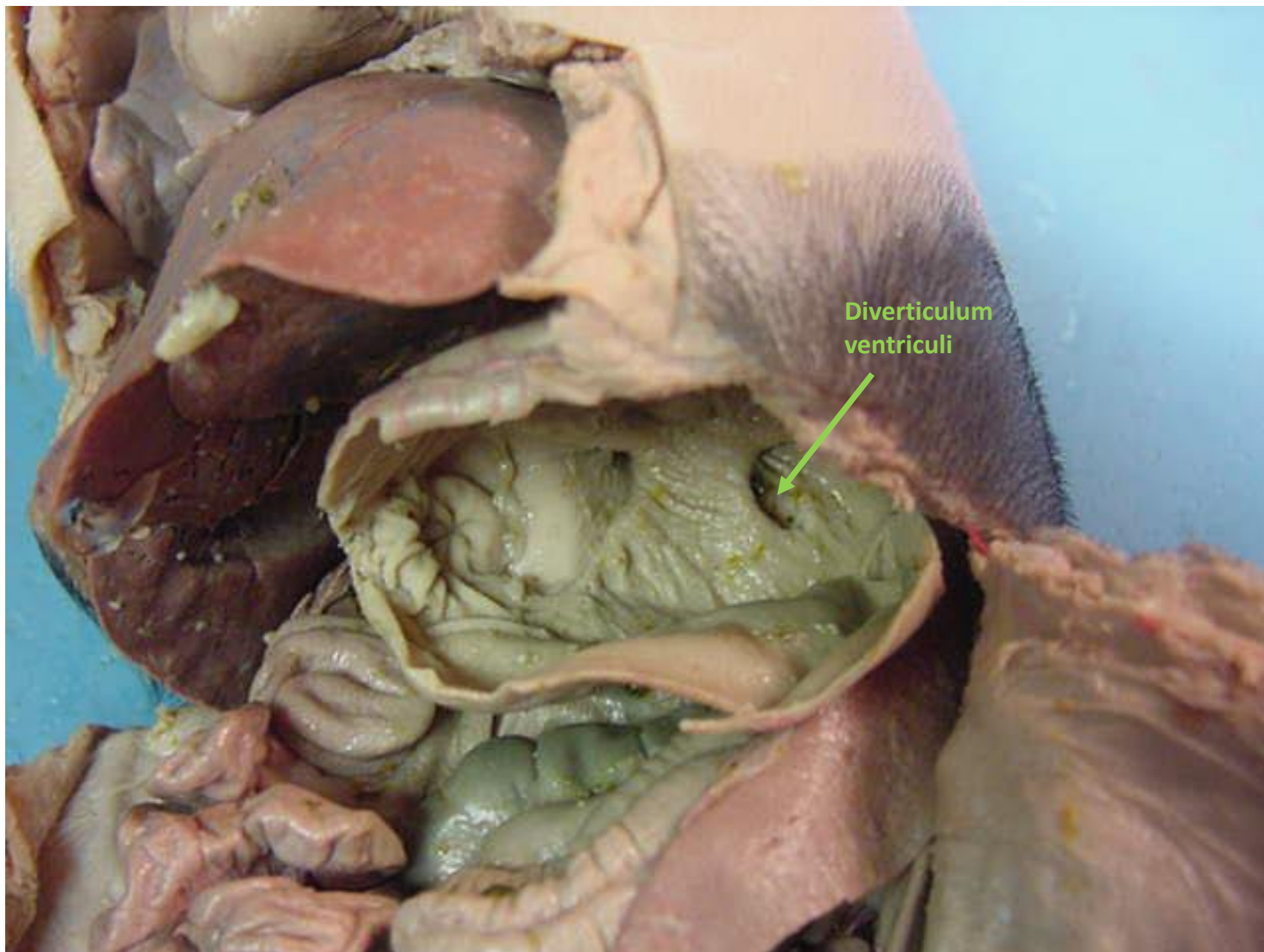
*scroll to the next slide to check your answer



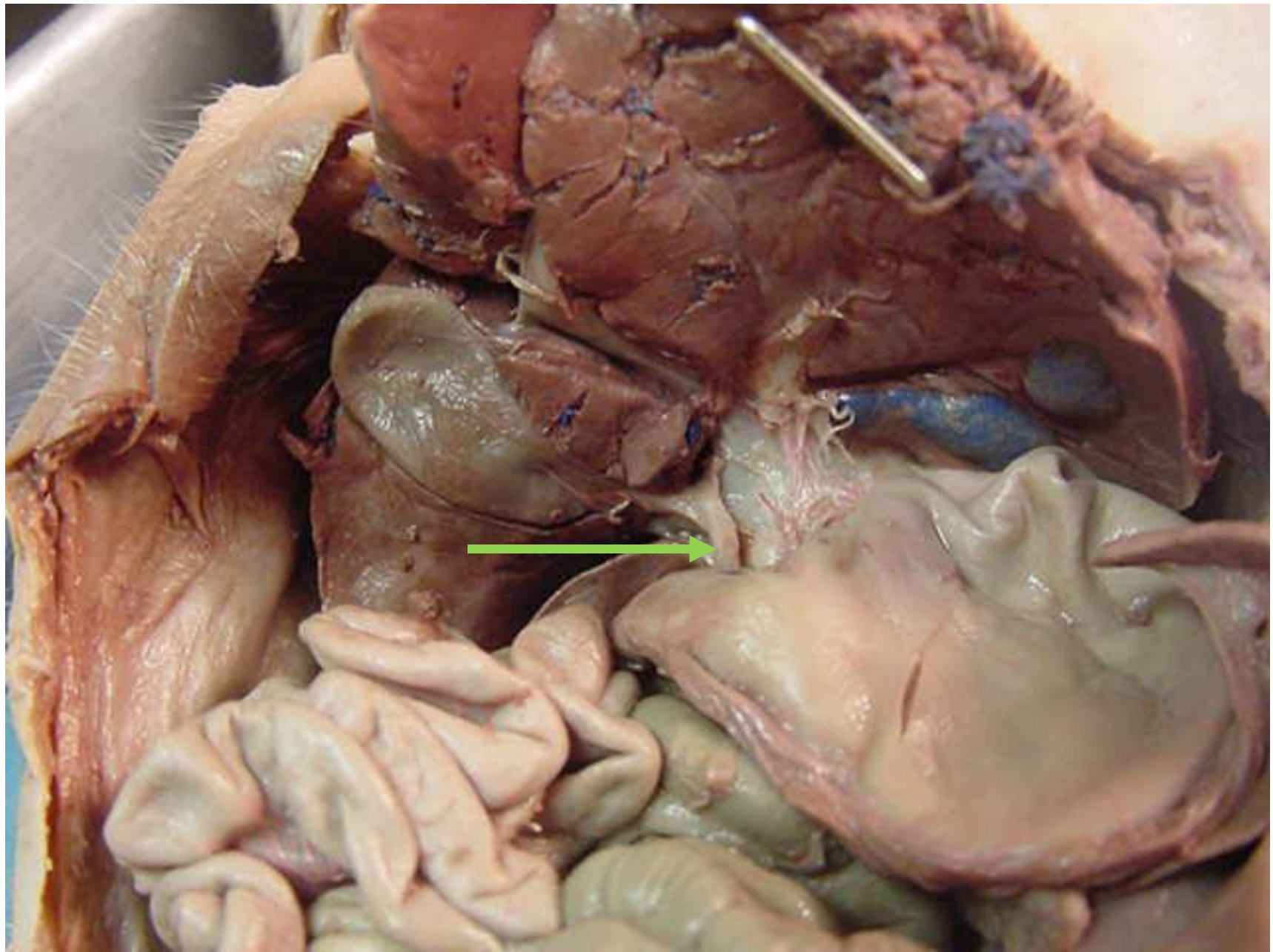
pancreas



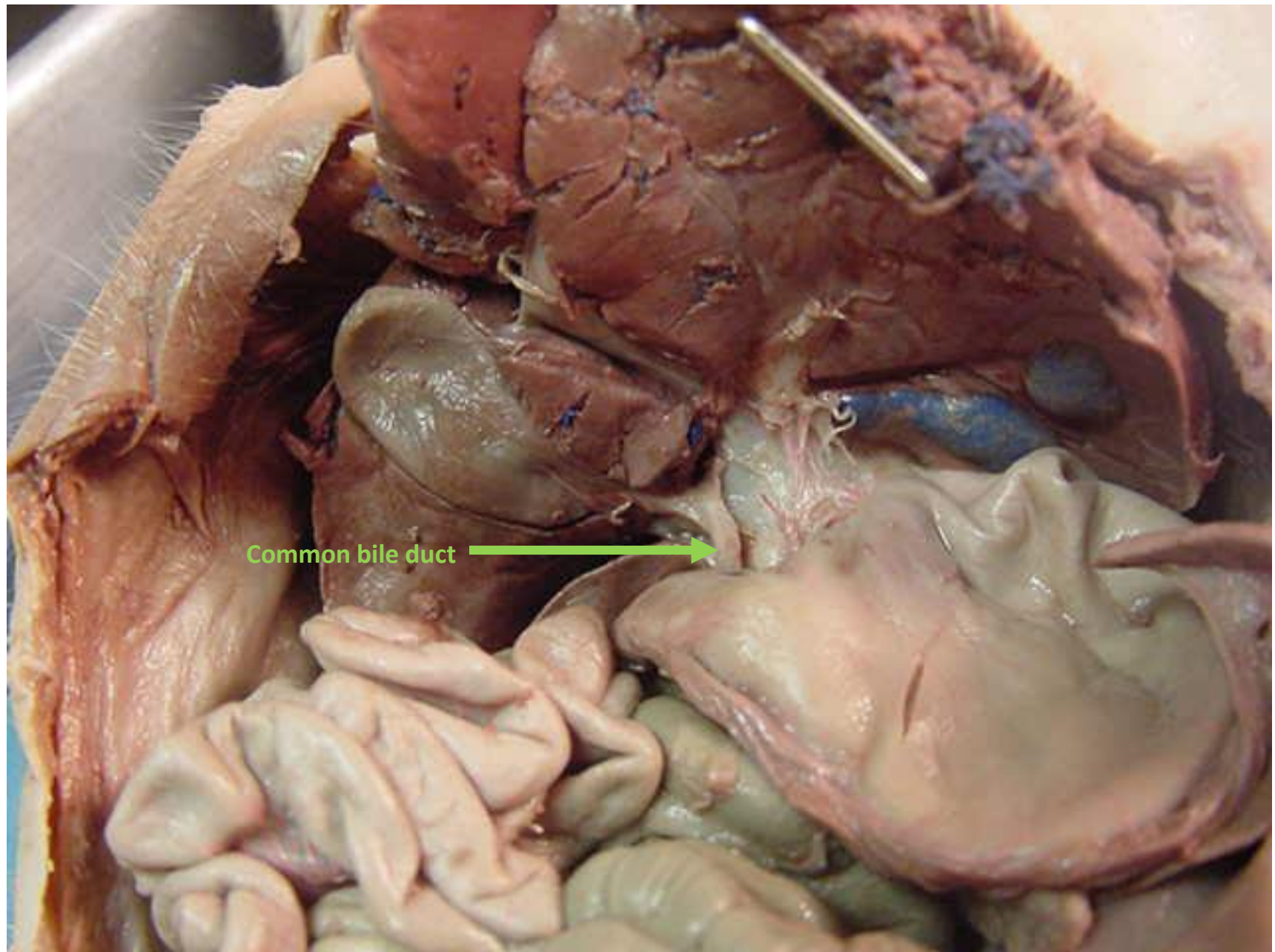
*scroll to the next slide to check your answer

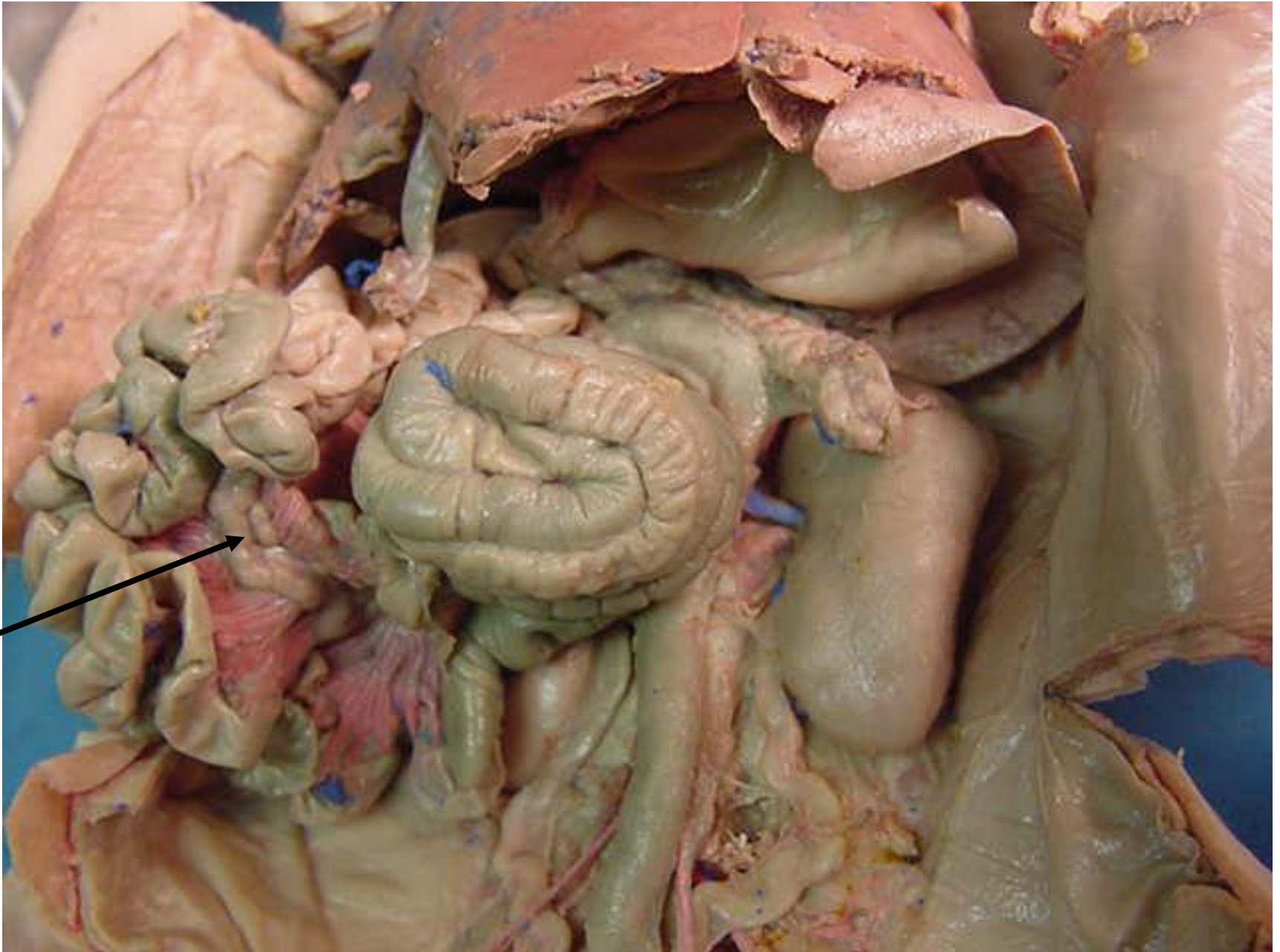

Diverticulum
ventriculi

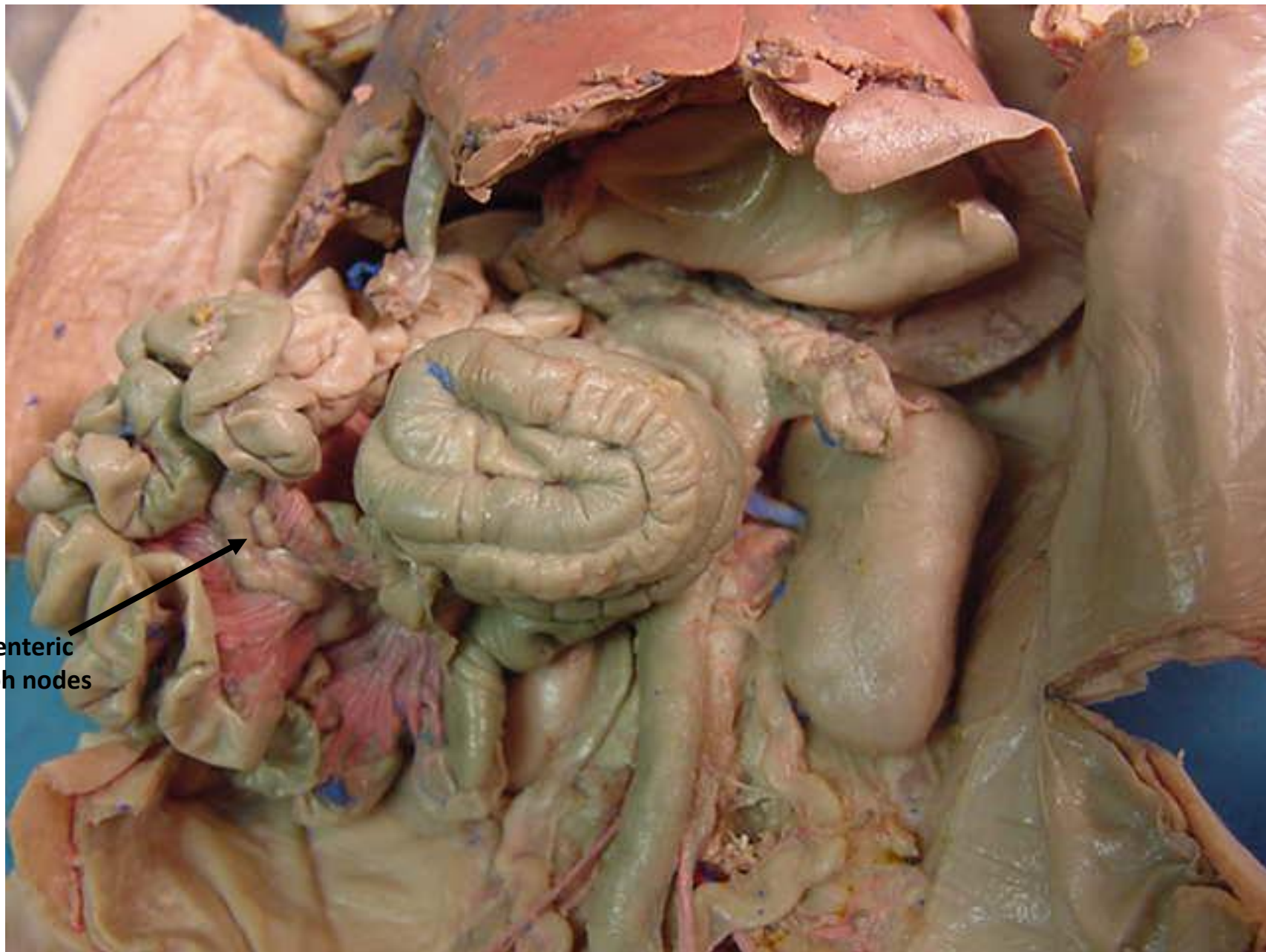


*scroll to the next slide to check your answer

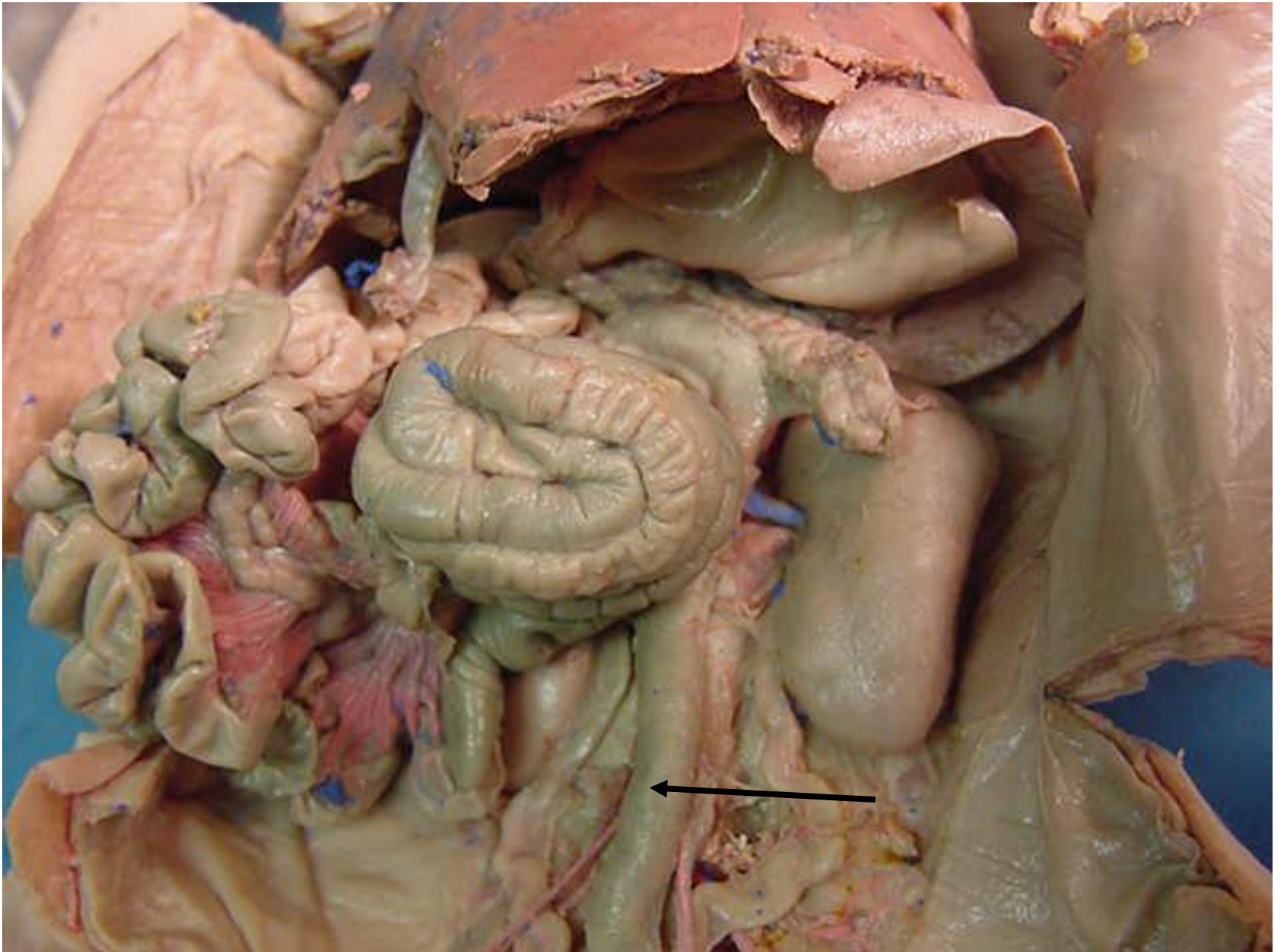




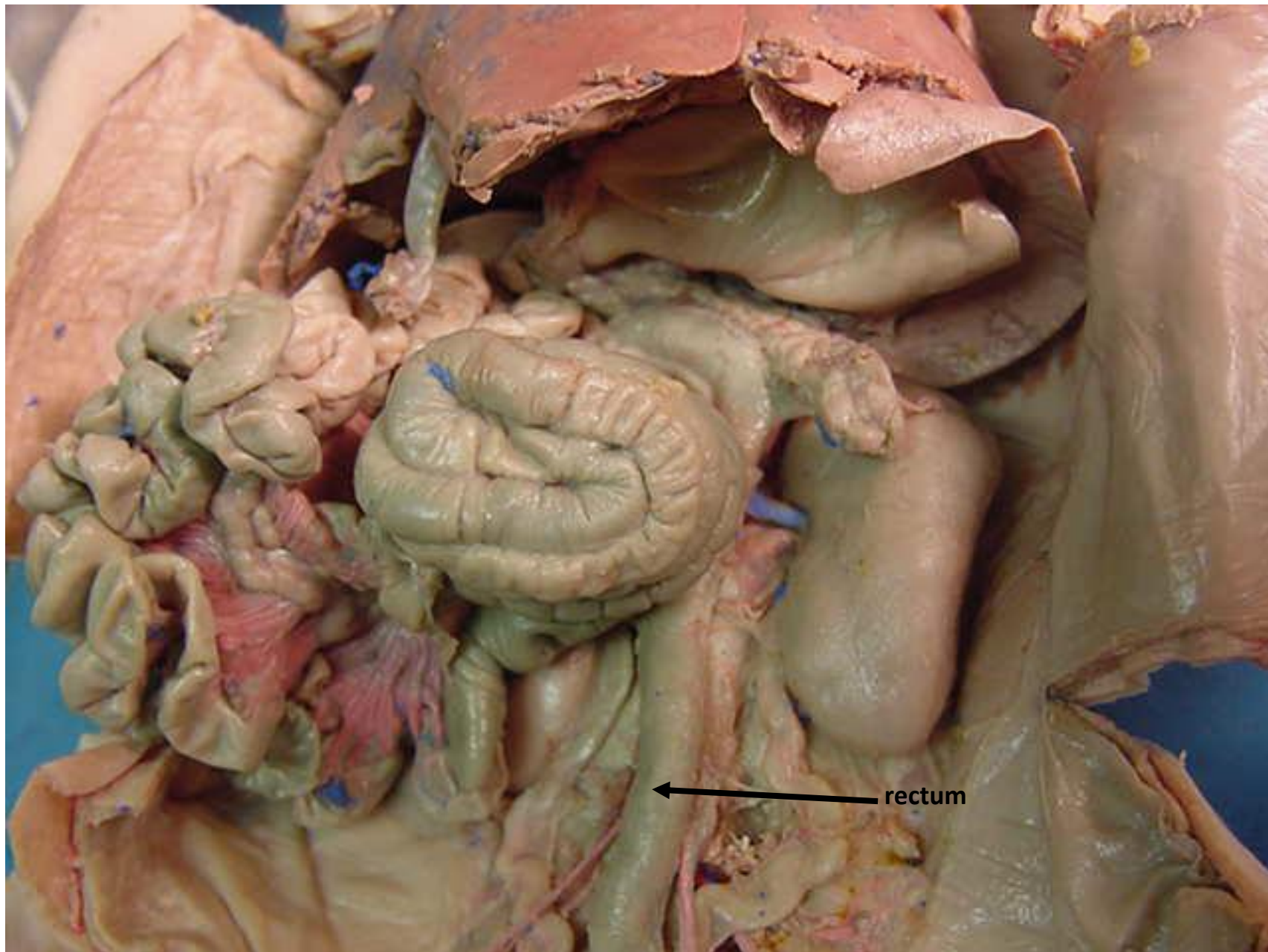
*scroll to the next slide to check your answer



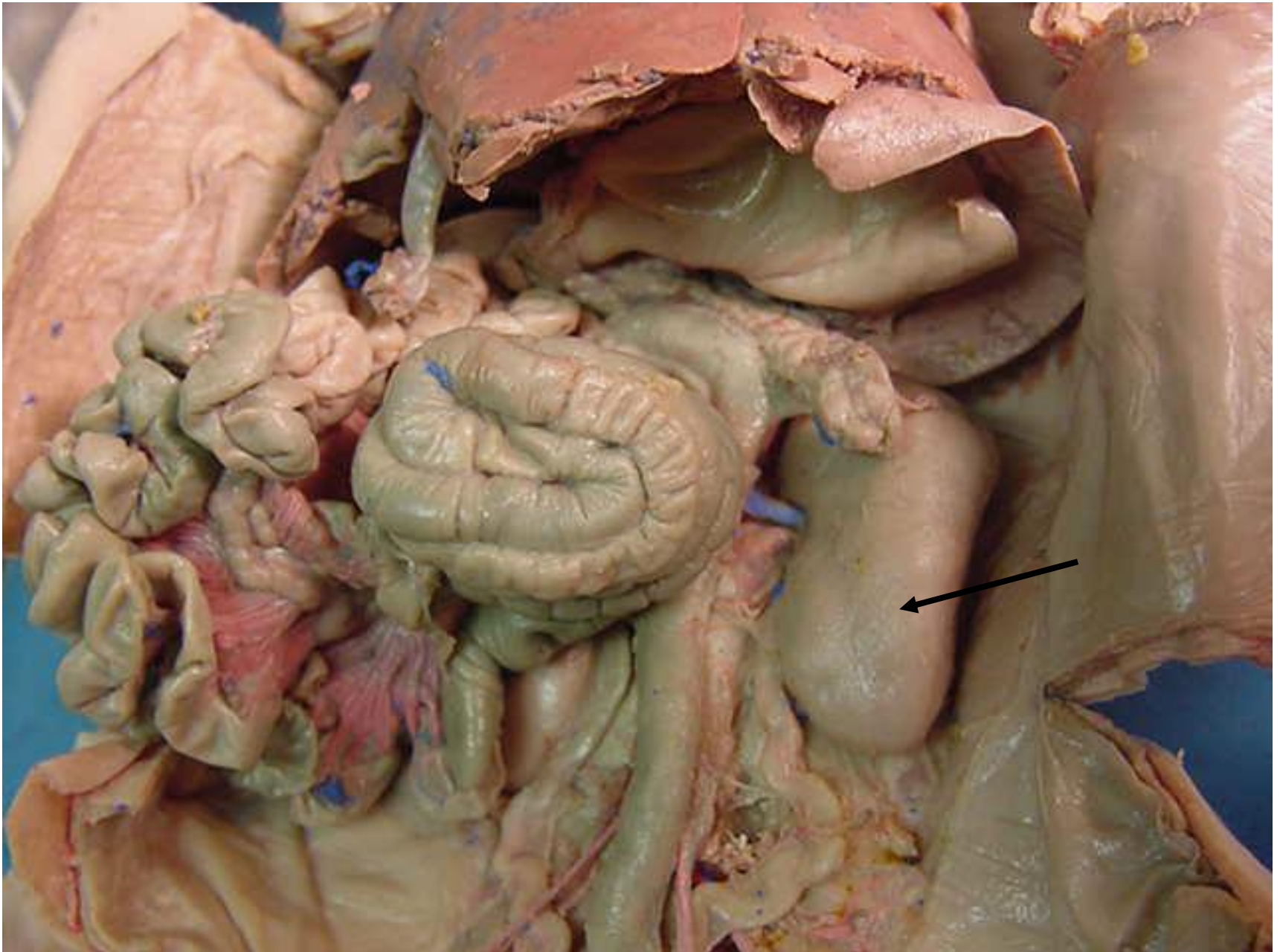
Mesenteric
lymph nodes



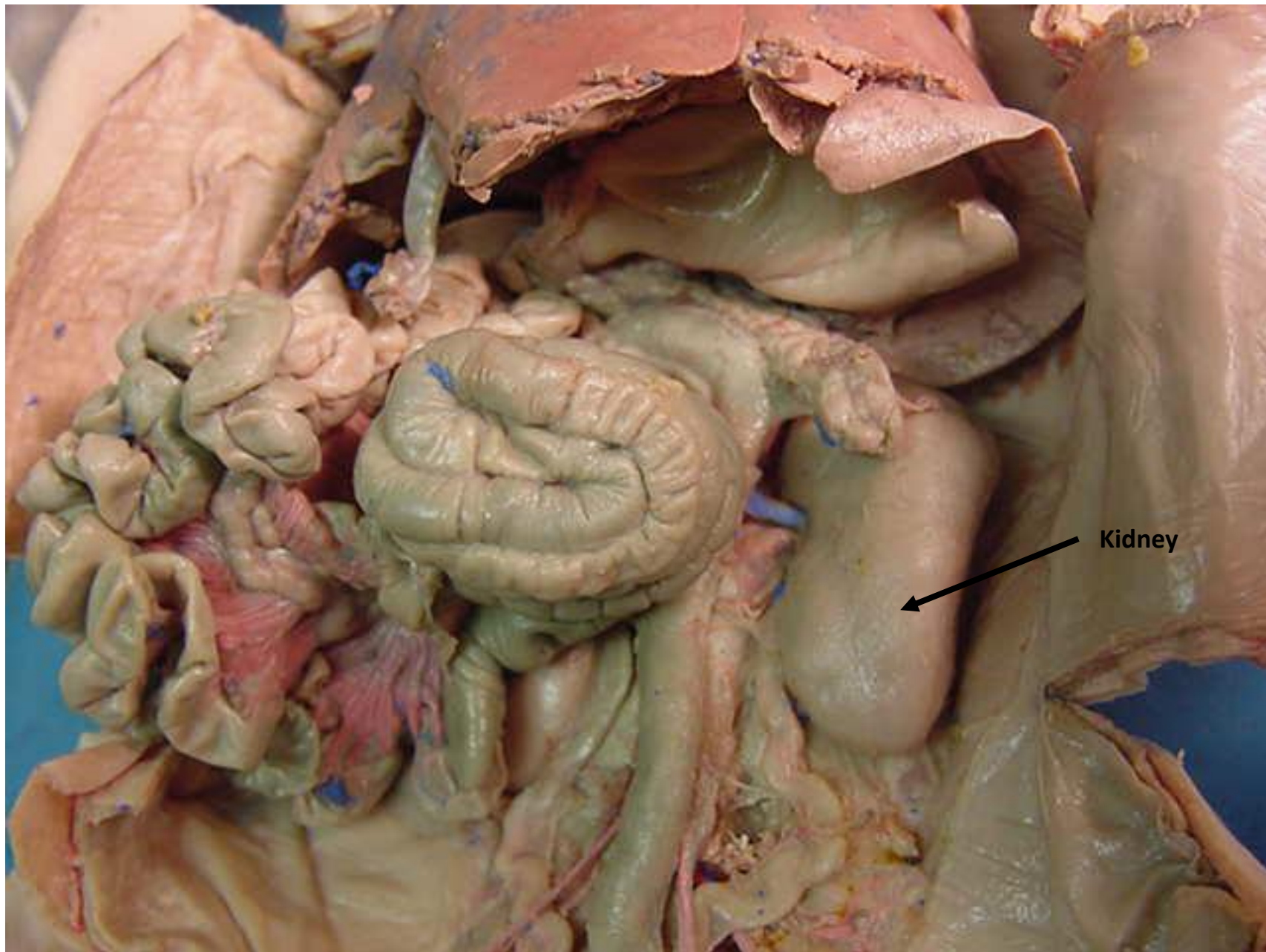
*scroll to the next slide to check your answer



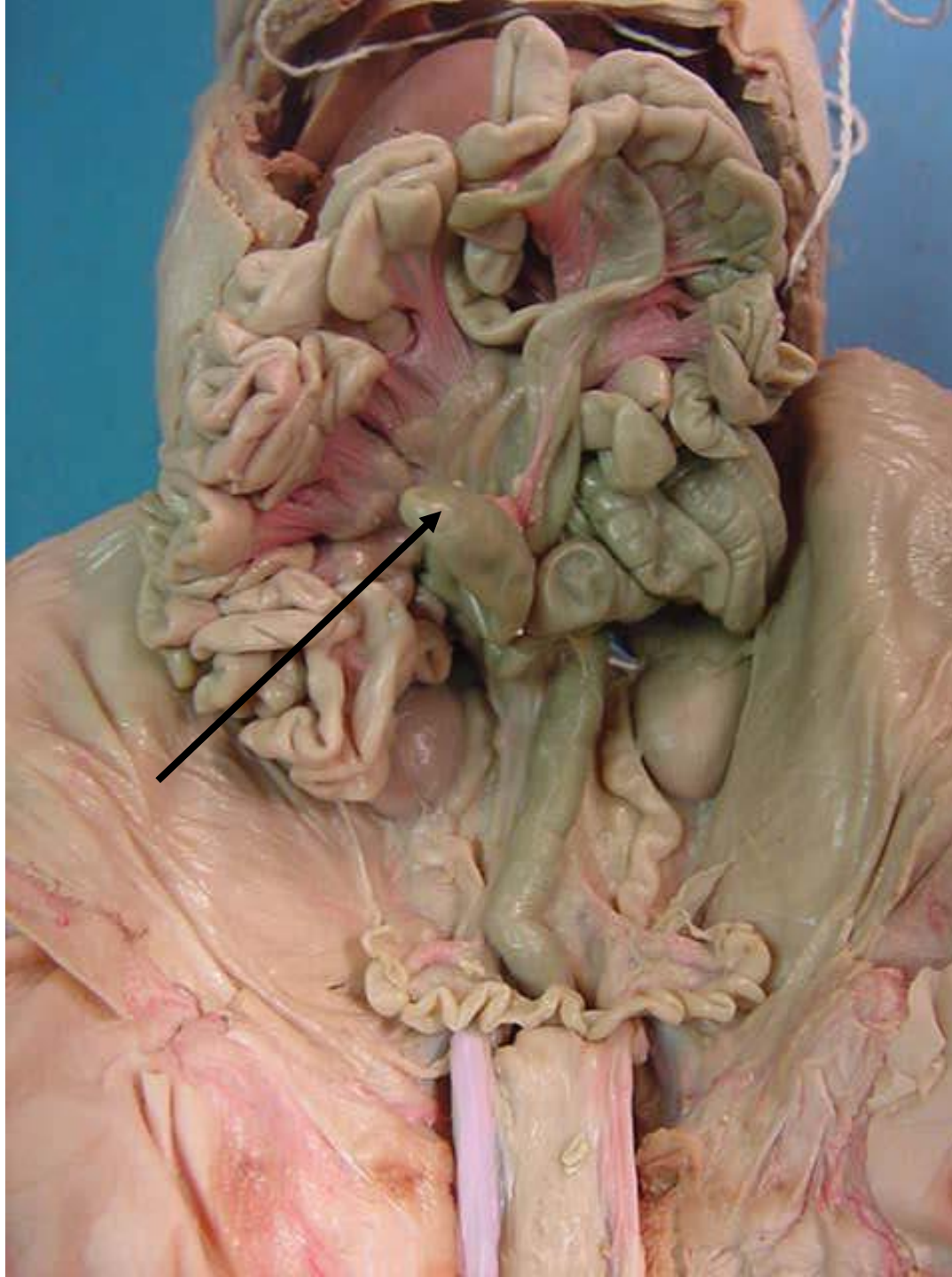
rectum



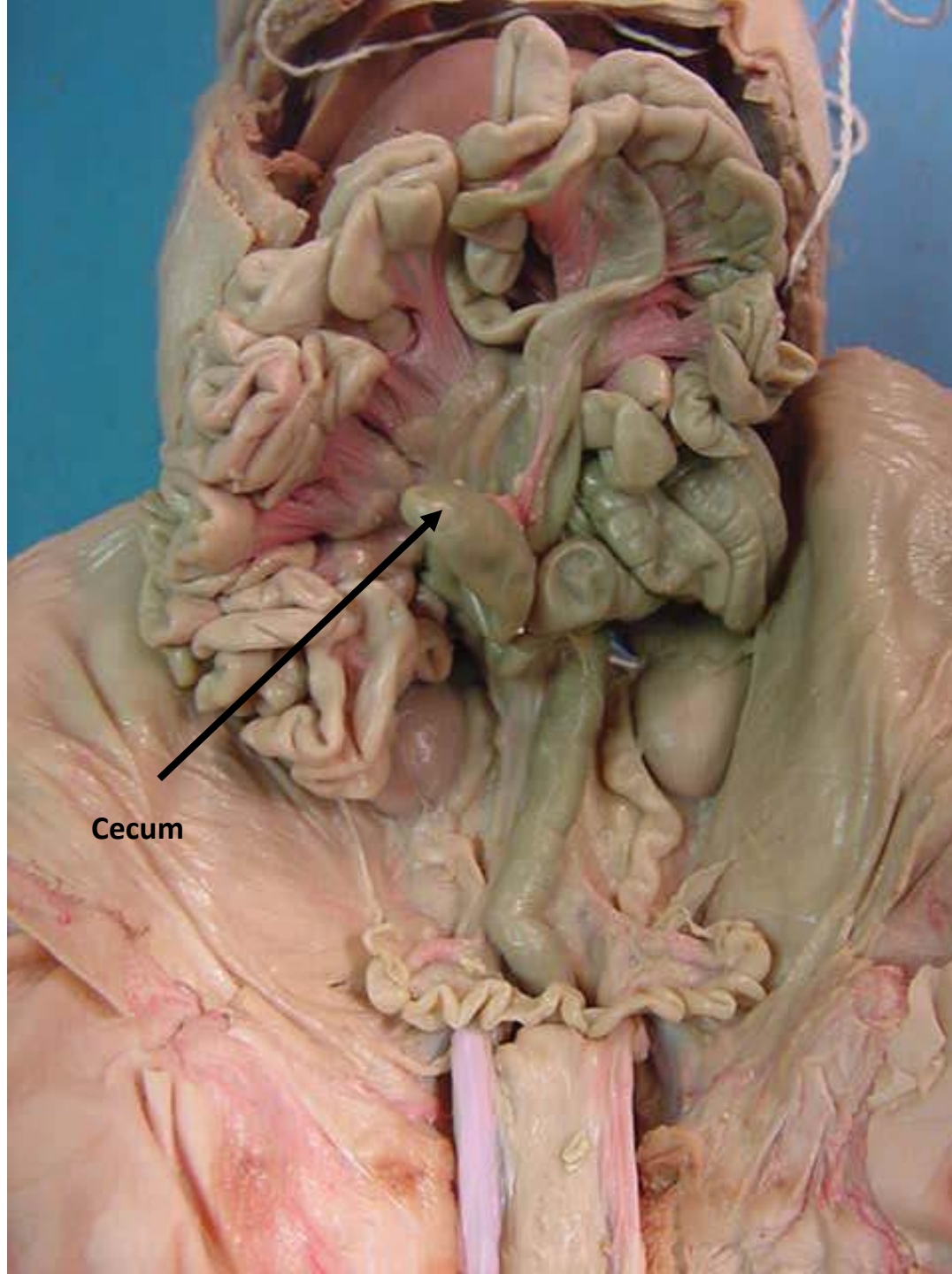
*scroll to the next slide to check your answer



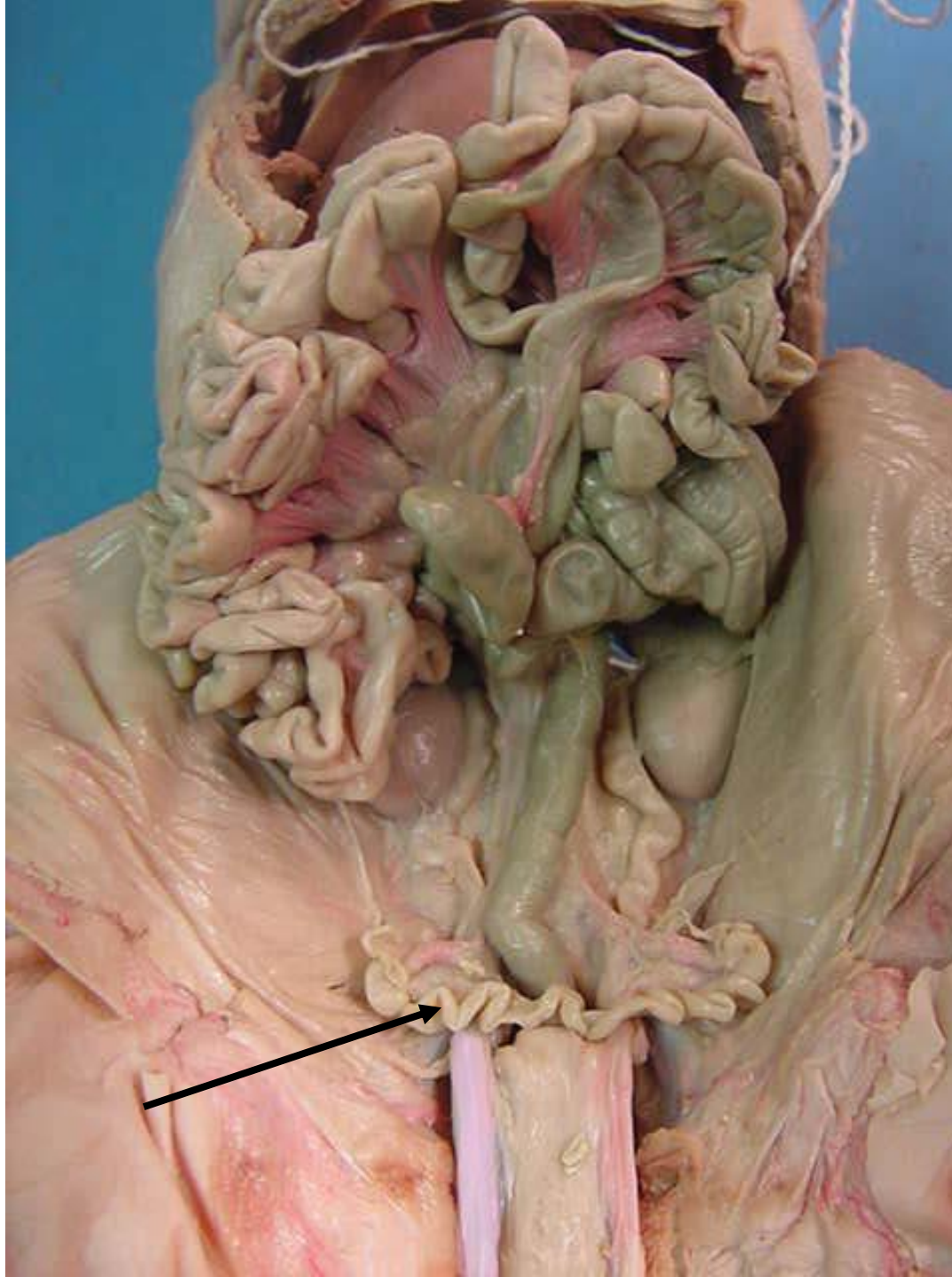
Kidney



*scroll to the next slide to check your answer

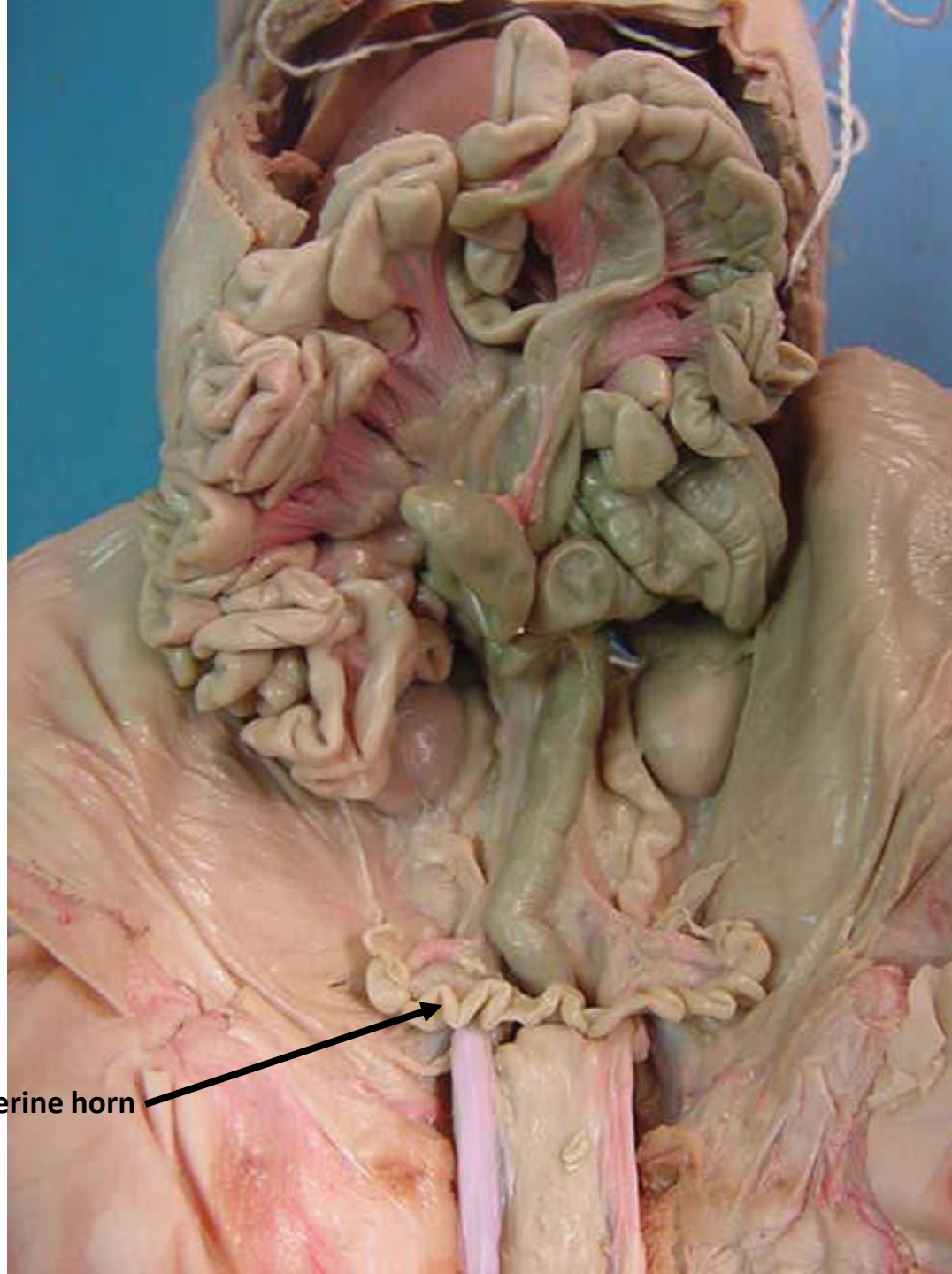


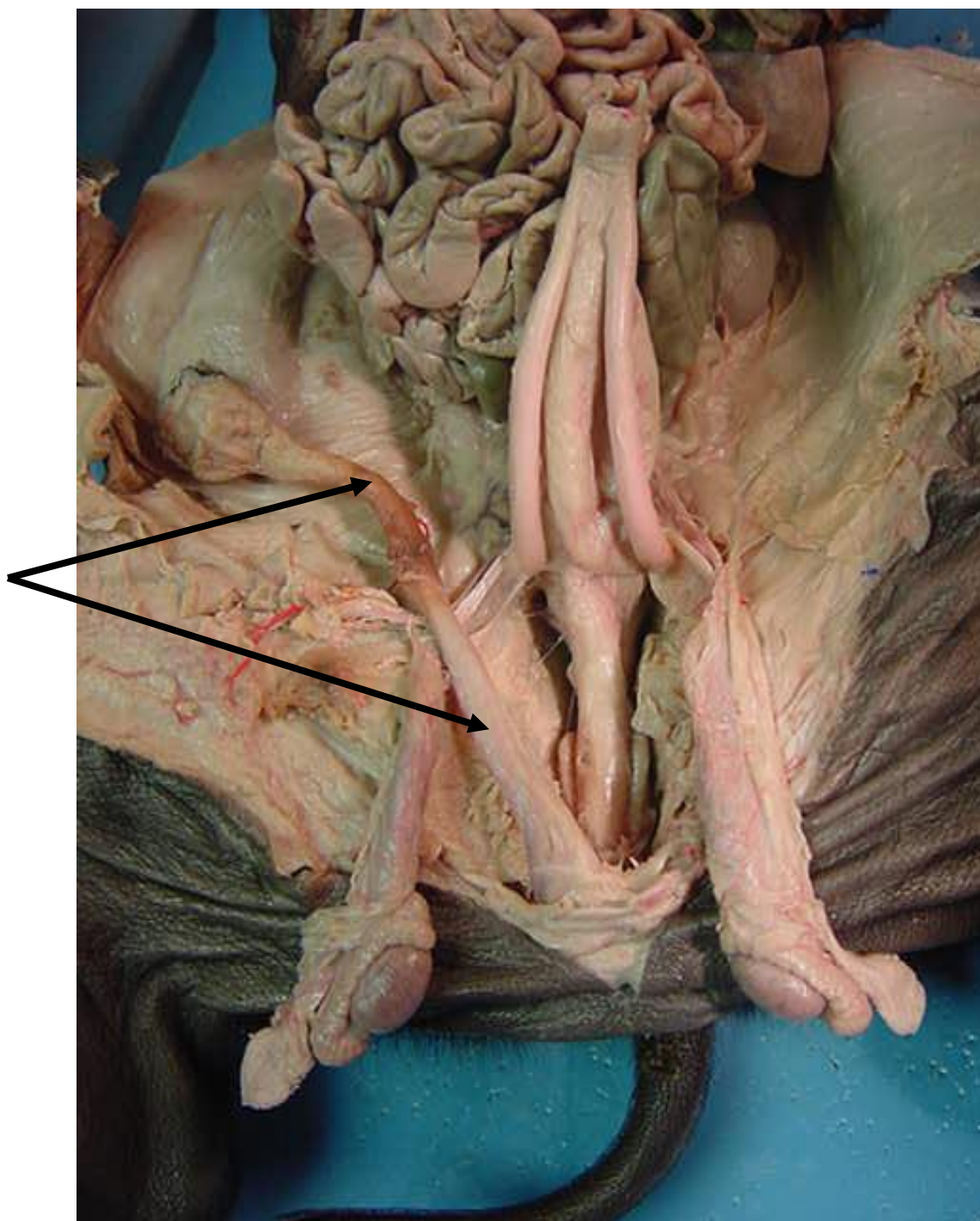
Cecum



*scroll to the next
slide to check your
answer

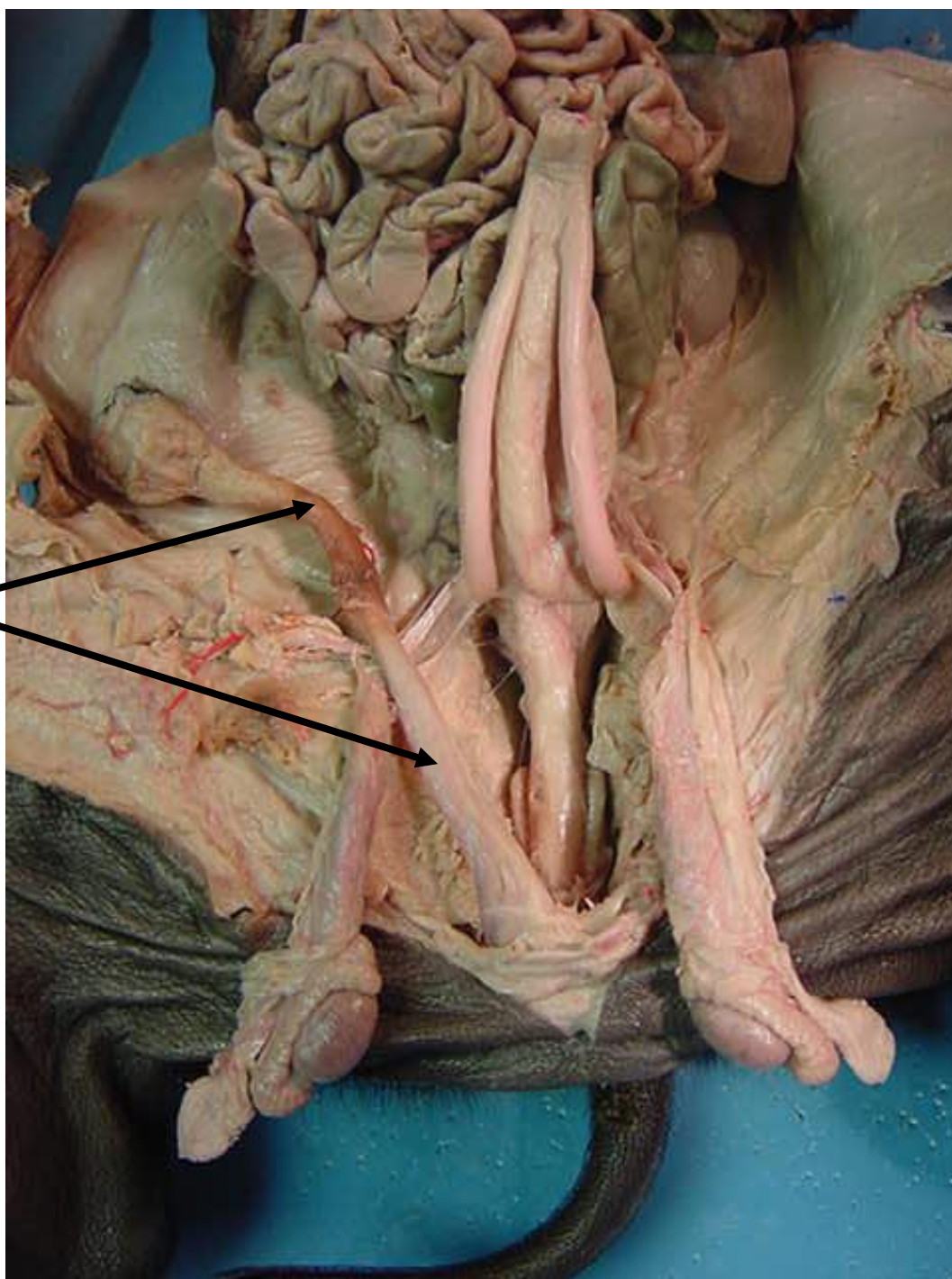
Uterine horn

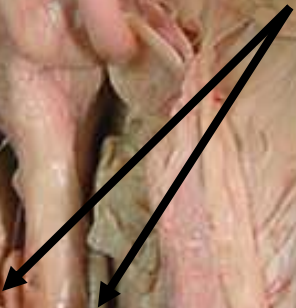




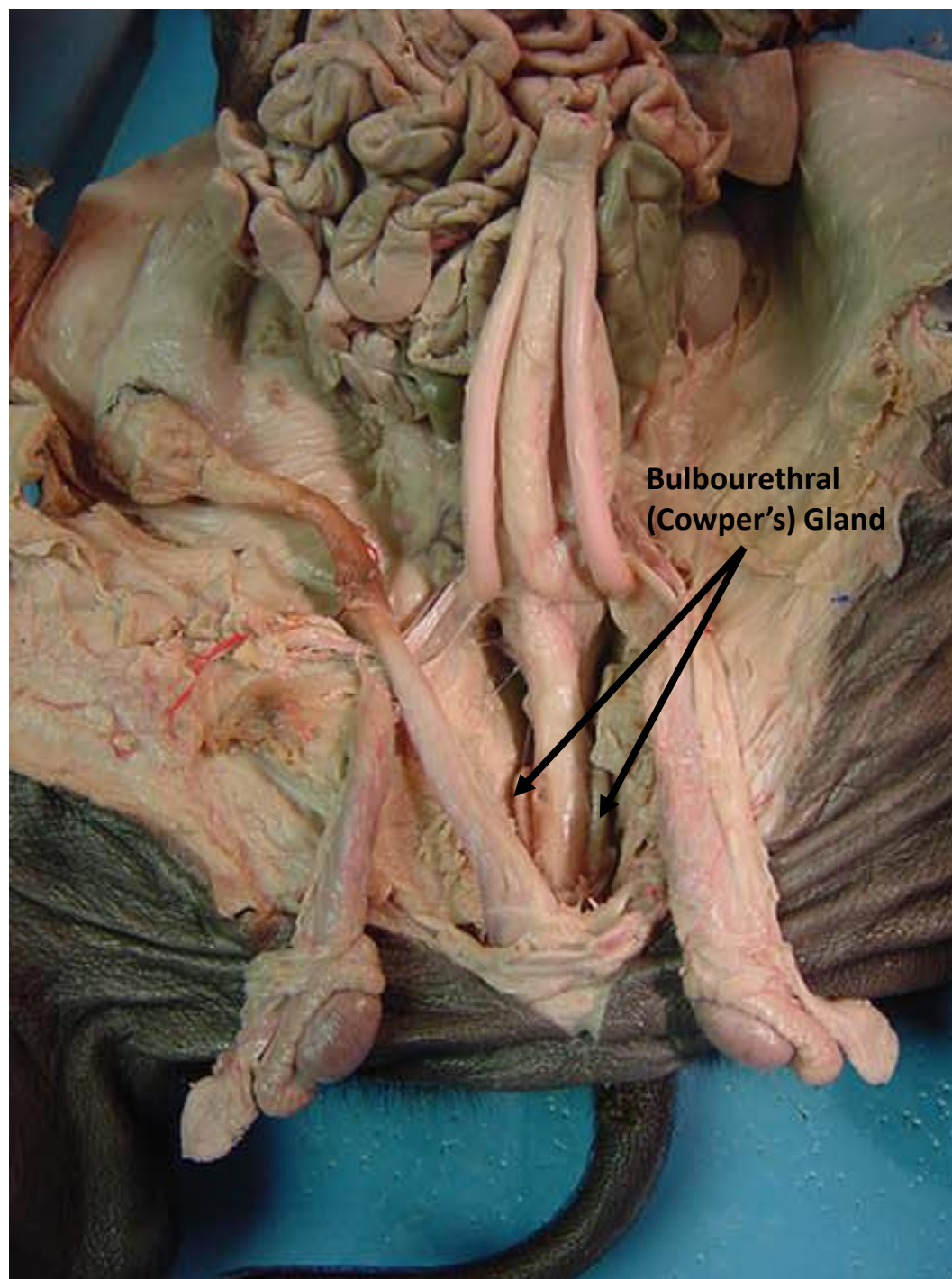
*scroll to the next slide to check your answer

Penis

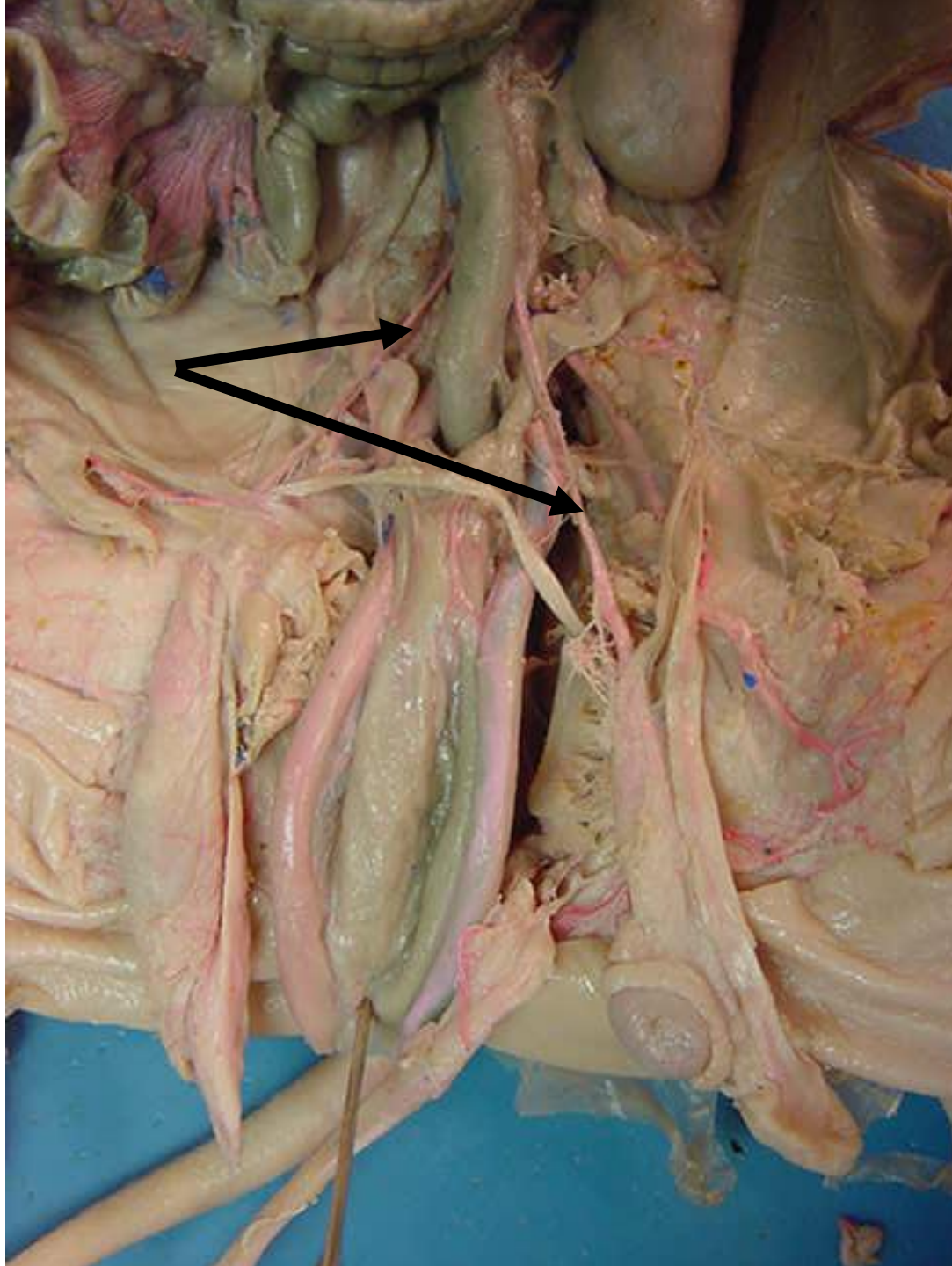




*scroll to the next slide to check your answer

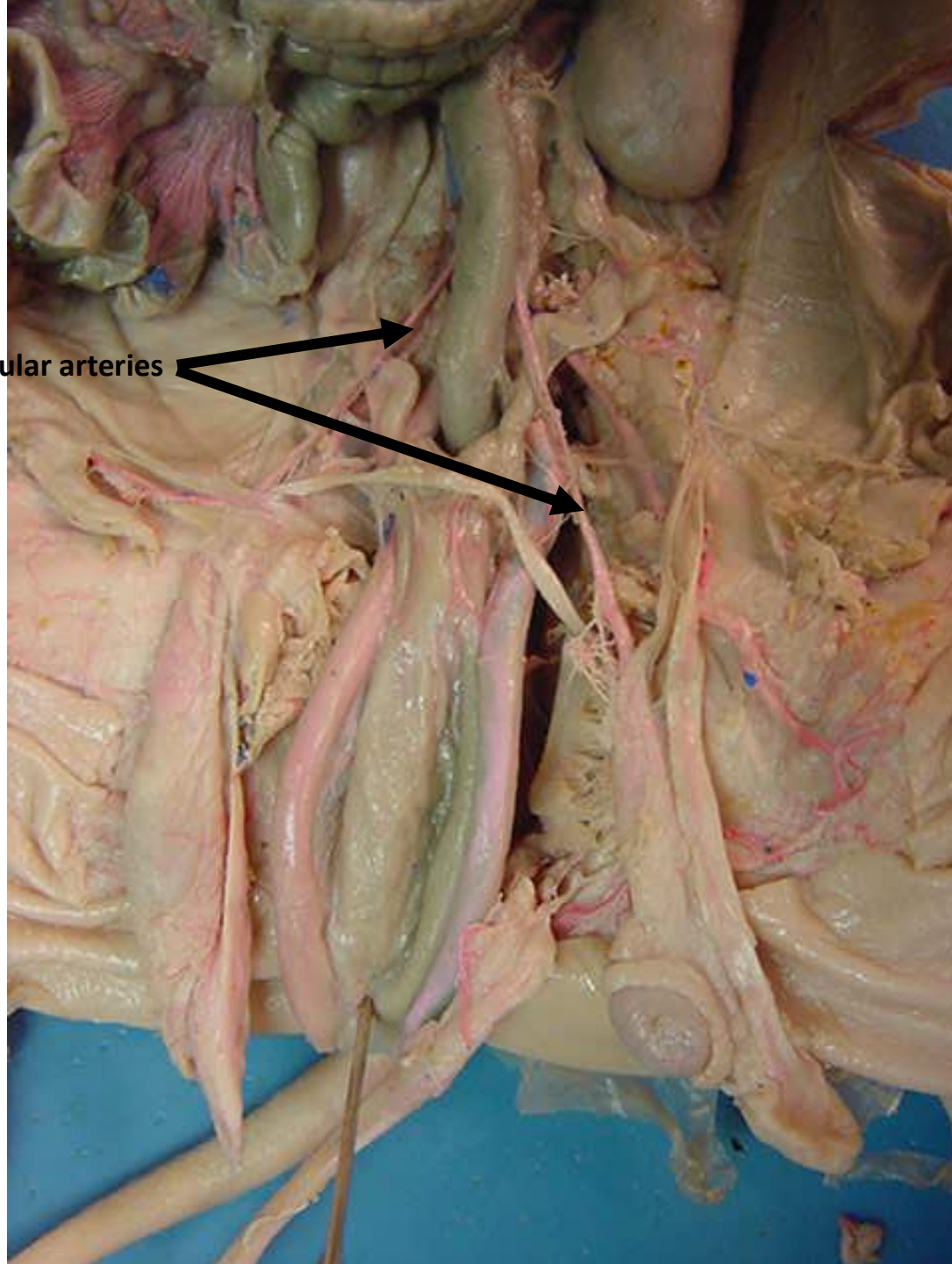


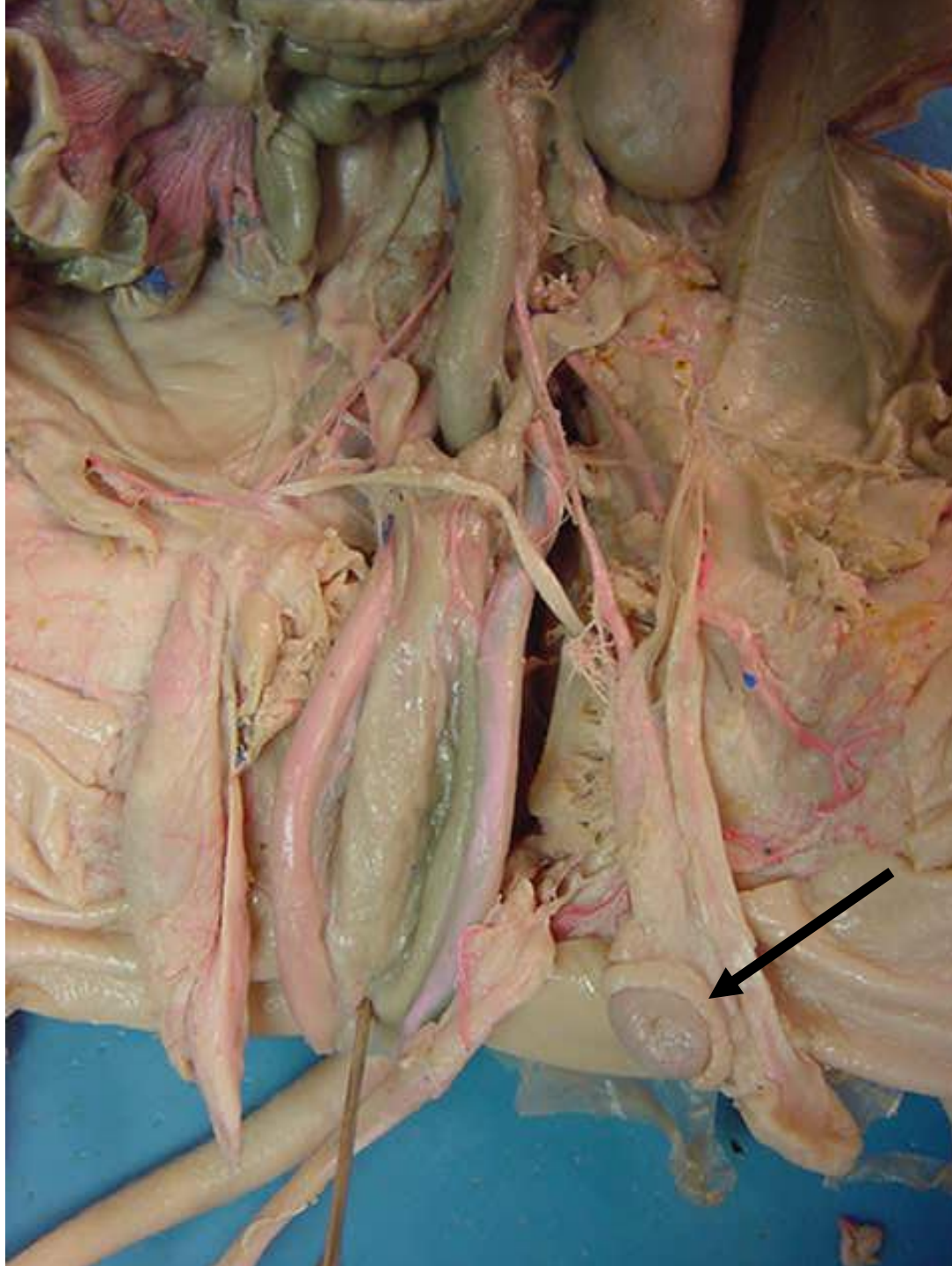
**Bulbourethral
(Cowper's) Gland**



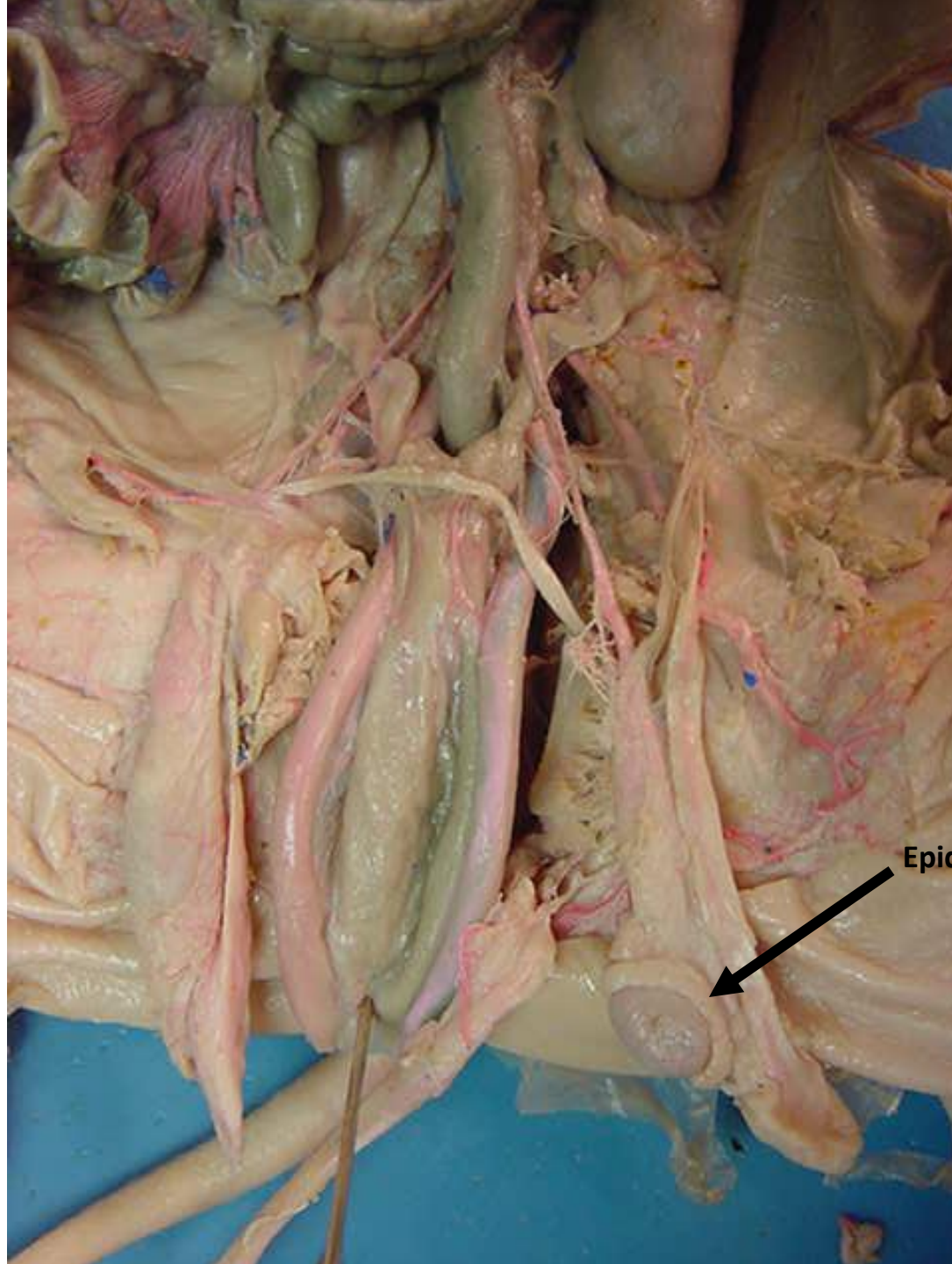
*scroll to the next slide to check your answer

Testicular arteries

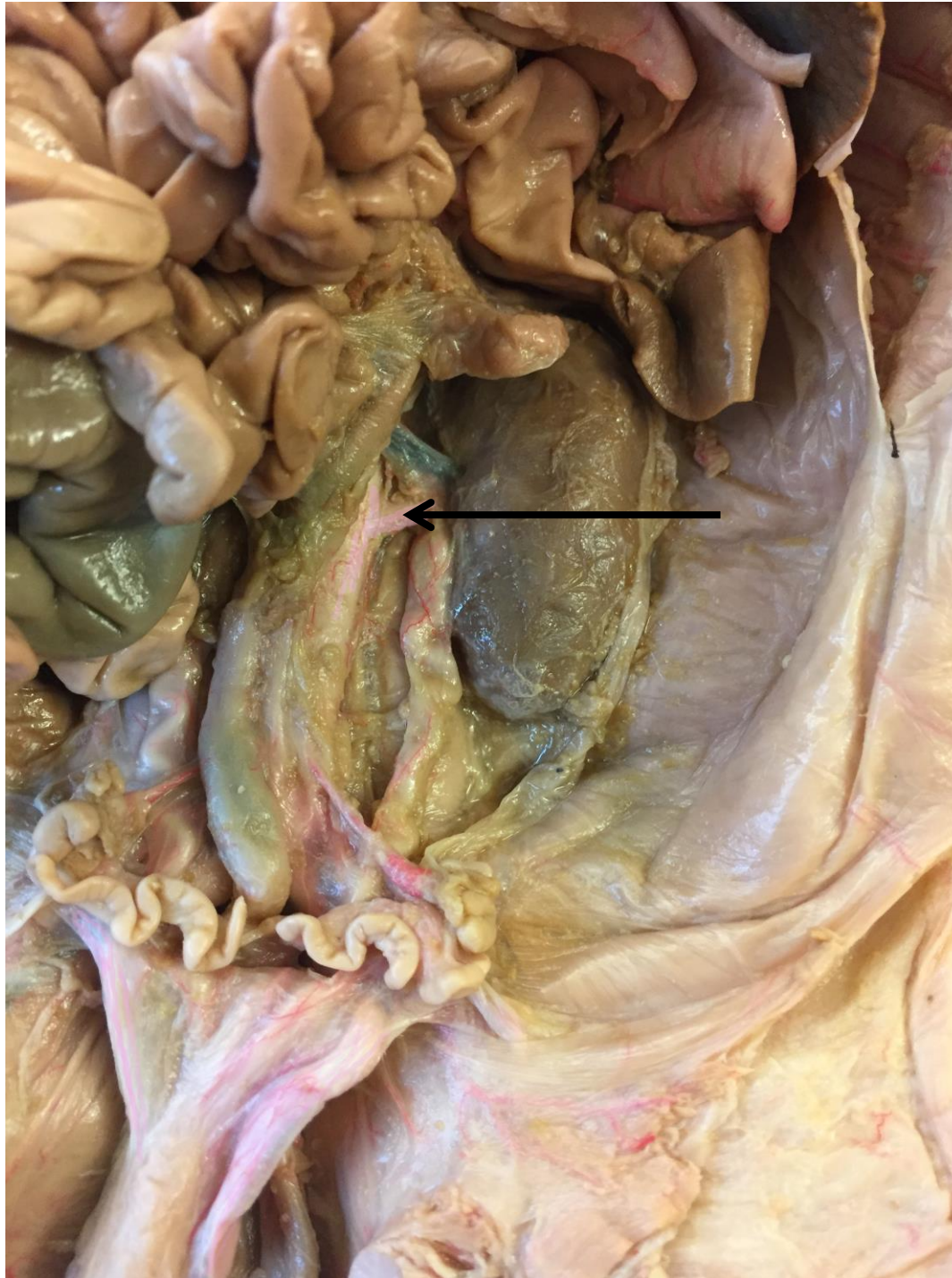




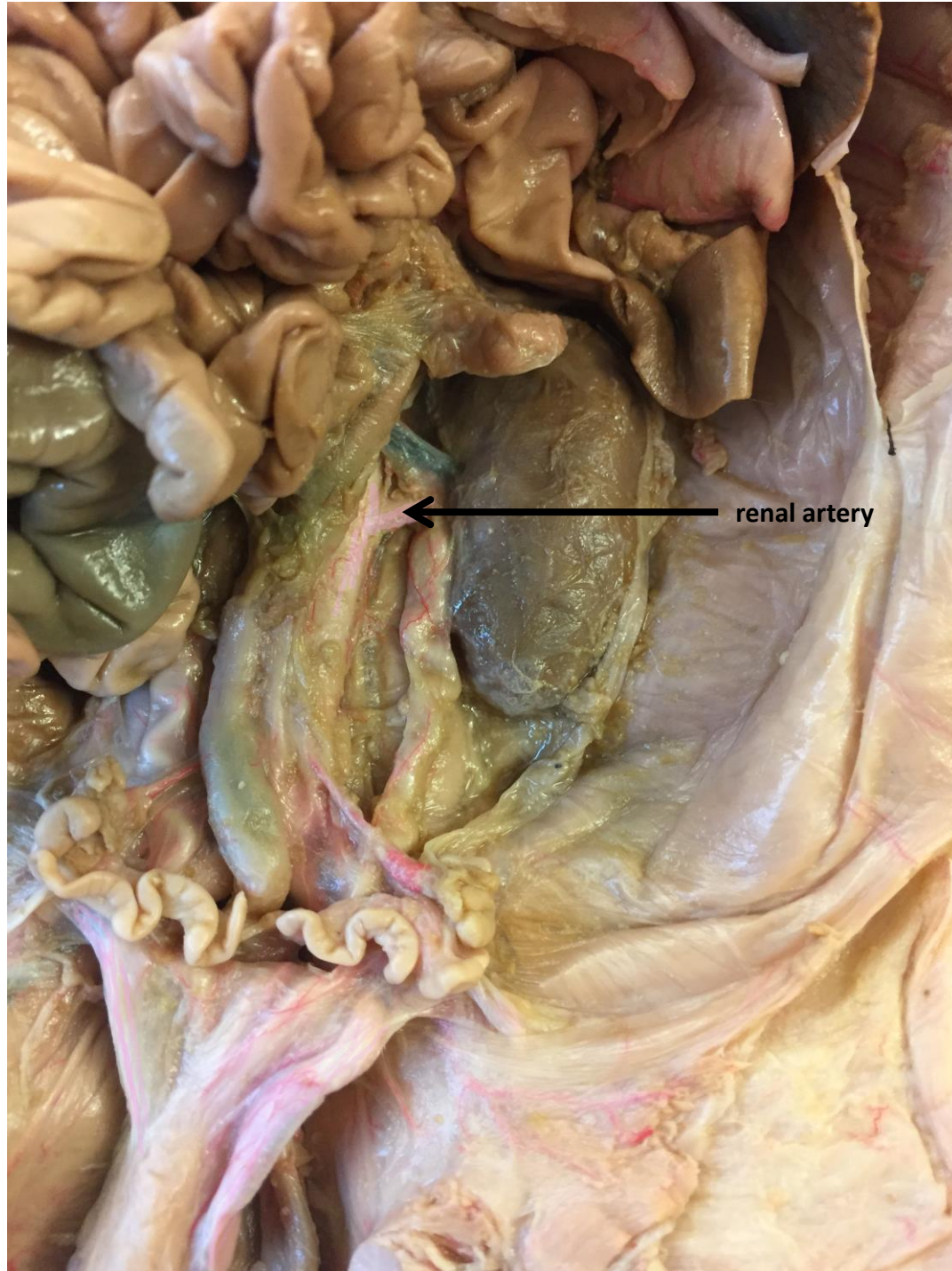*scroll to the next slide to check your answer



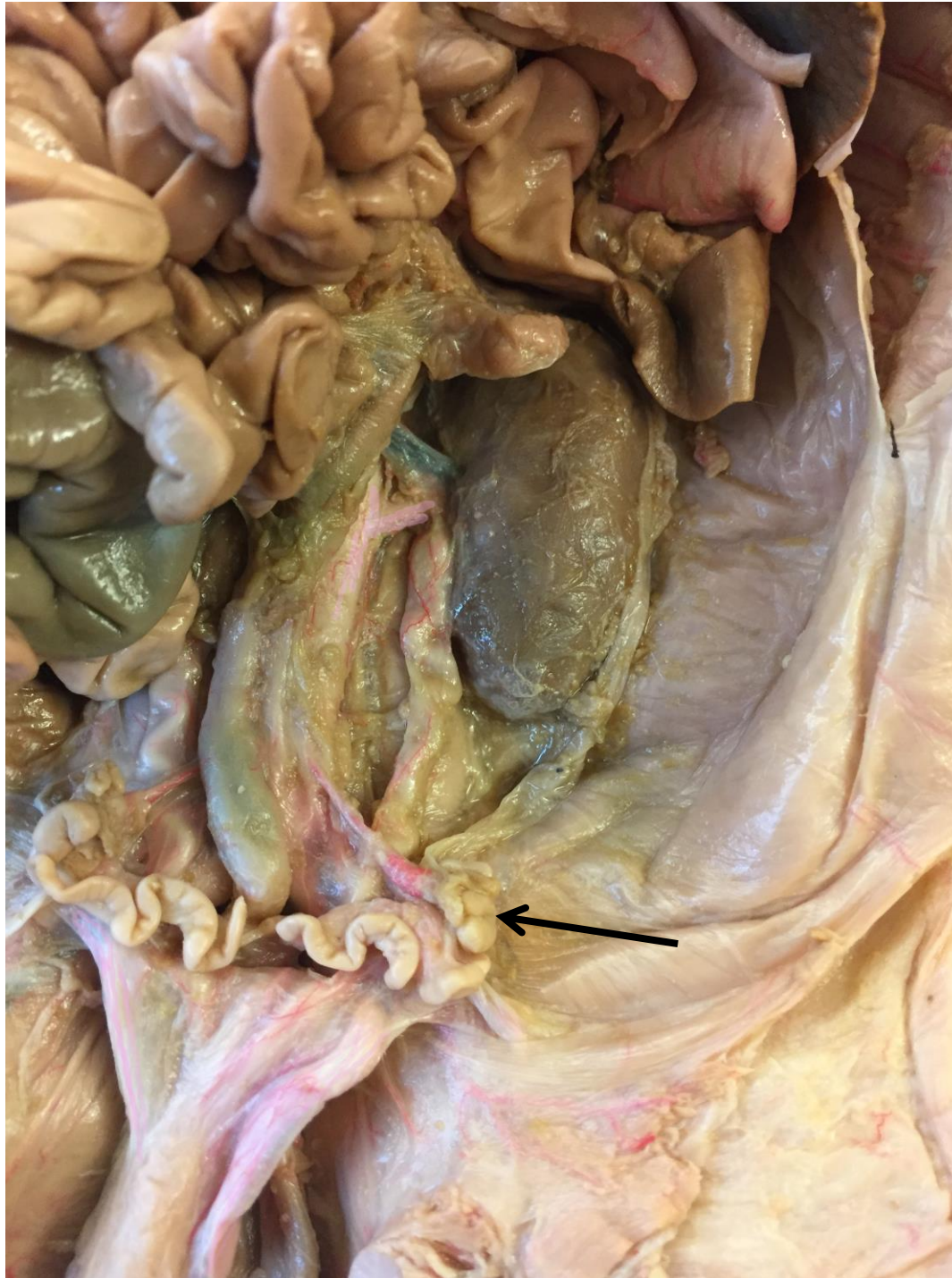Epididymis



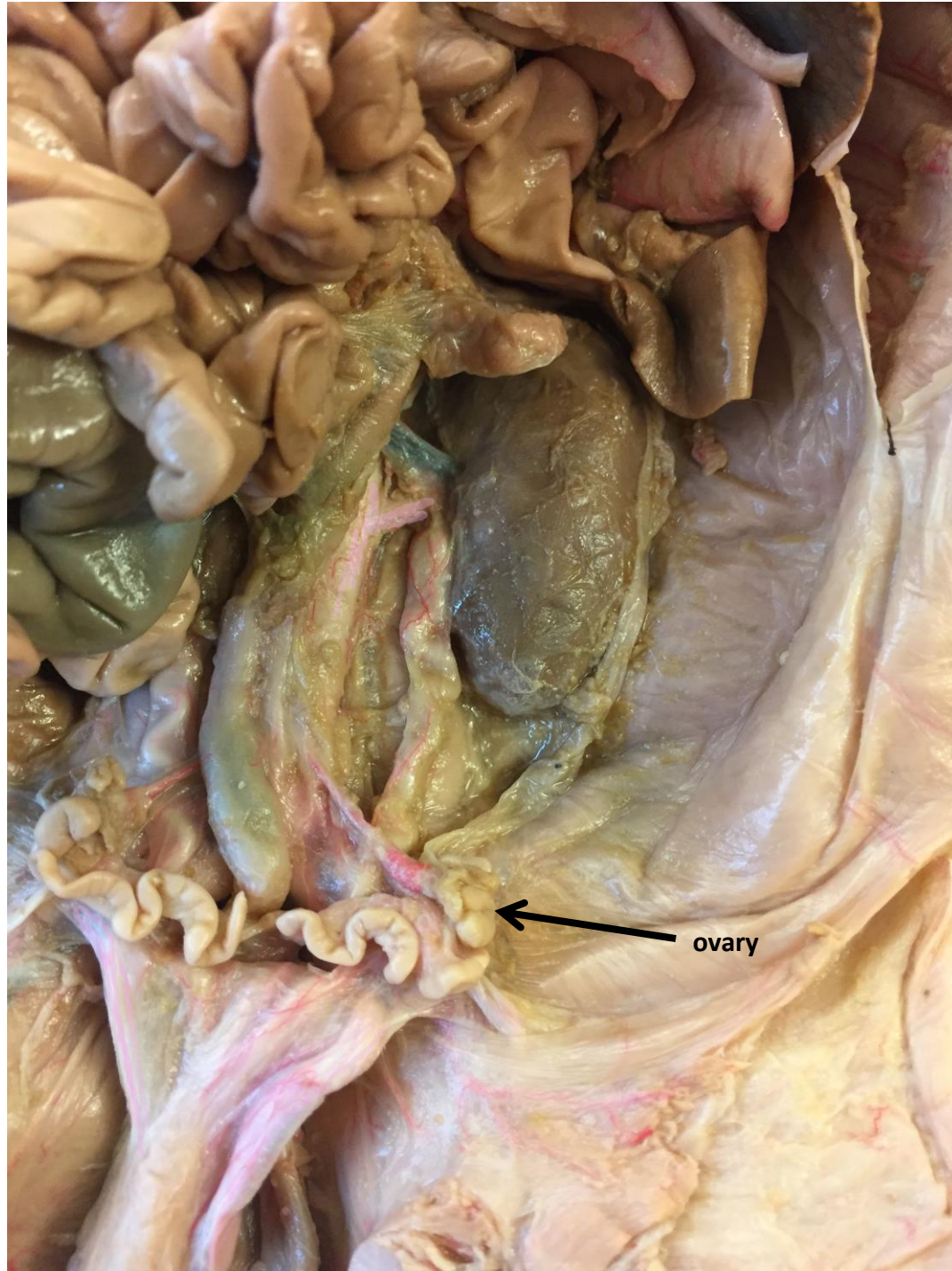*scroll to the next slide
to check your answer



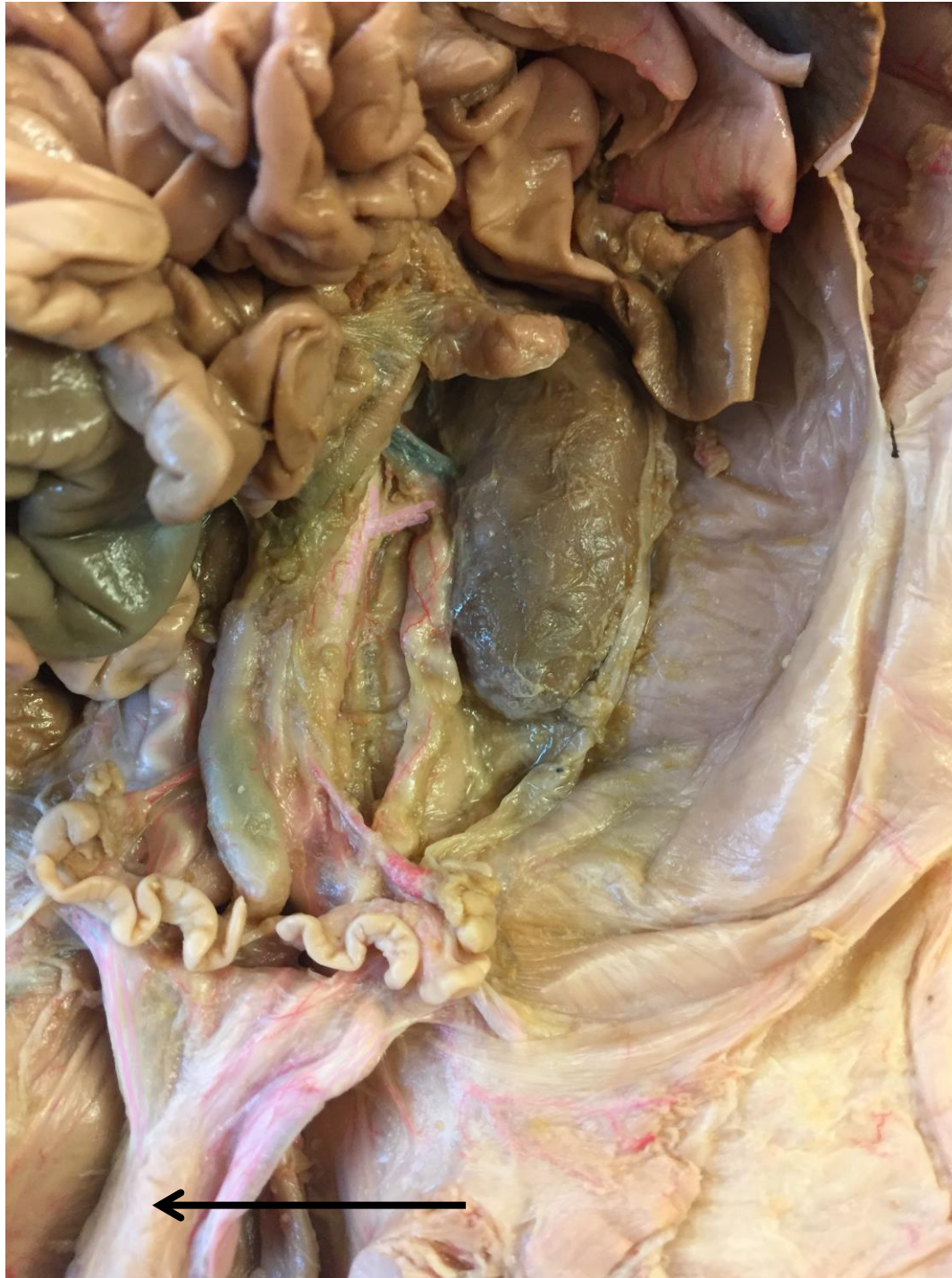renal artery



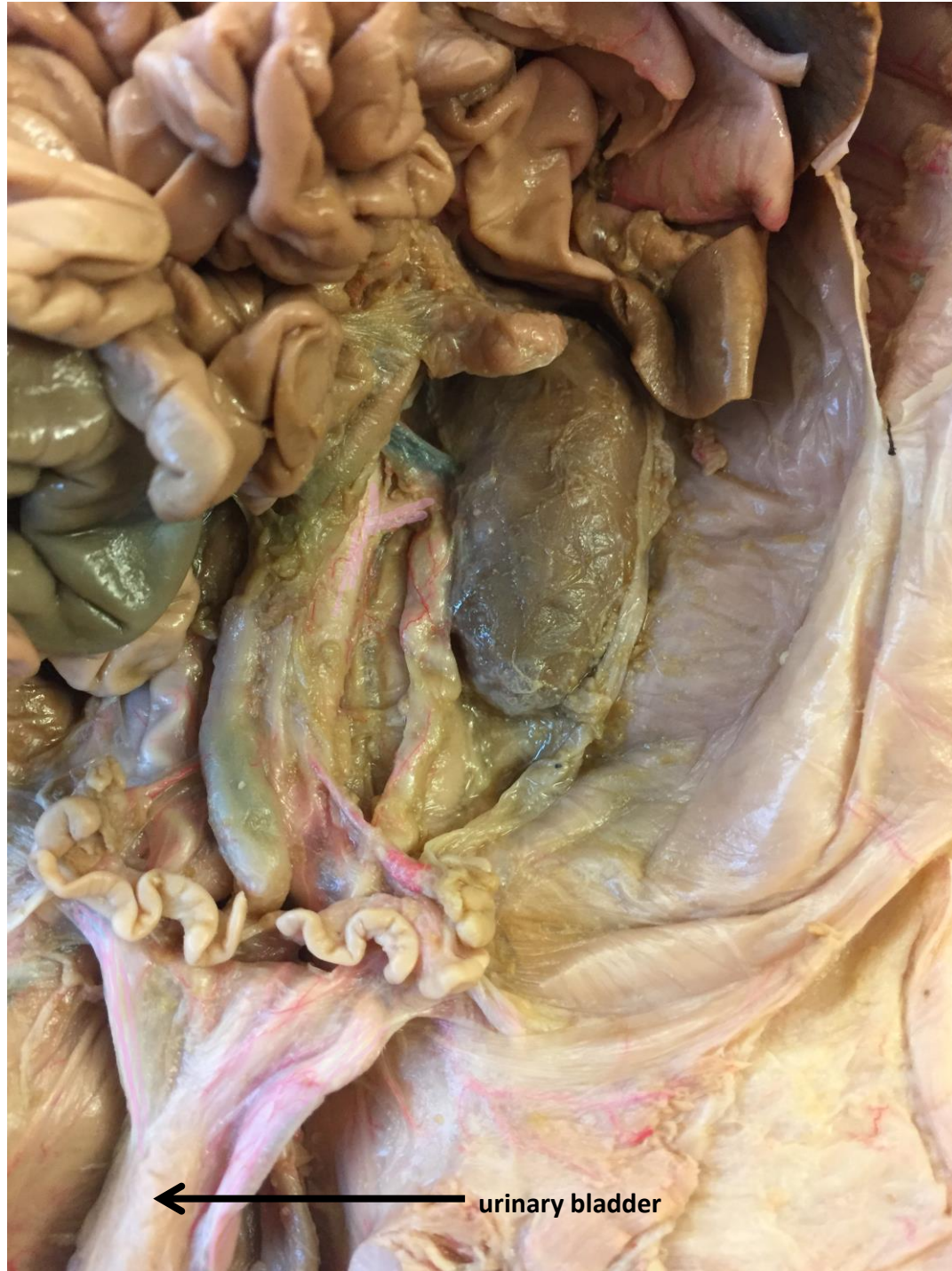*scroll to the next slide
to check your answer



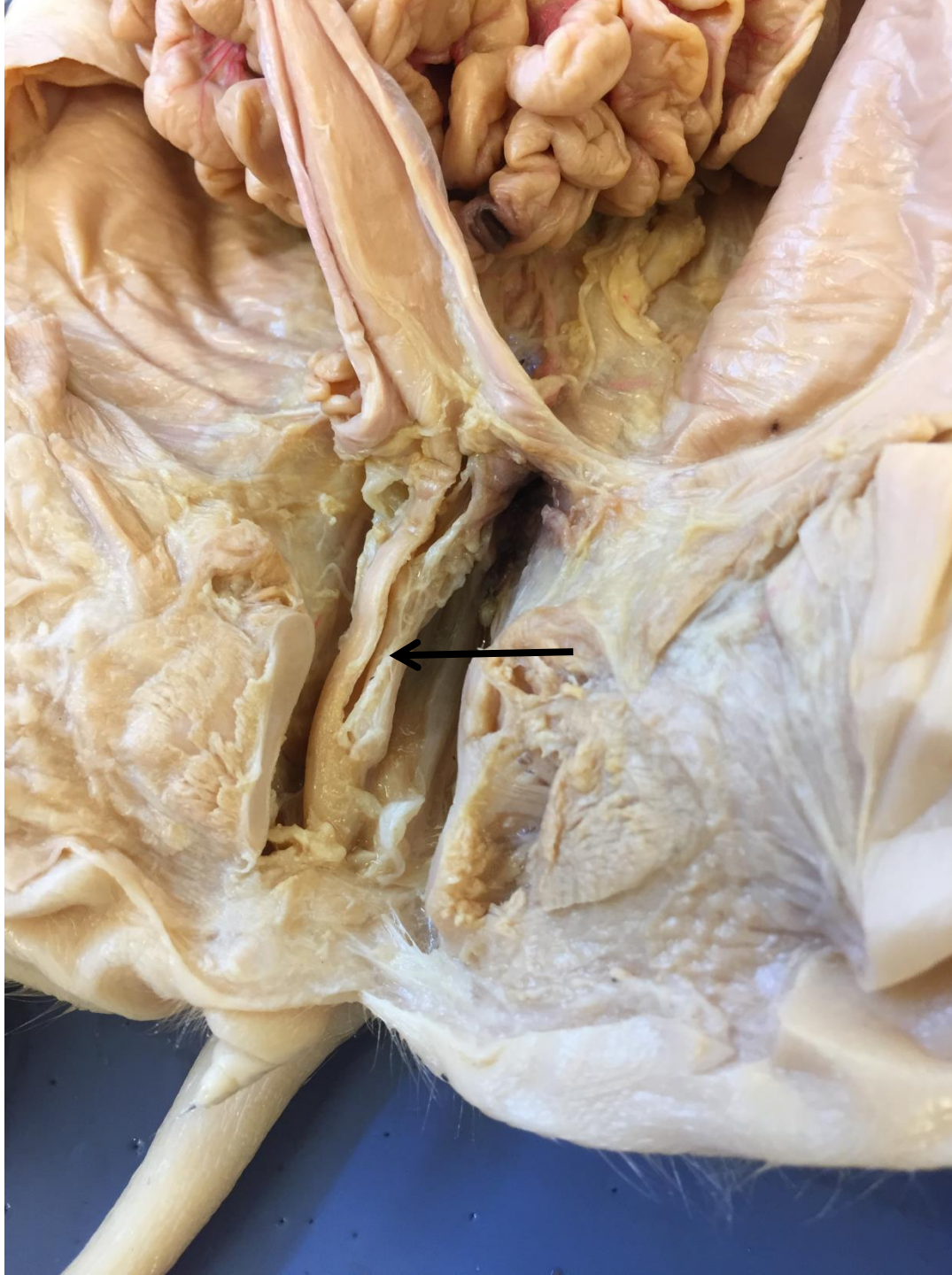
ovary



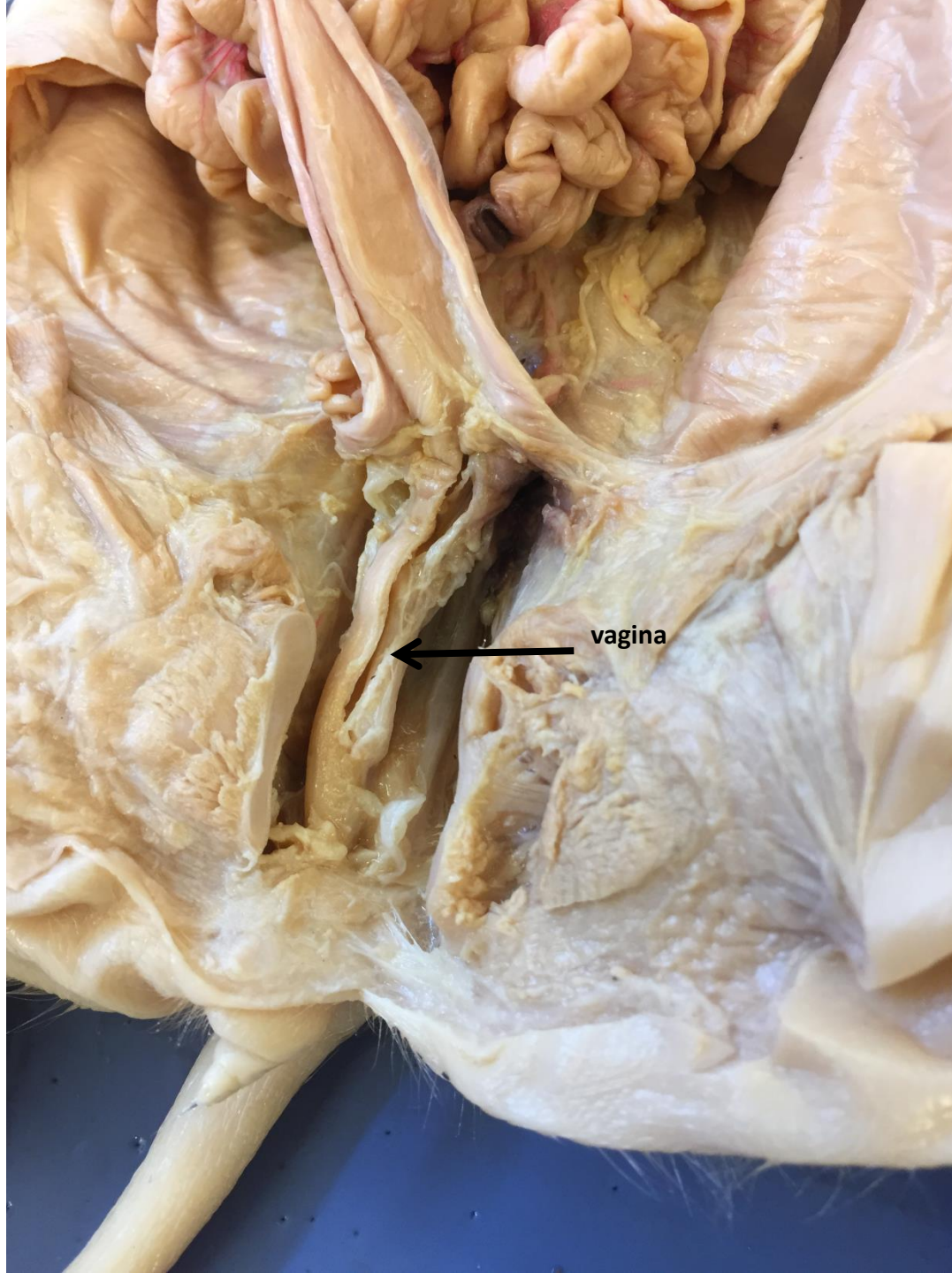*scroll to the next
slide to check your
answer

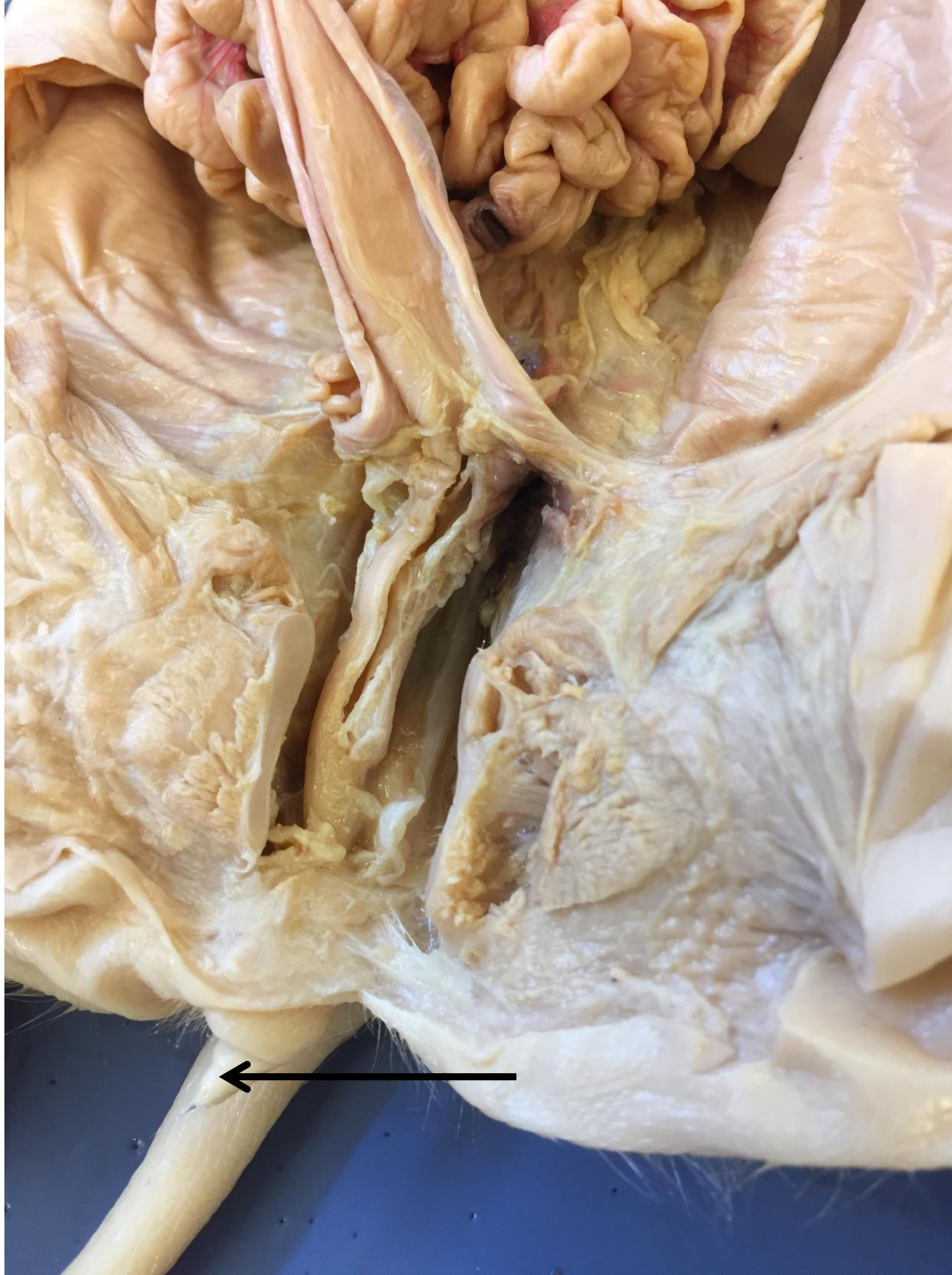

← urinary bladder

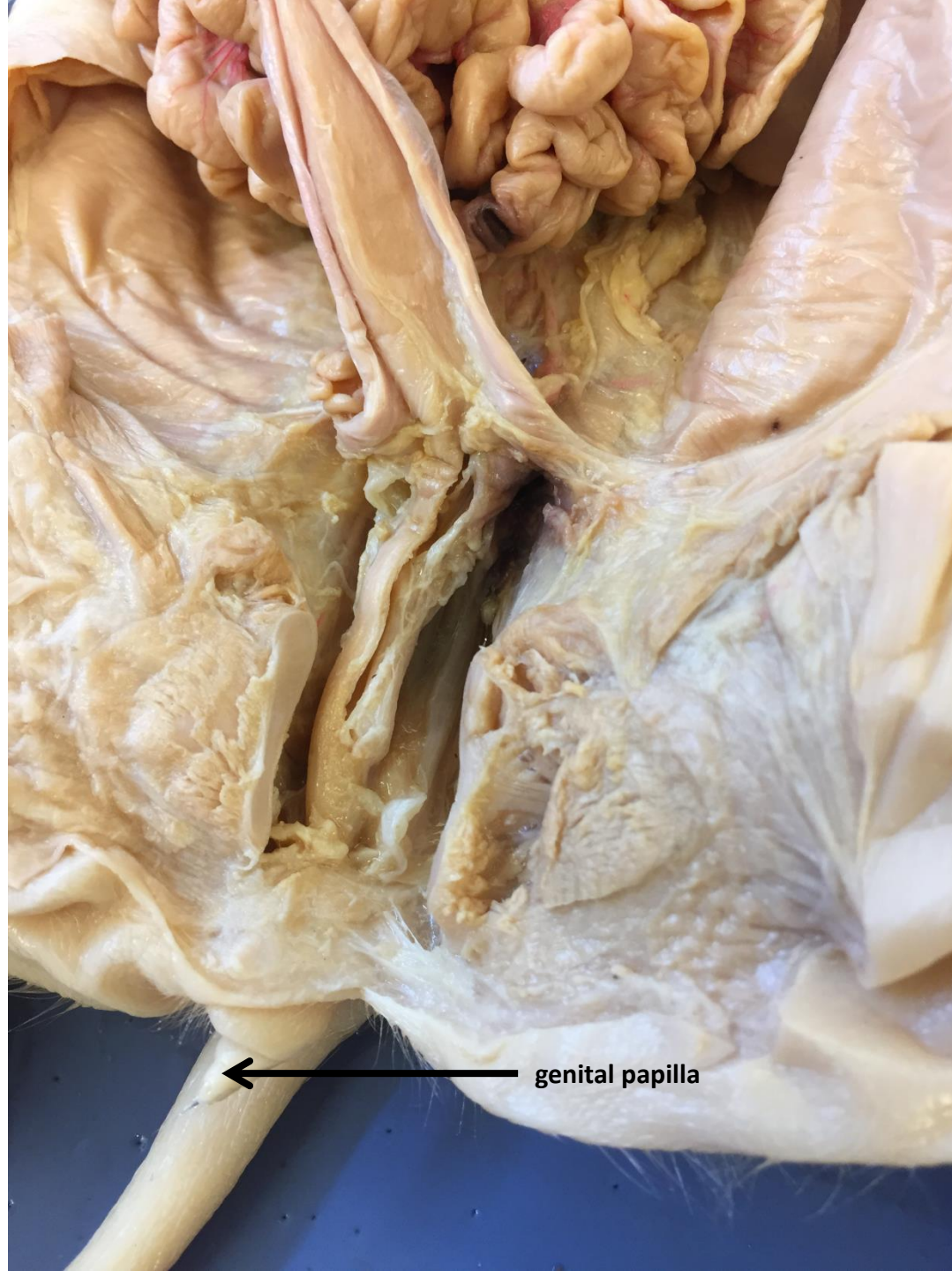


*scroll to the next slide
to check your answer





*scroll to the
next slide to
check your
answer



genital papilla