

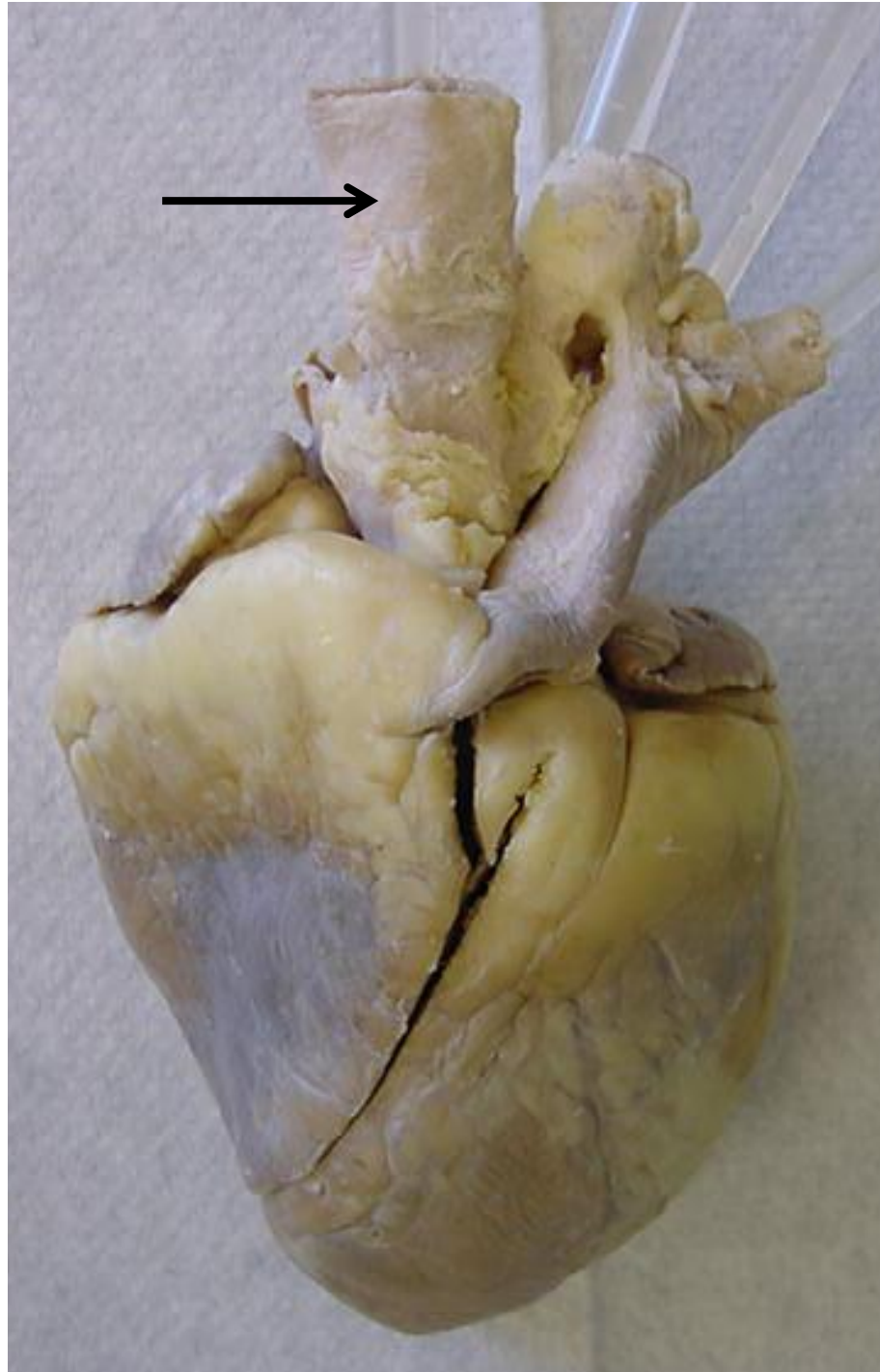
Sheep Heart Practice Exam #1

Name the following structures indicated by the arrows.

Scroll to the next slide to see the answer.

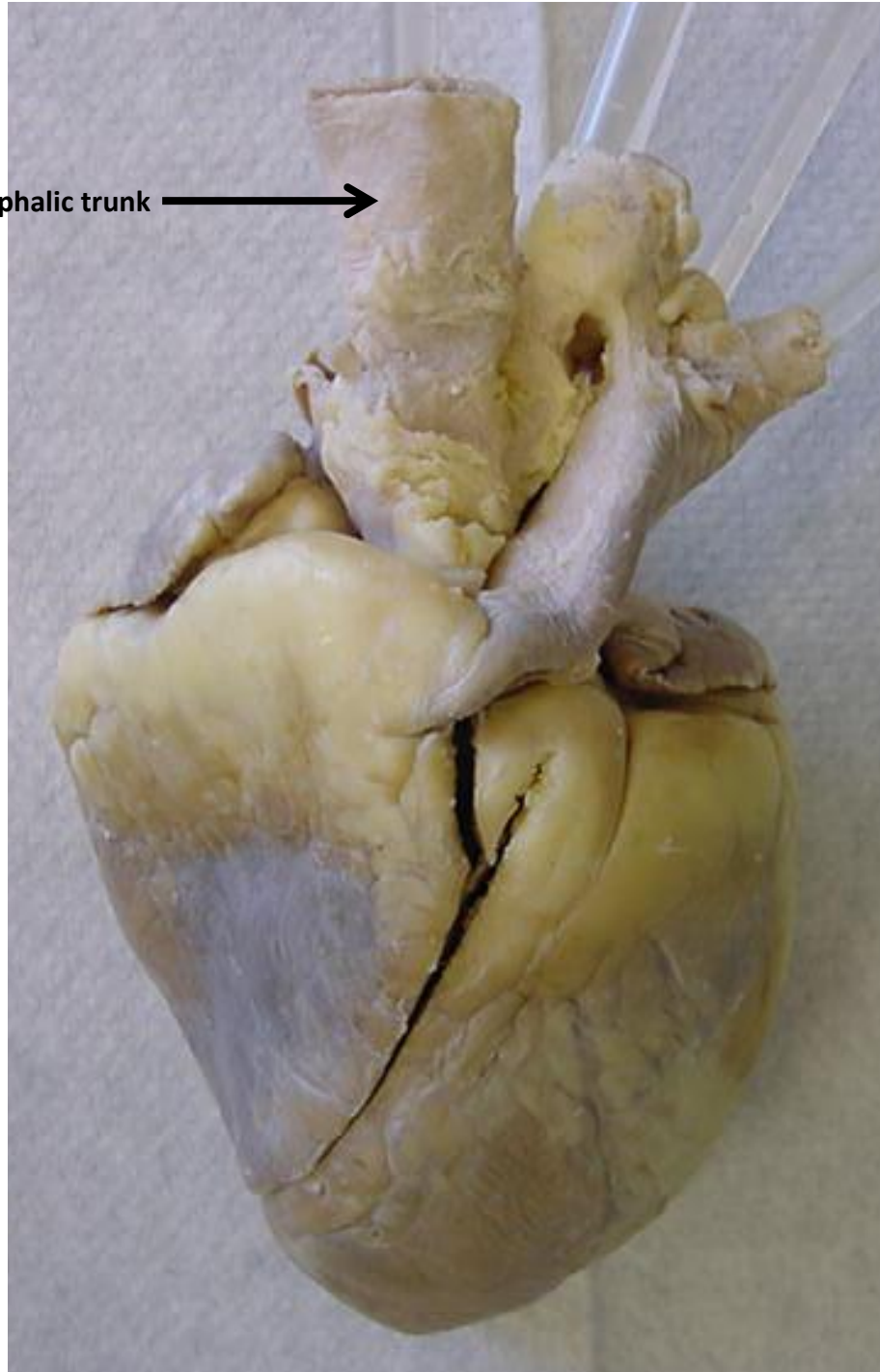
*For best results on these practice exams, write your answers on paper before scrolling to see the correct answer. Try to answer within a minute (remember your lab exams will be timed) and make sure to check your spelling!

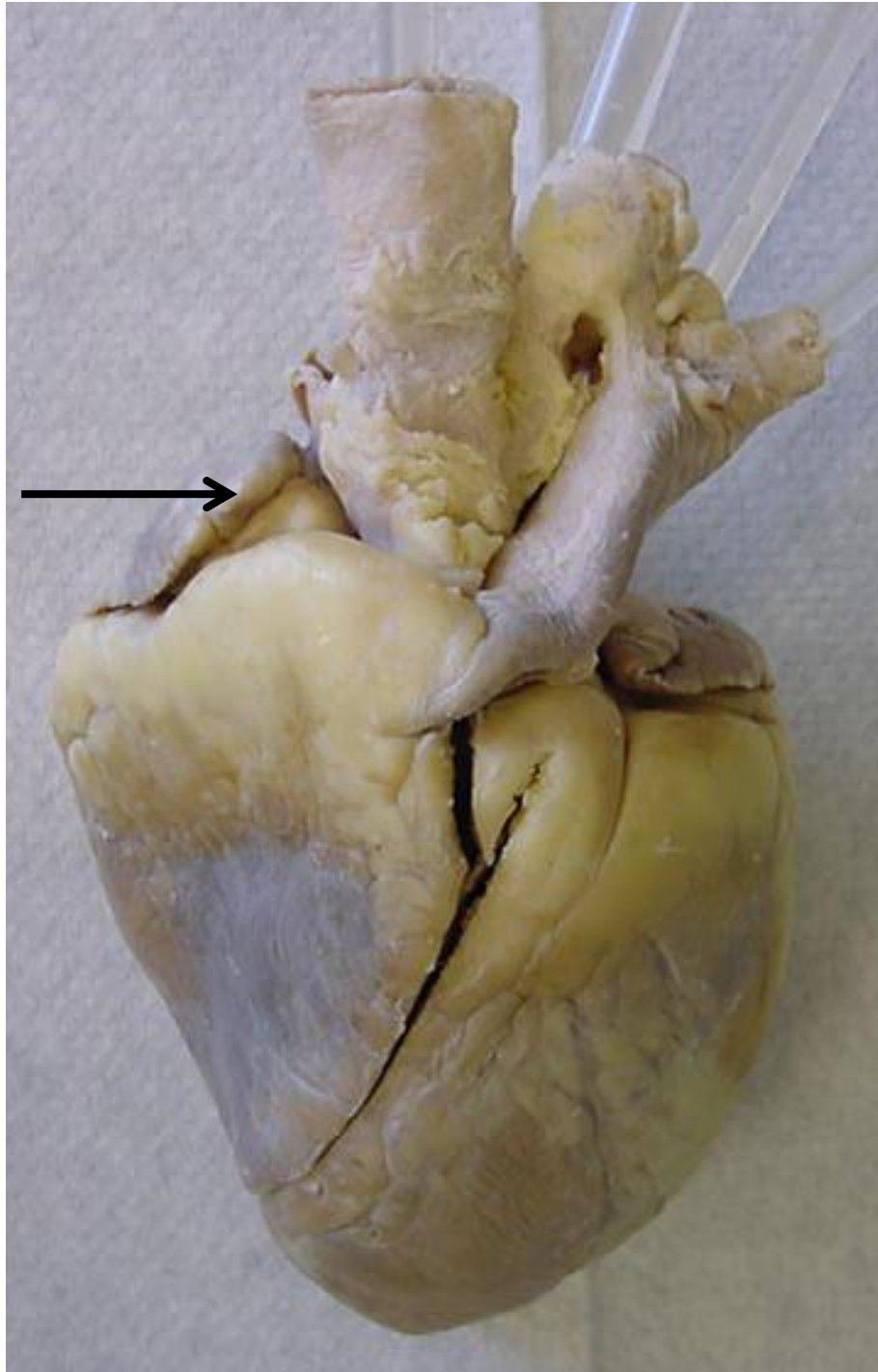
*note: not every structure you are required to know will be on this practice exercise so make sure you review the checklist of structures (p. 194 in your lab manual) when preparing for your lab exam



*scroll to the next slide to
check your answer

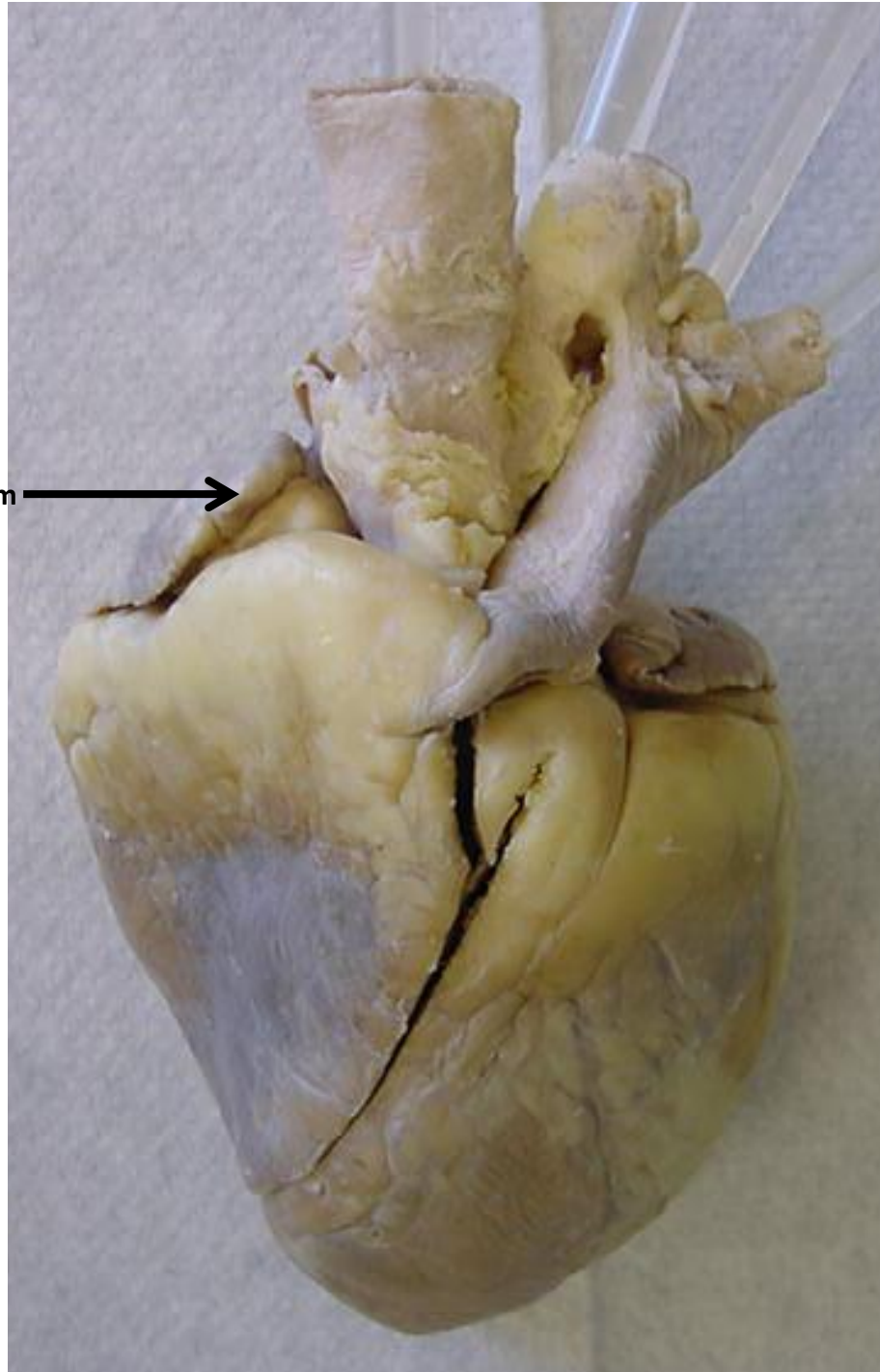
Brachiocephalic trunk →

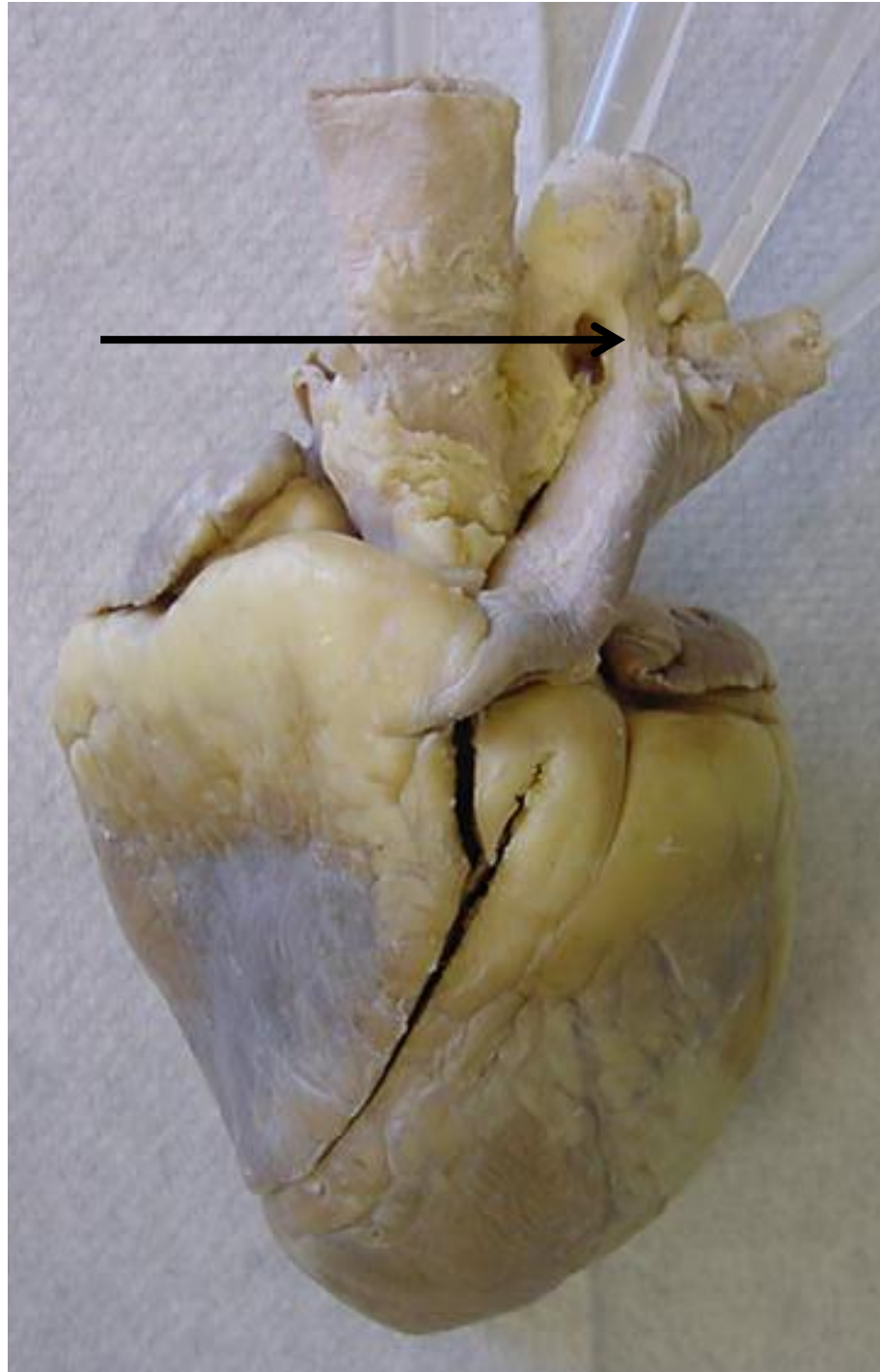




*scroll to the next slide to
check your answer

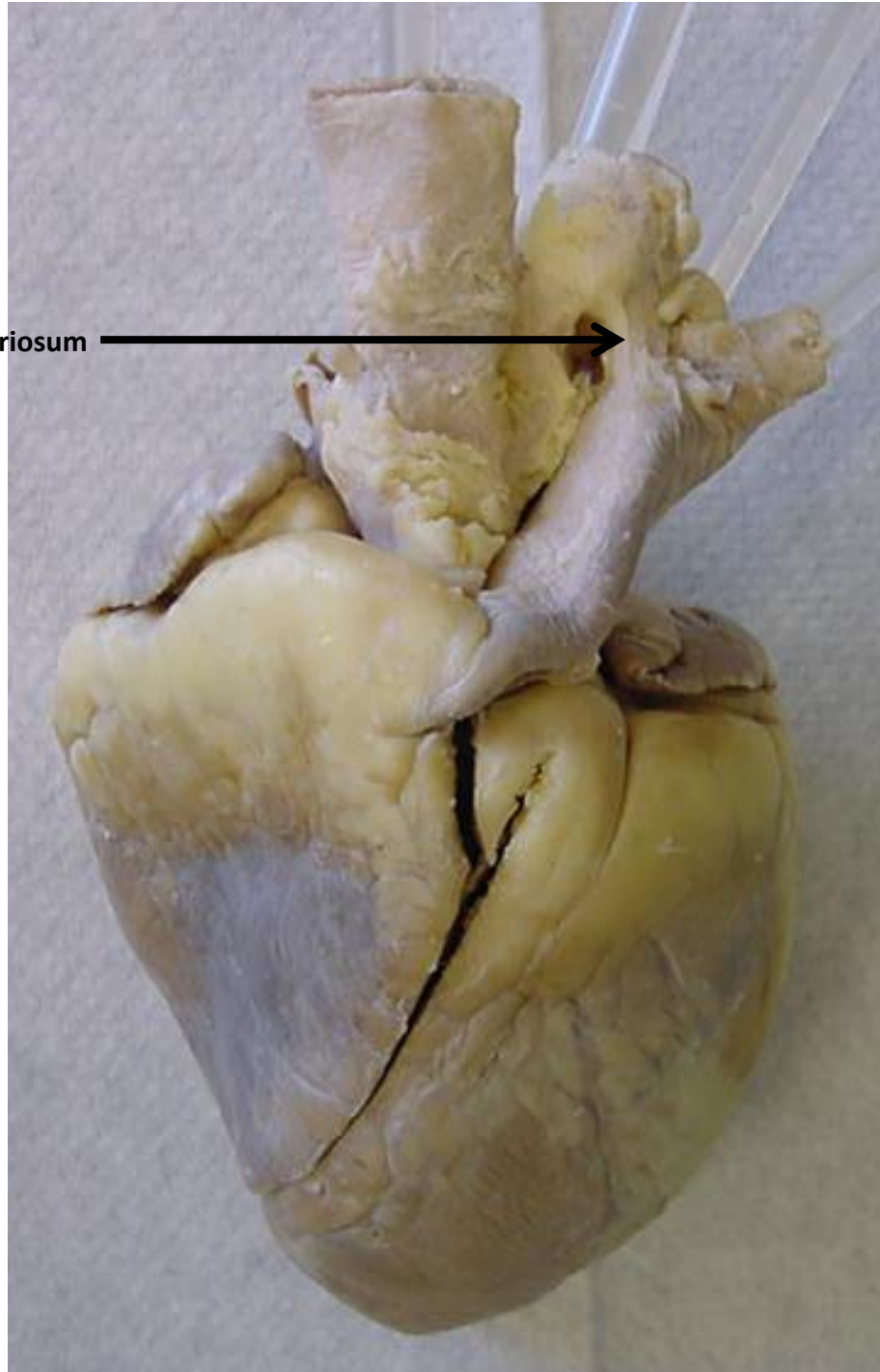

Auricle of right atrium →

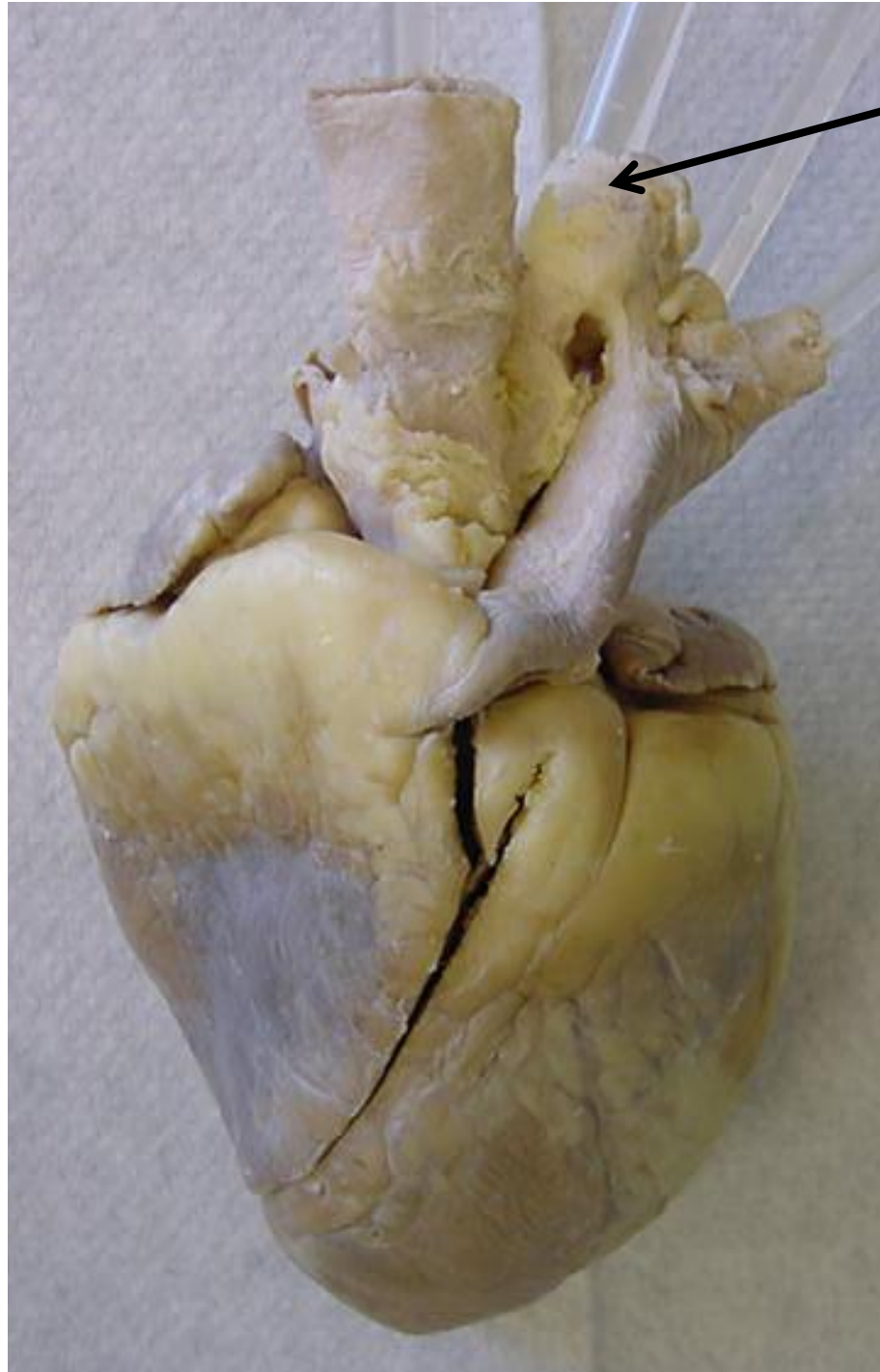




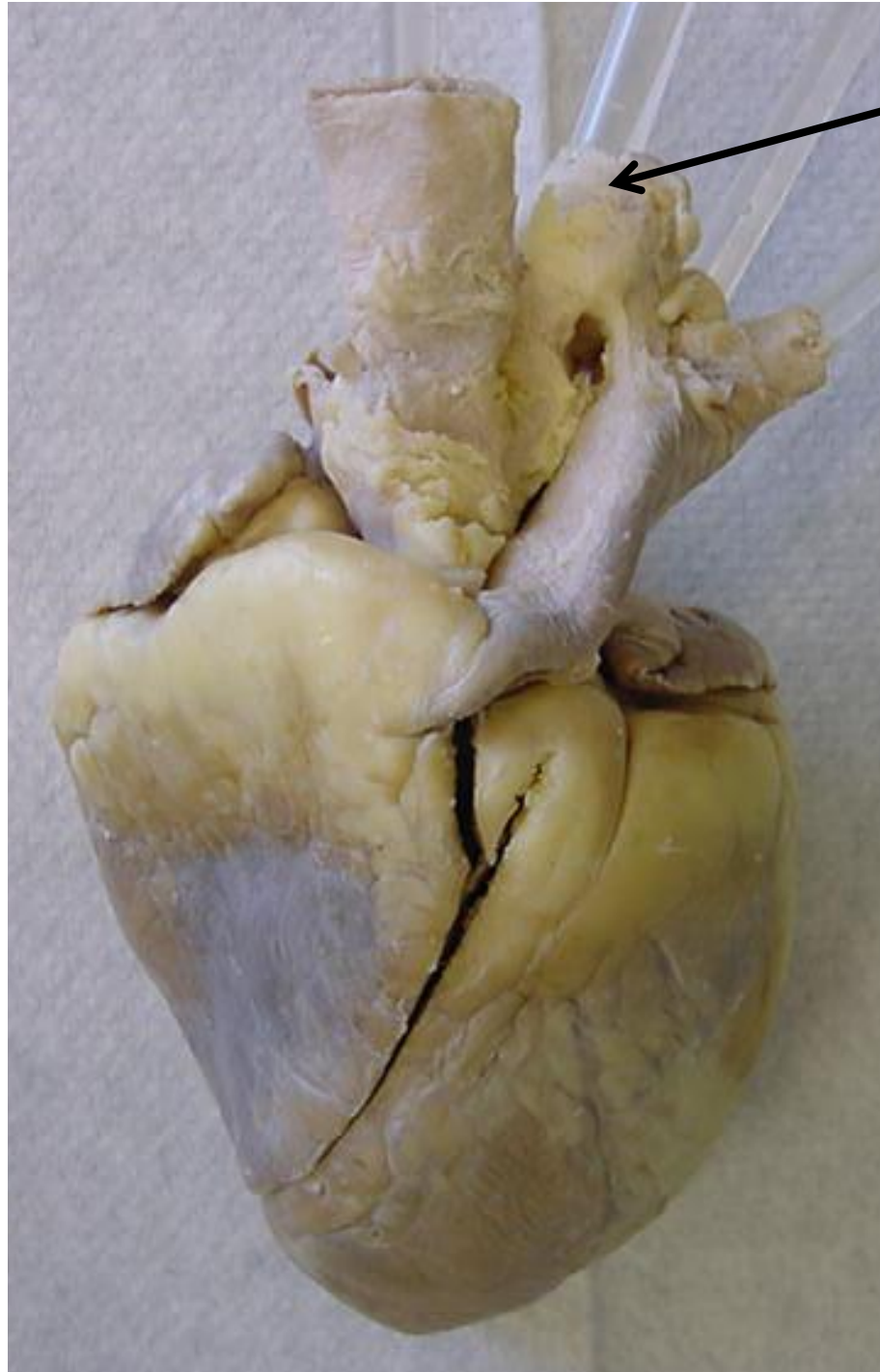
*scroll to the next slide to
check your answer

Ligamentum arteriosum

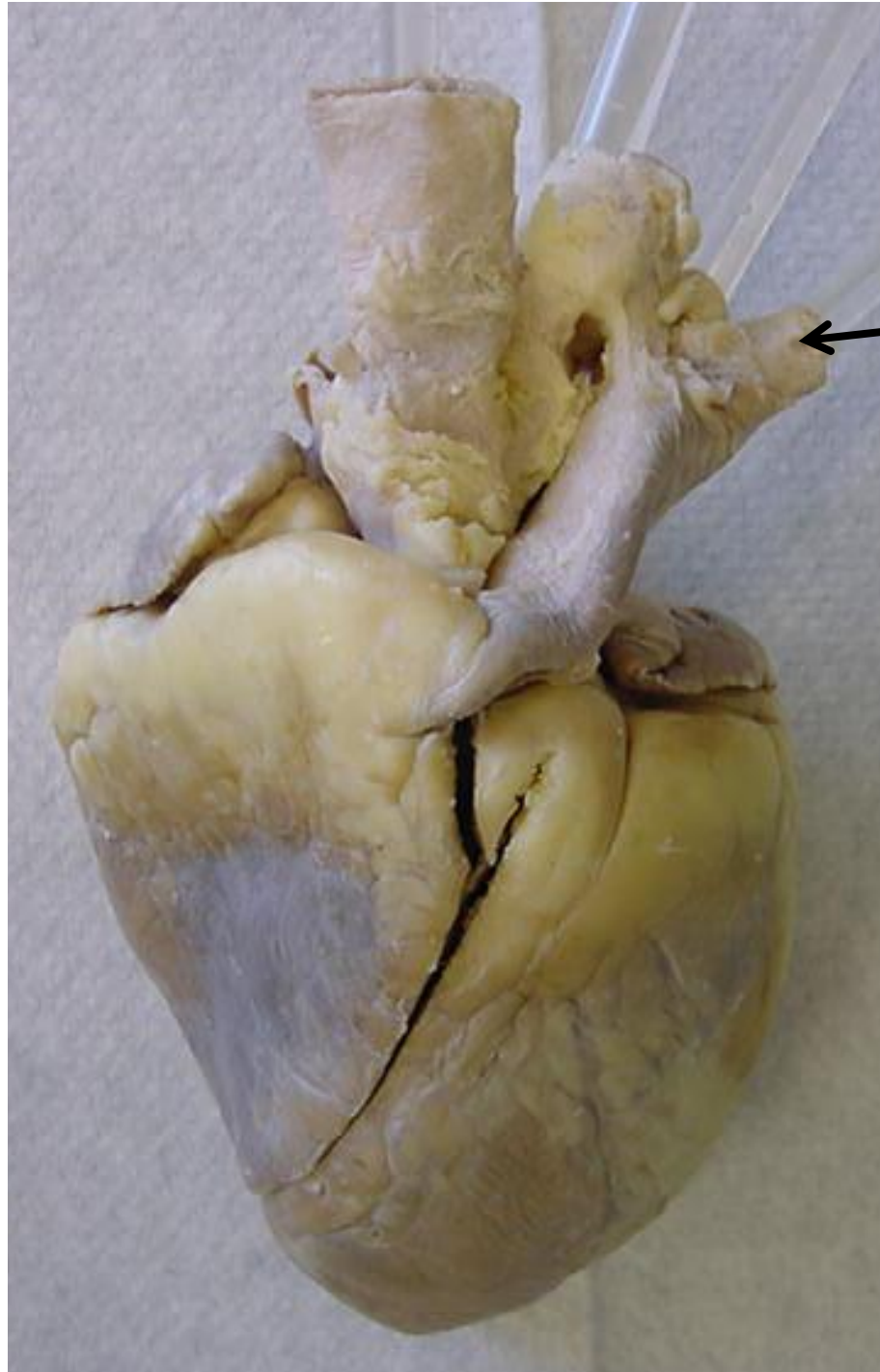




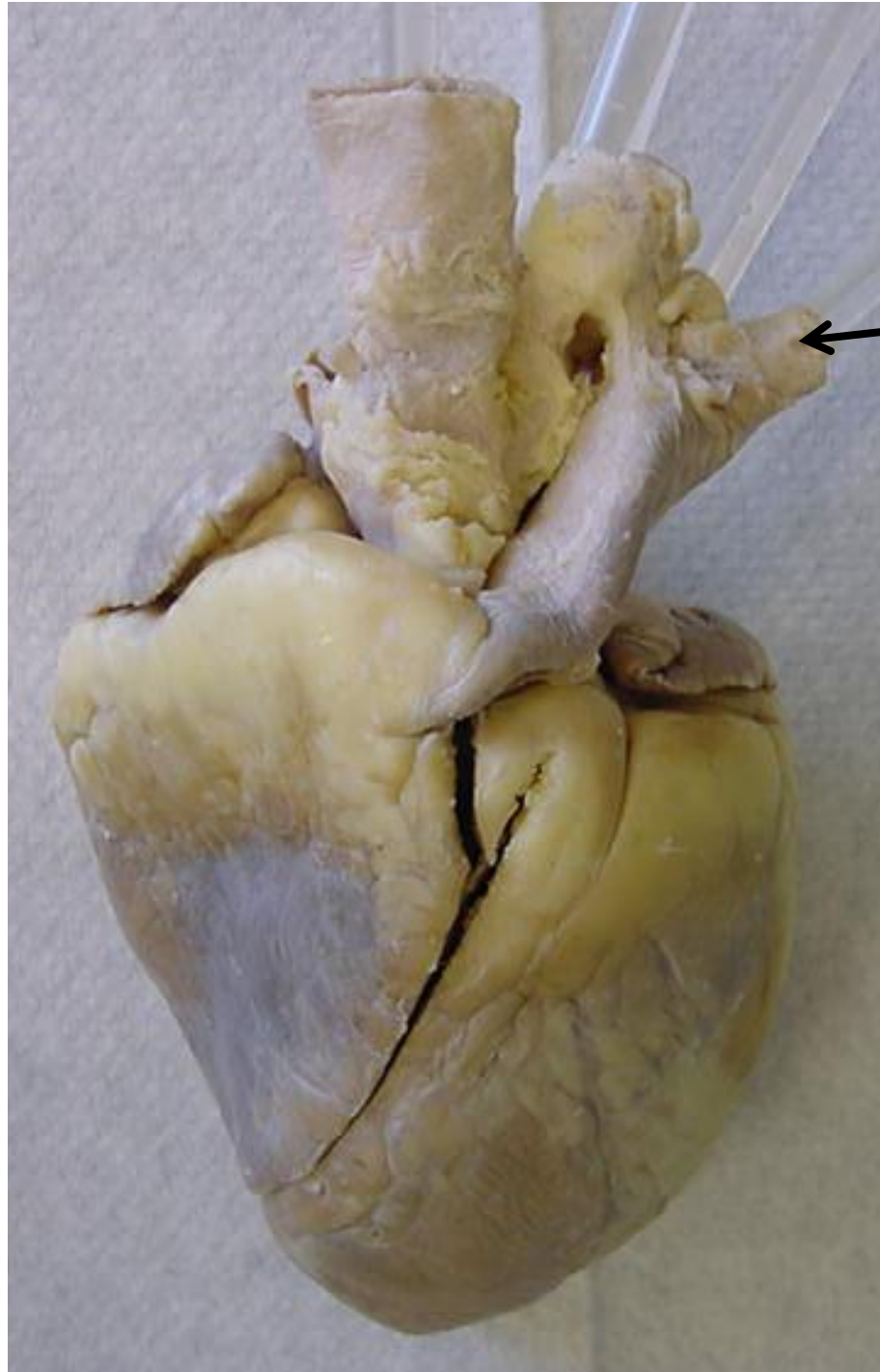
*scroll to the next slide to
check your answer



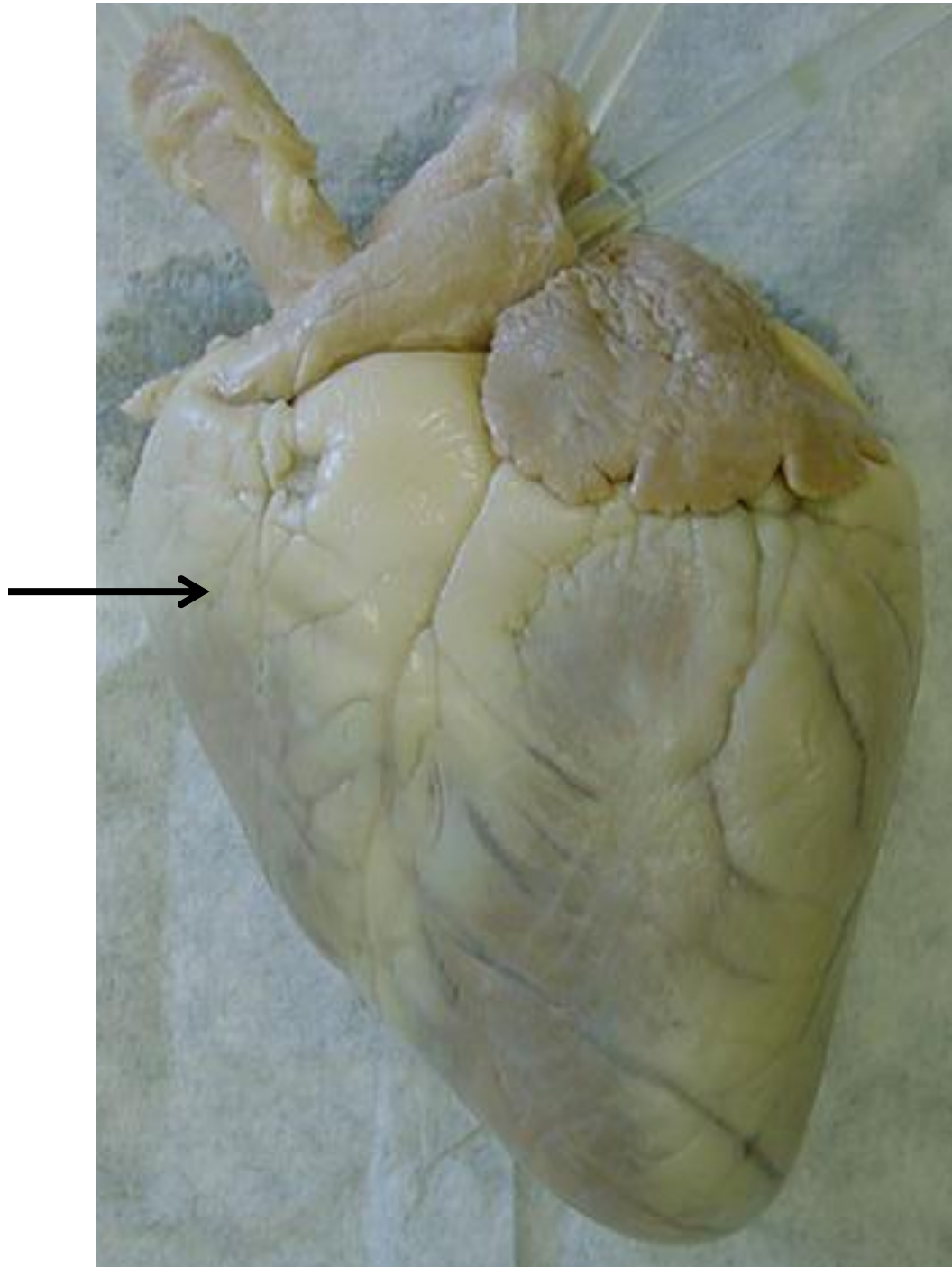
Aorta



*scroll to the next slide to
check your answer

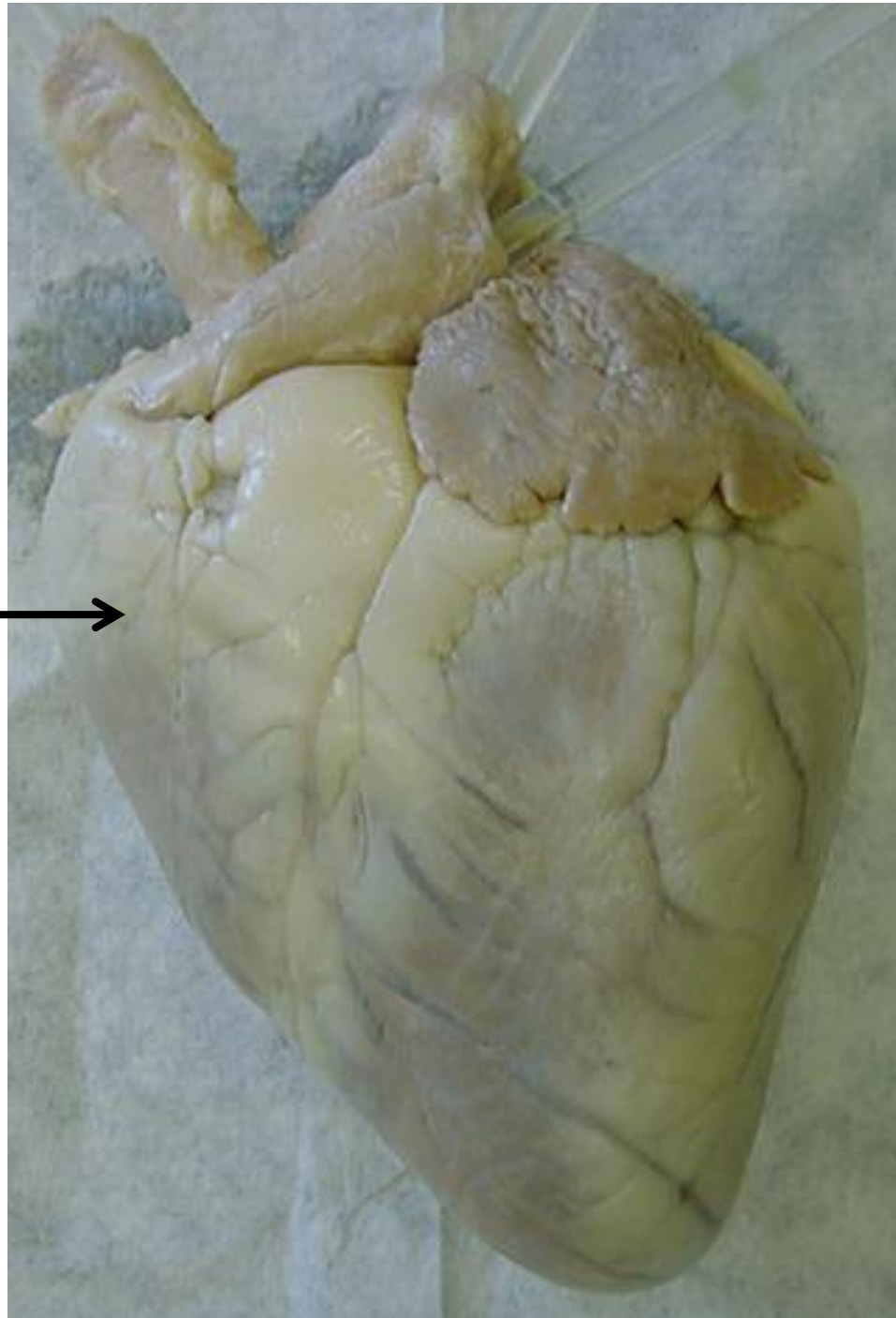


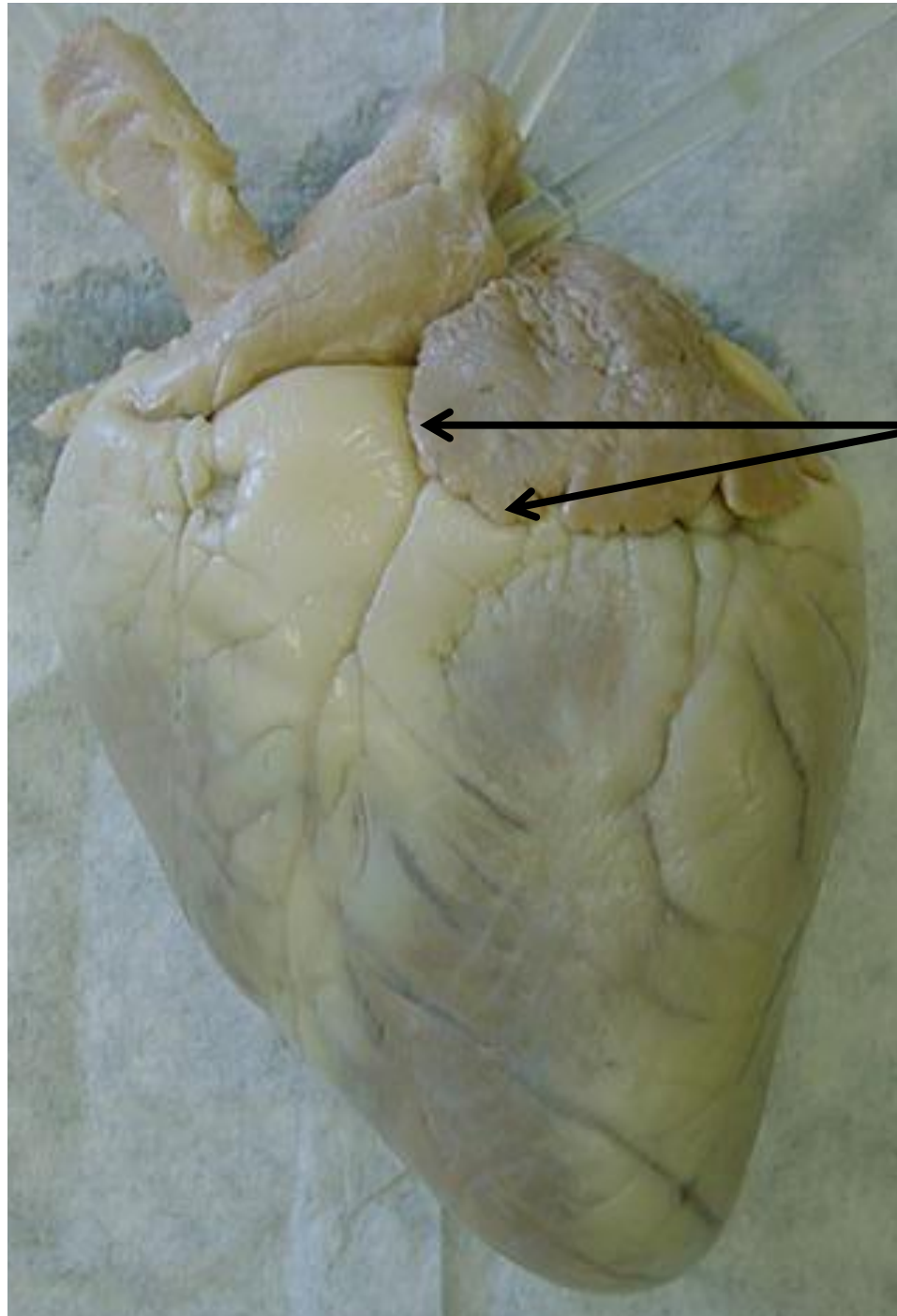
Left pulmonary artery



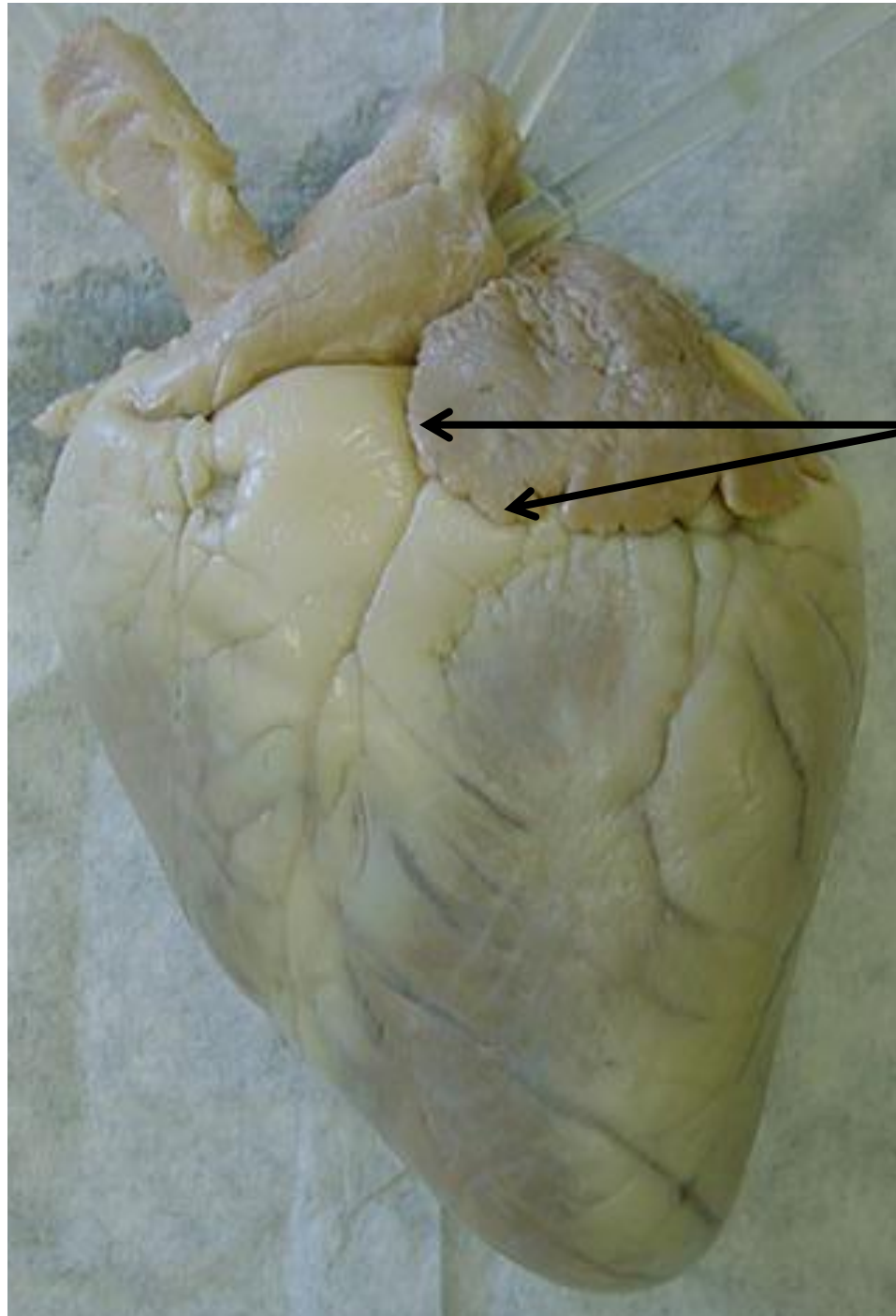
*scroll to the next slide to
check your answer

Right ventricle

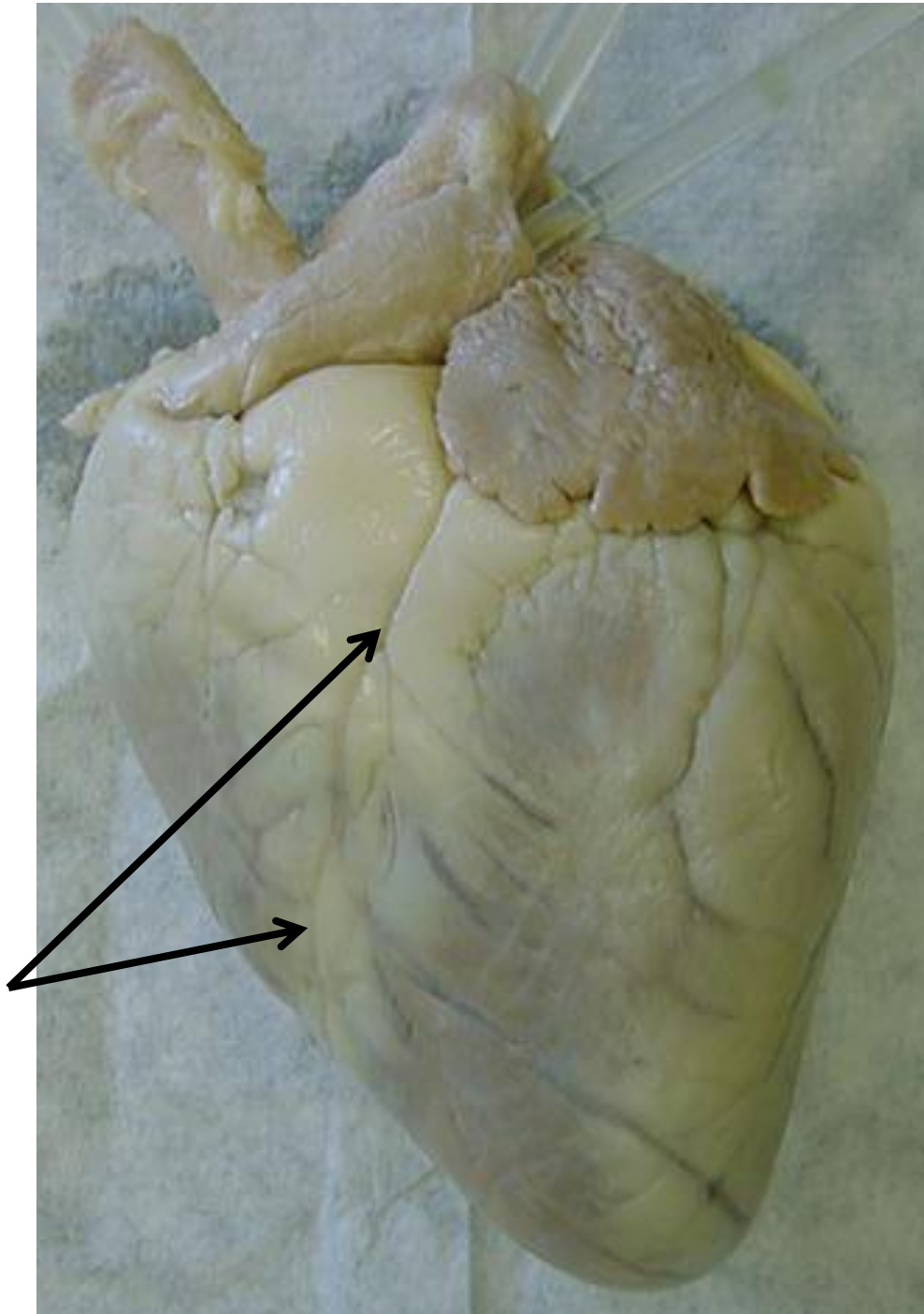




*scroll to the next slide to
check your answer

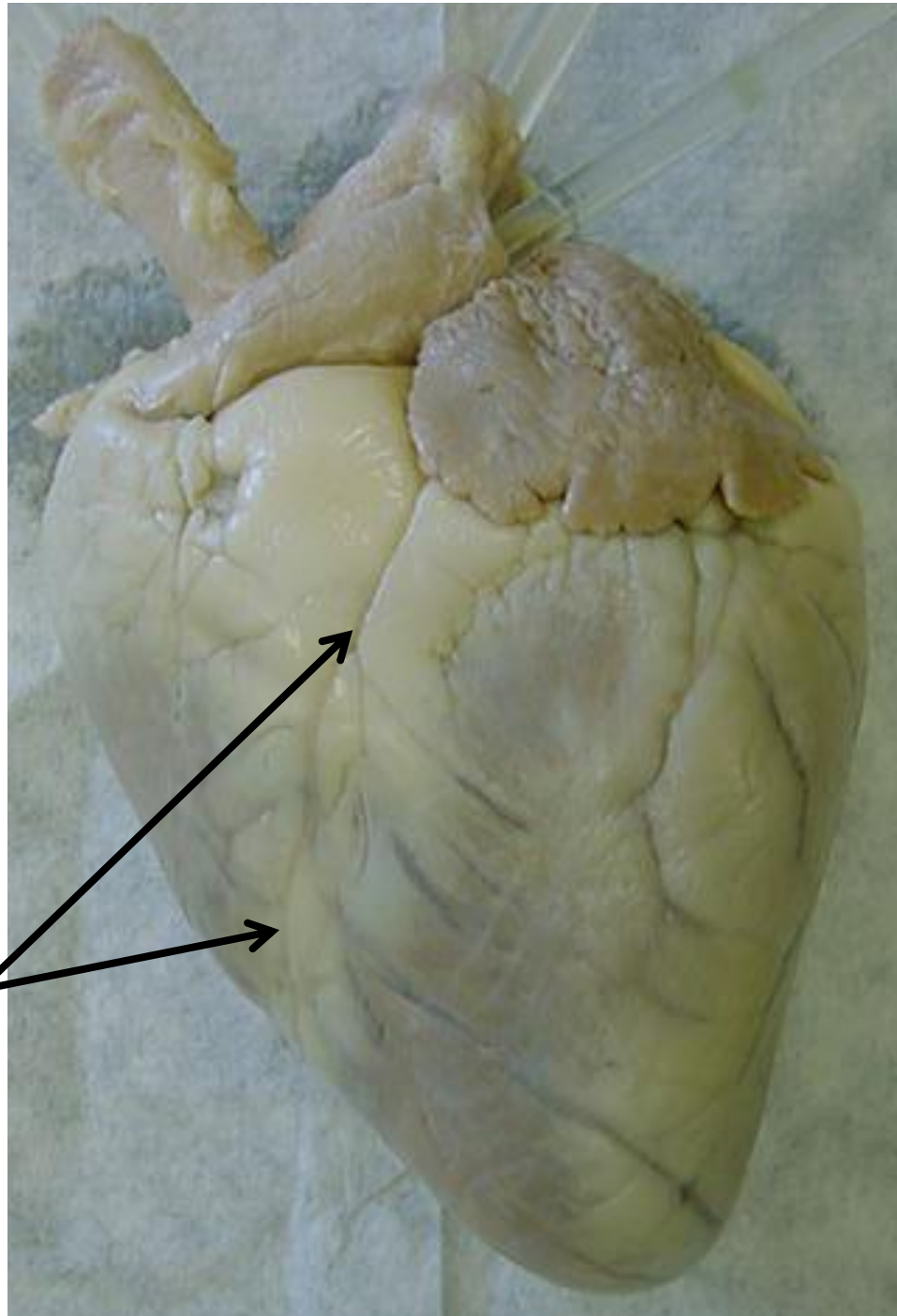


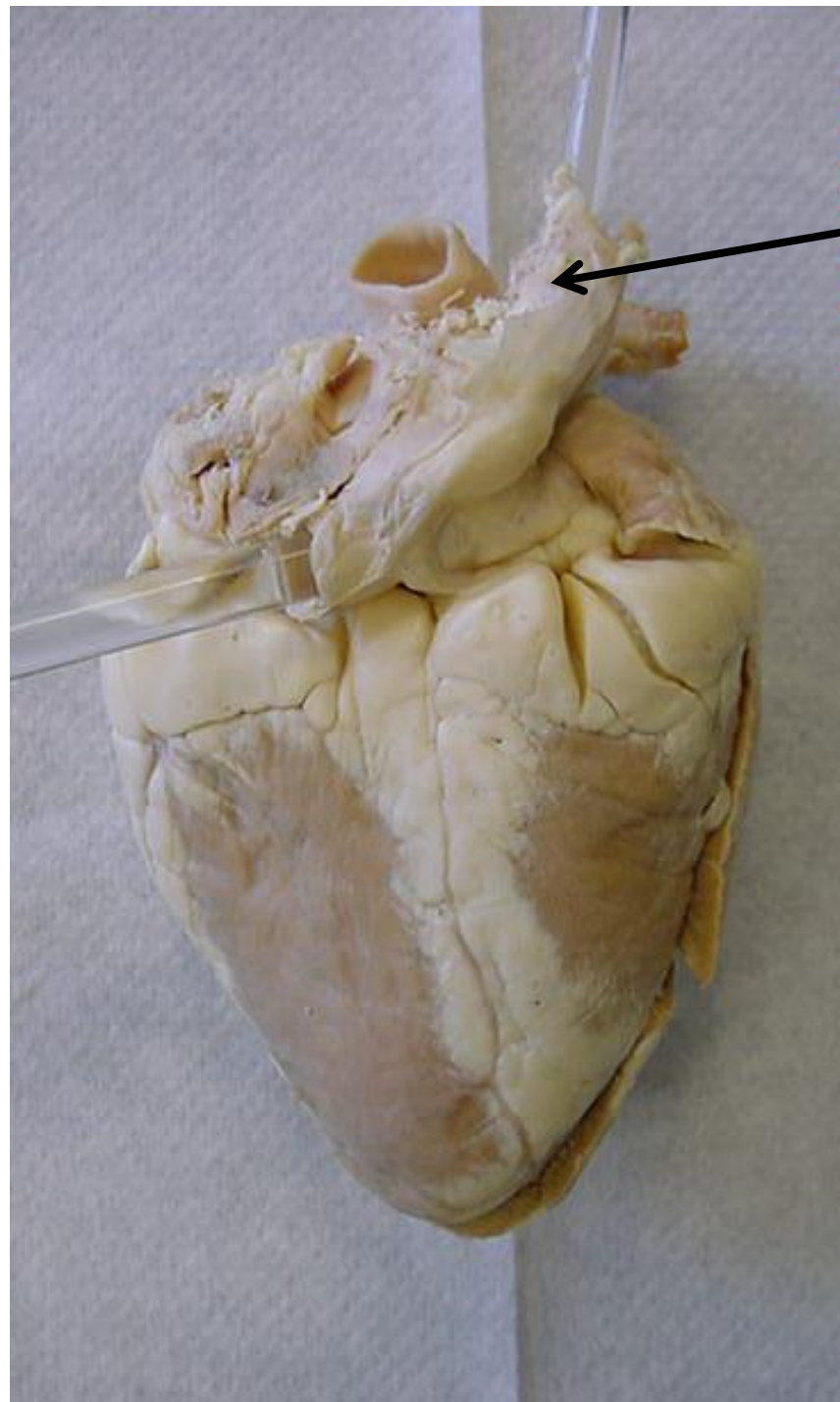
Auricle of left atrium



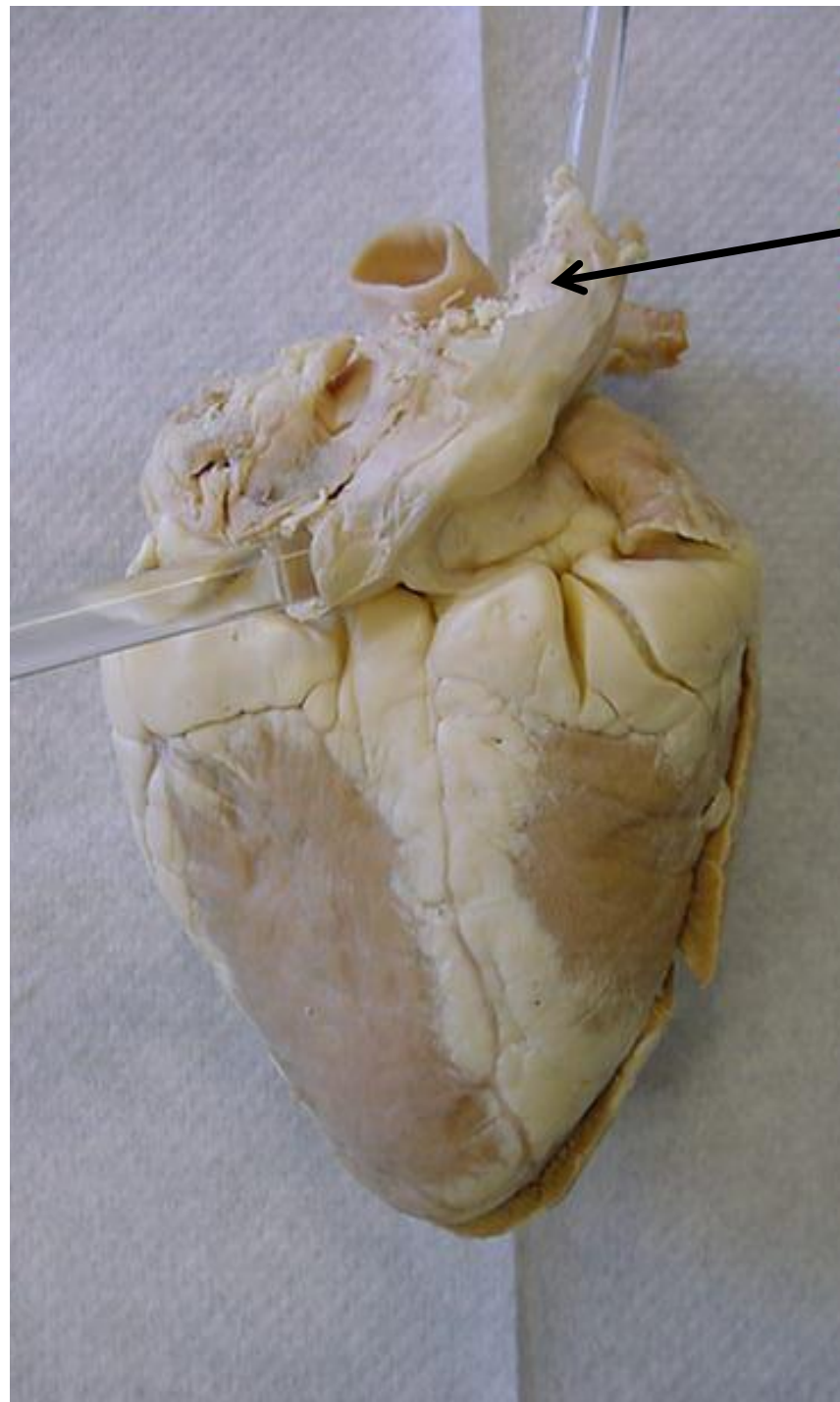
*scroll to the next slide to
check your answer

Anterior interventricular
sulcus

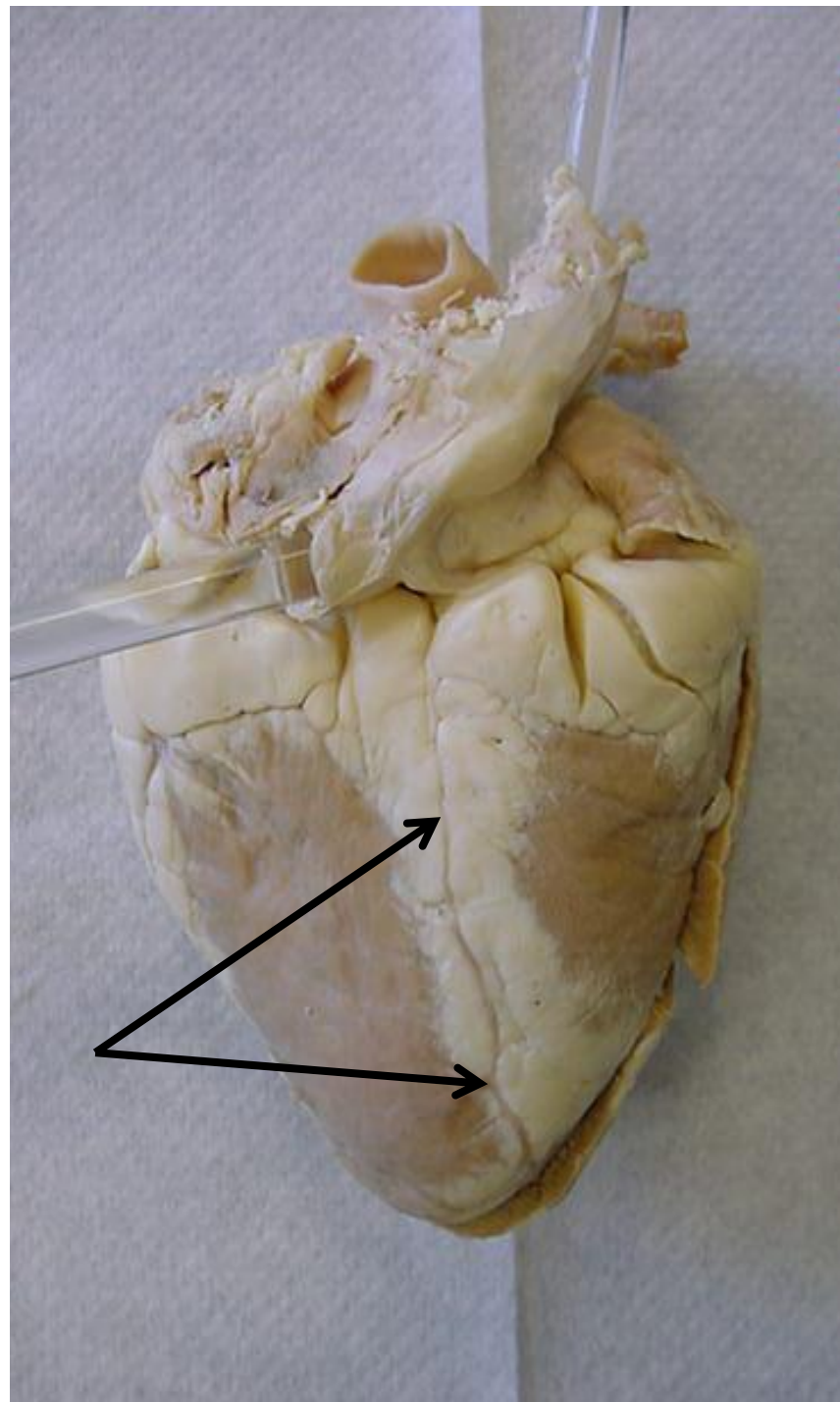




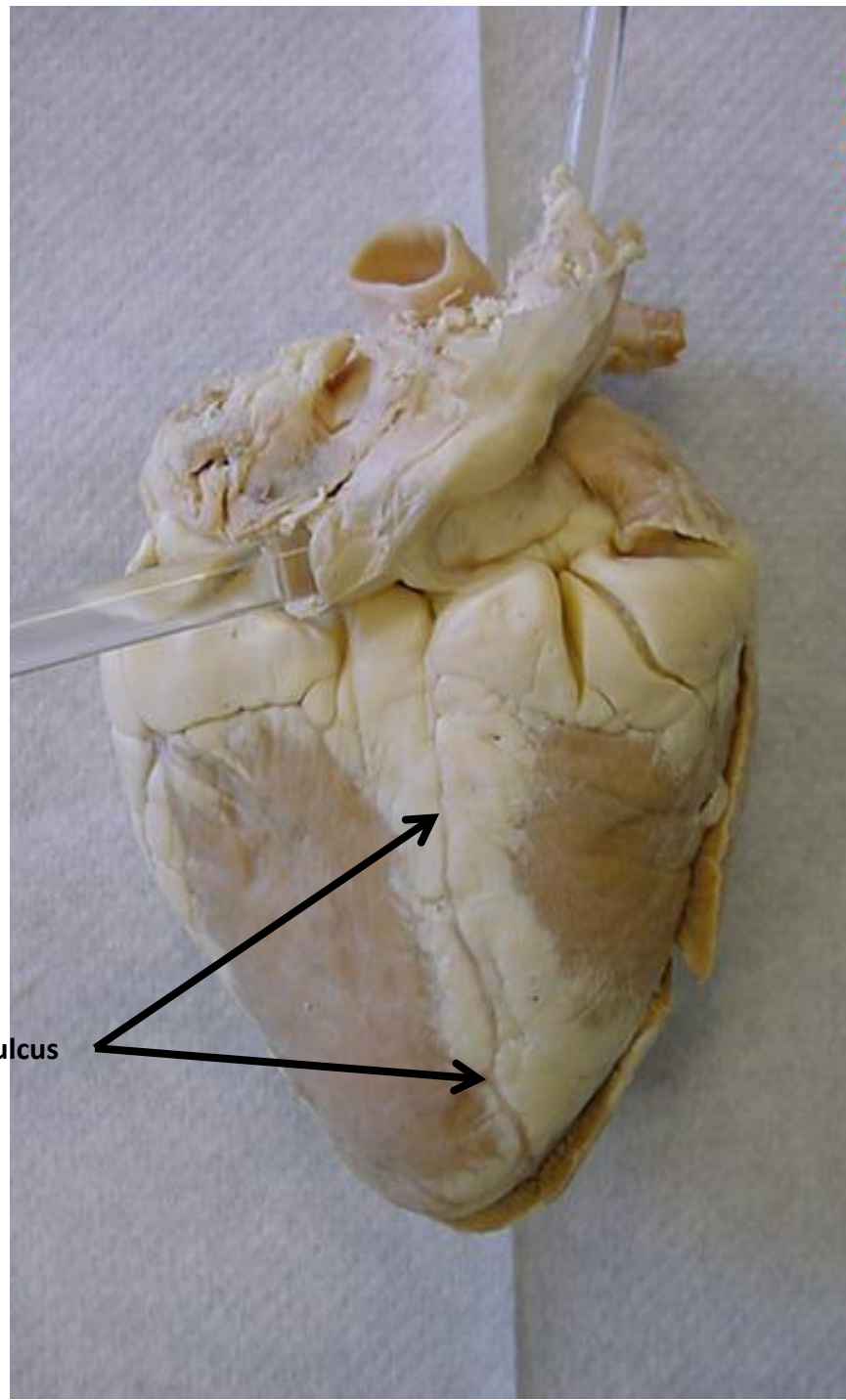
*scroll to the next slide to
check your answer



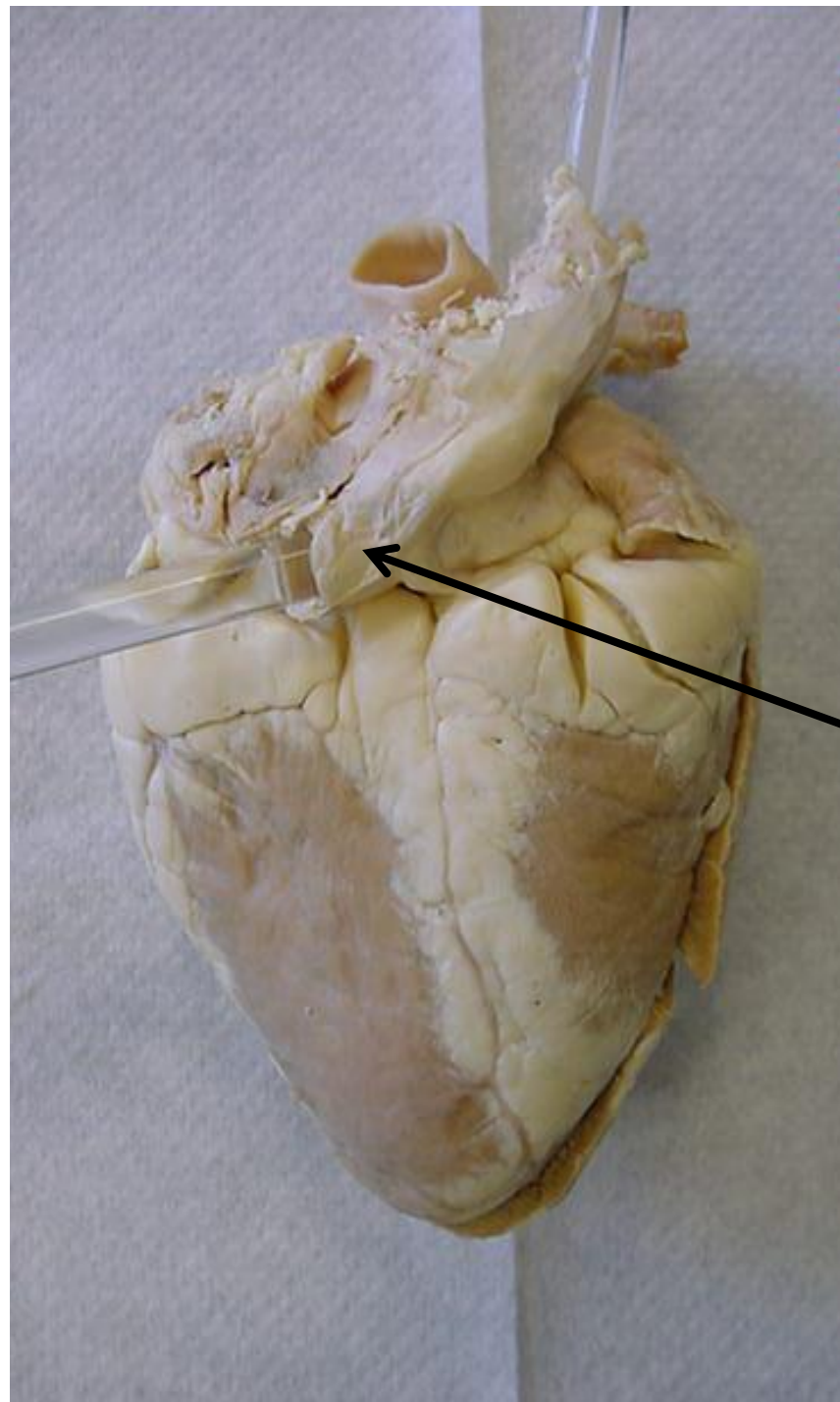
Superior vena cava



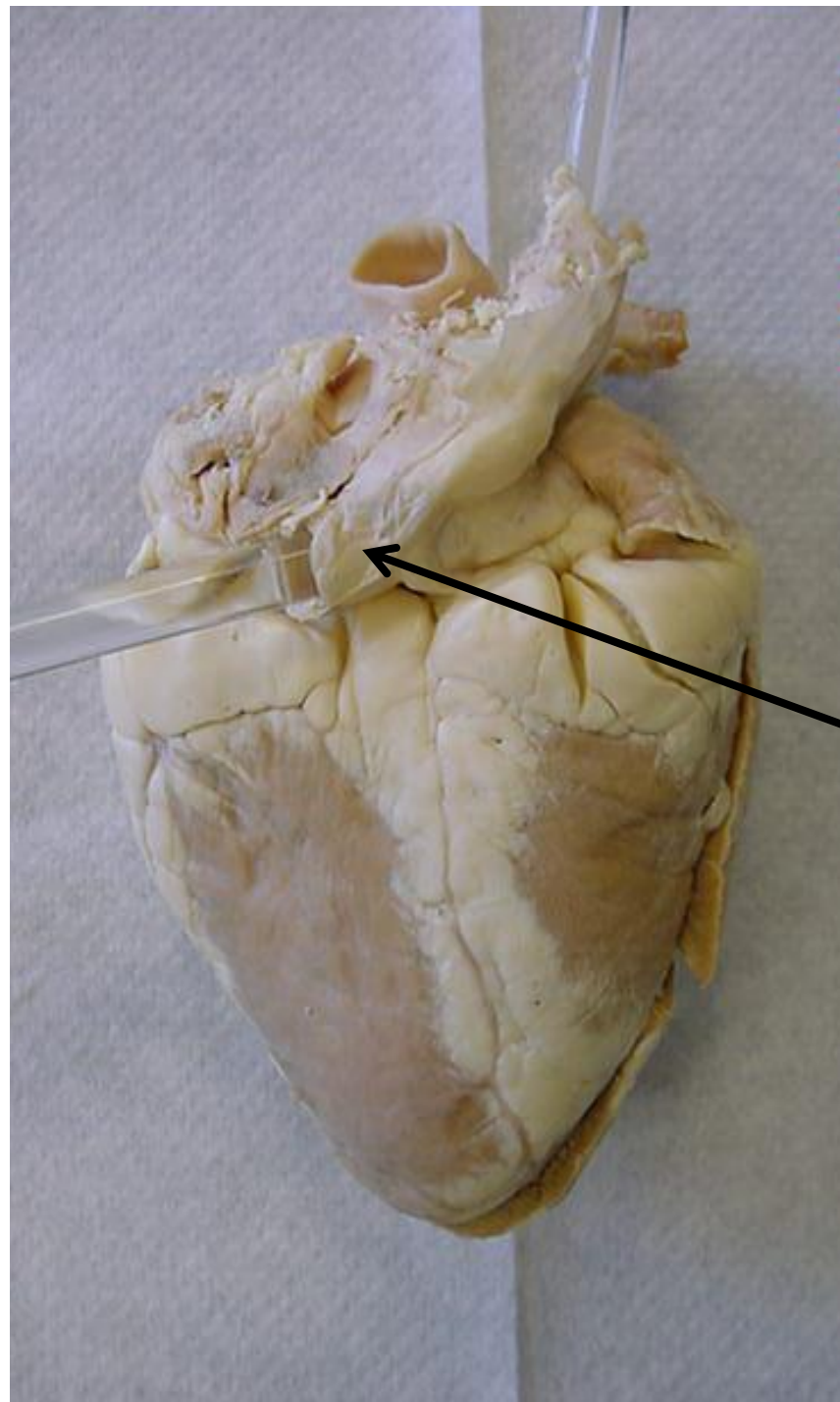
*scroll to the next slide to
check your answer



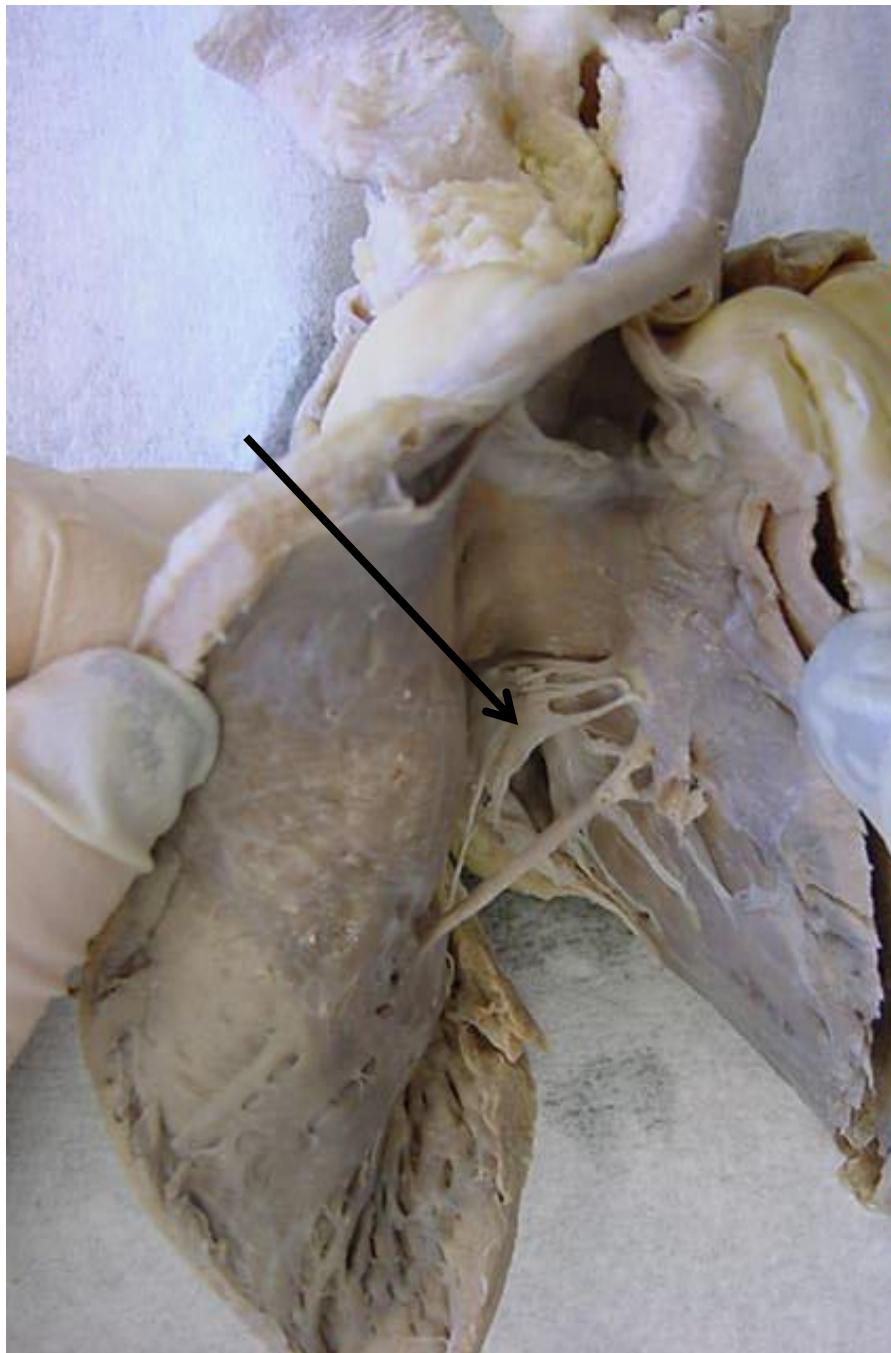
Posterior interventricular sulcus



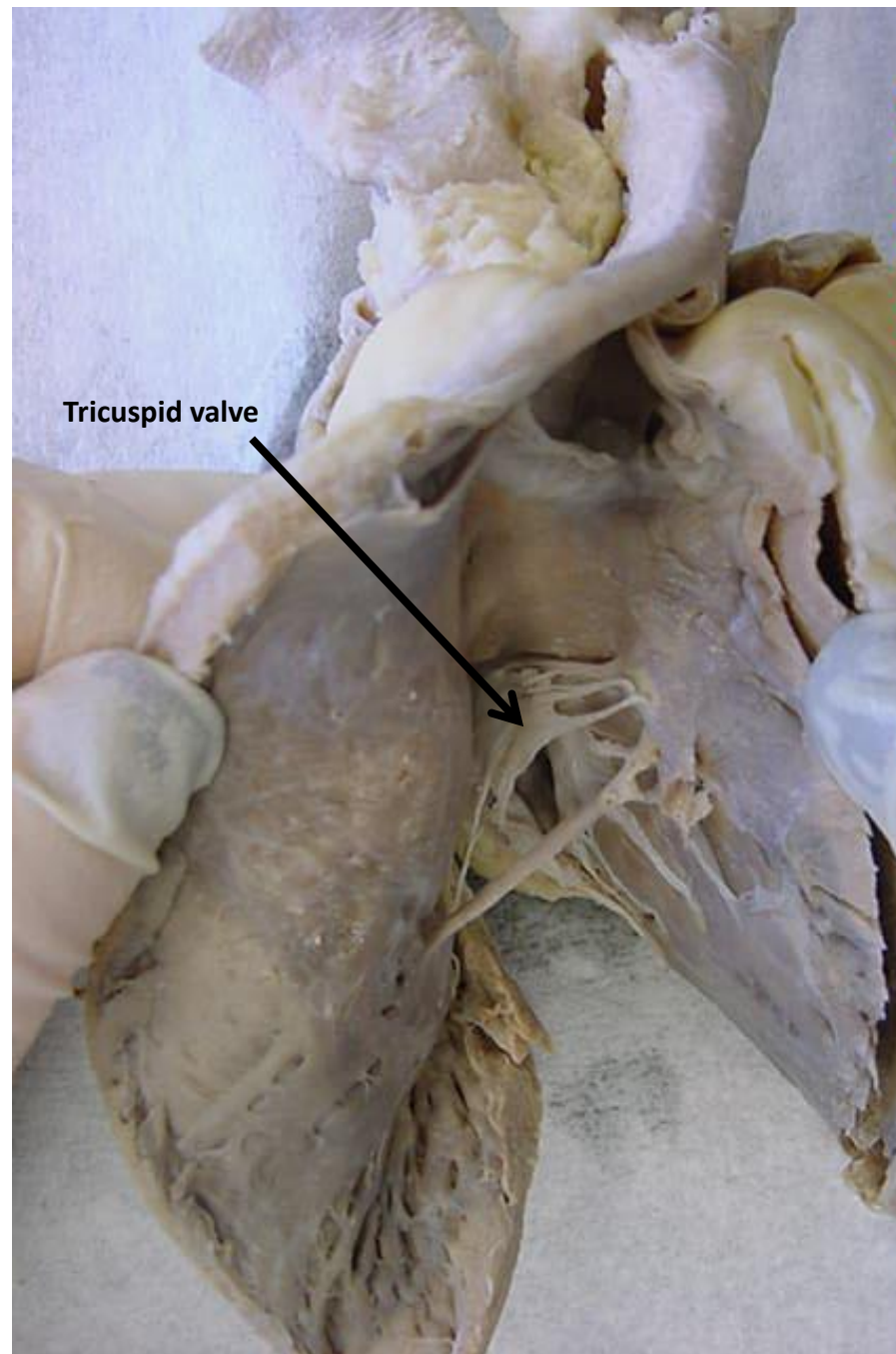
*scroll to the next slide to
check your answer

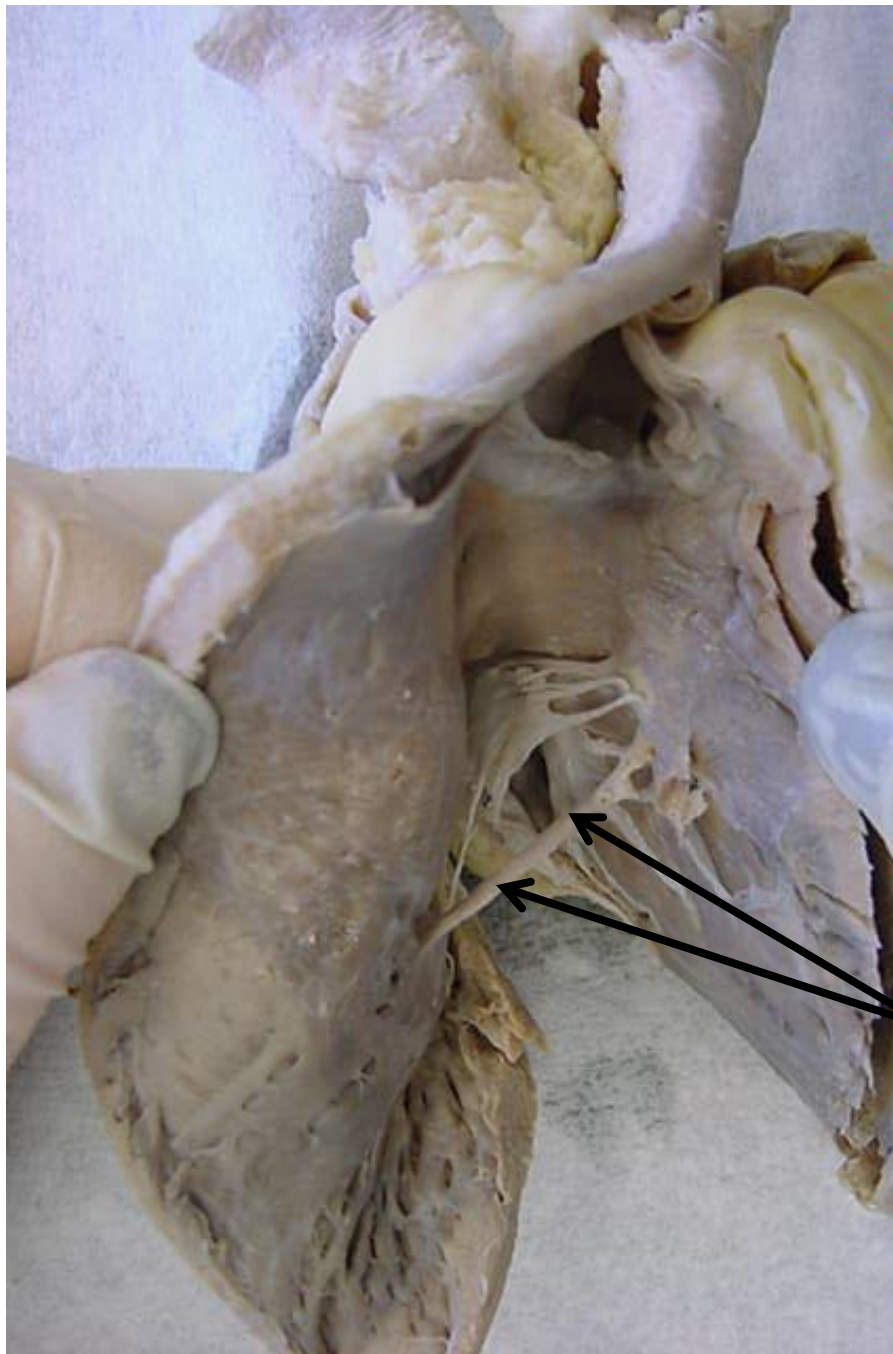


Inferior vena cava

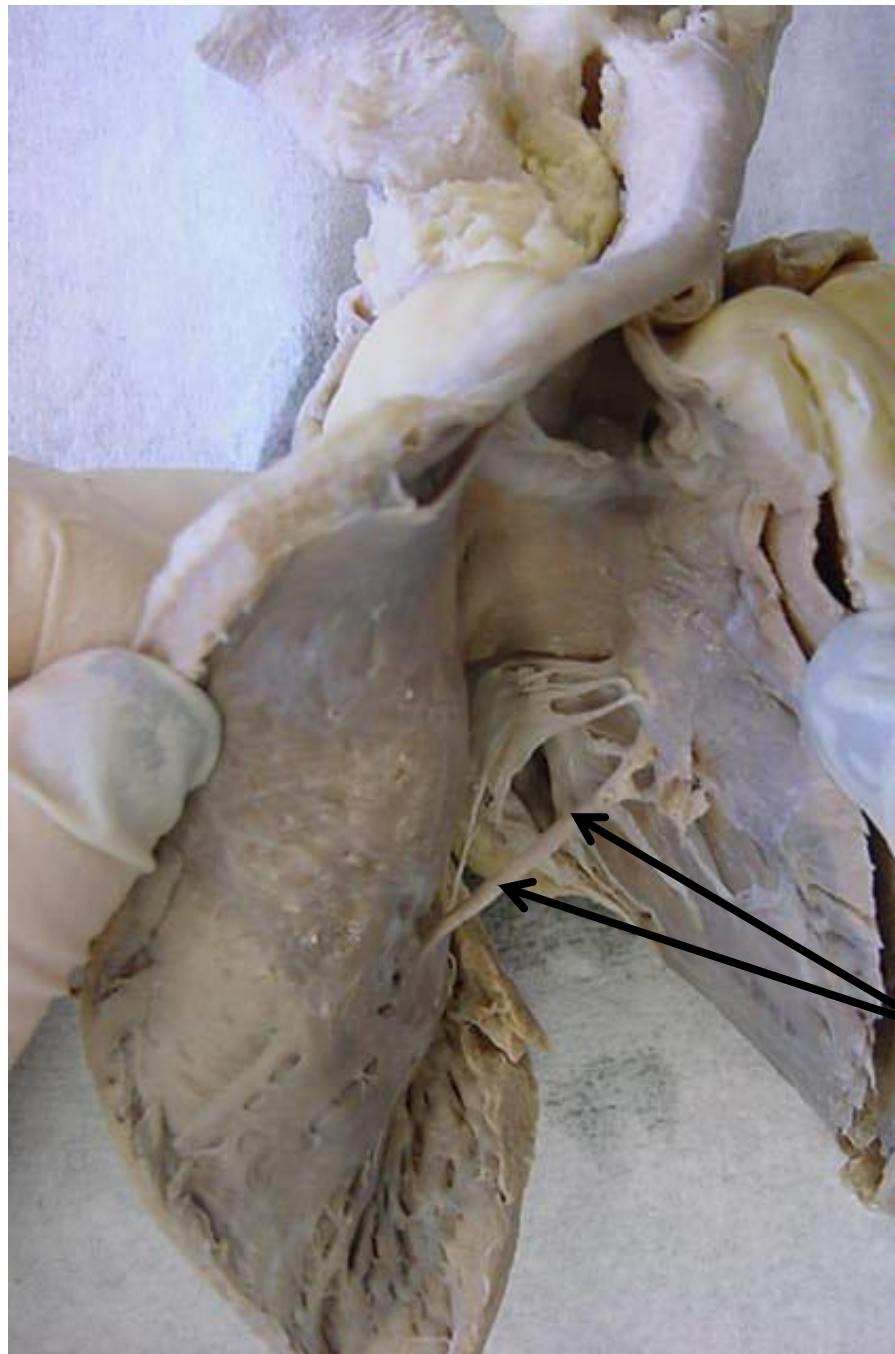


*scroll to the next slide to
check your answer

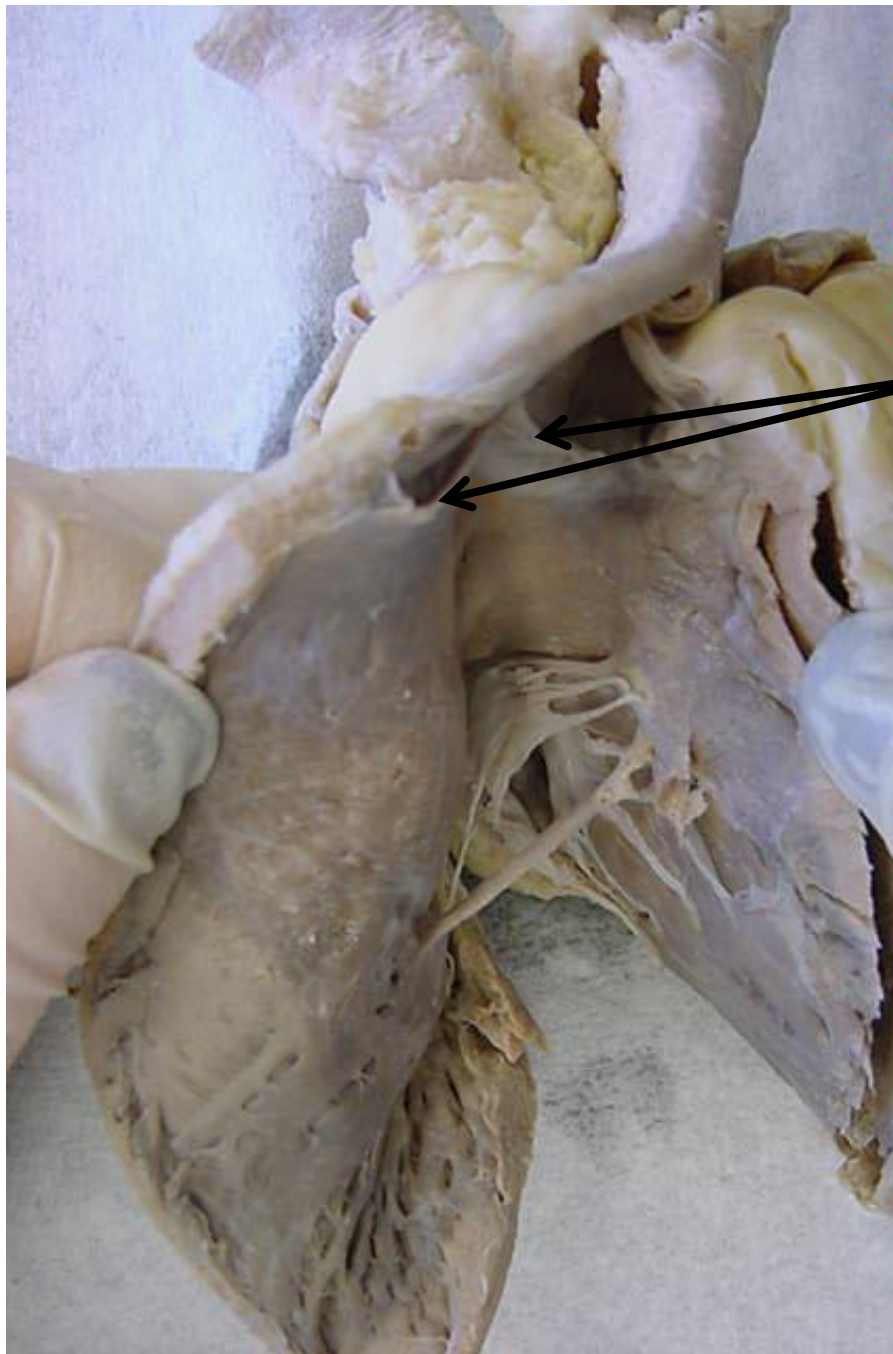




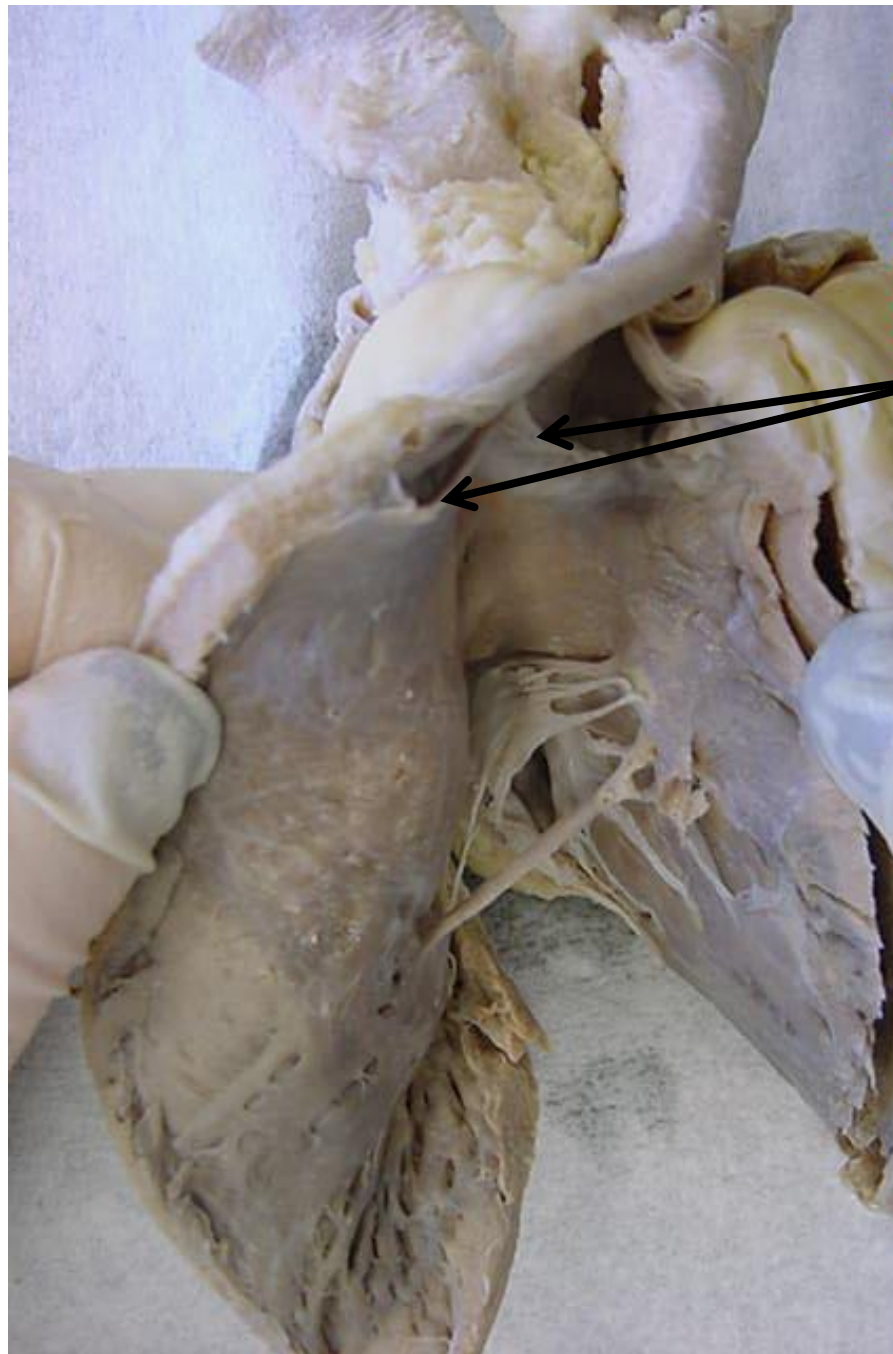
*scroll to the next slide to
check your answer



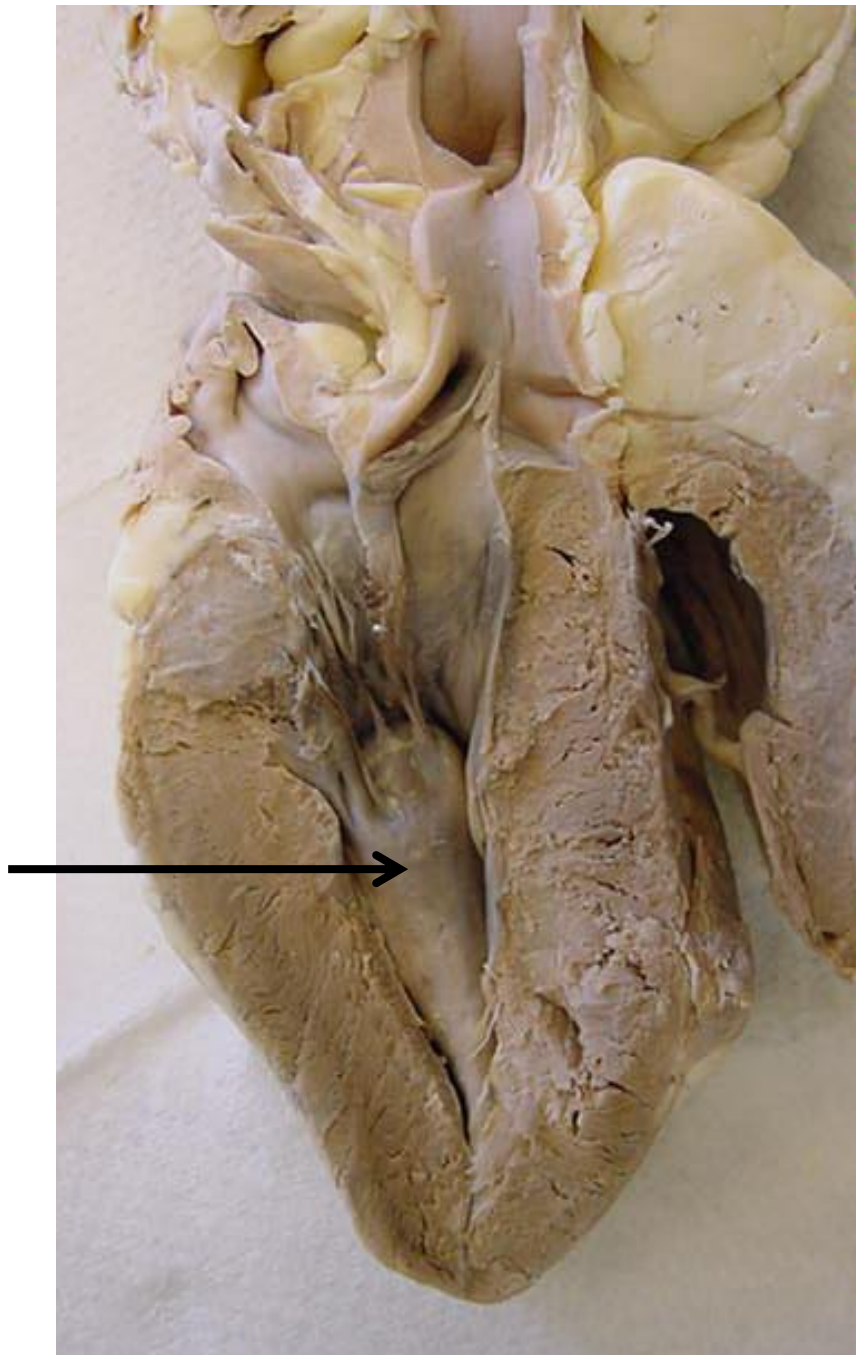
Moderator band



*scroll to the next slide to
check your answer

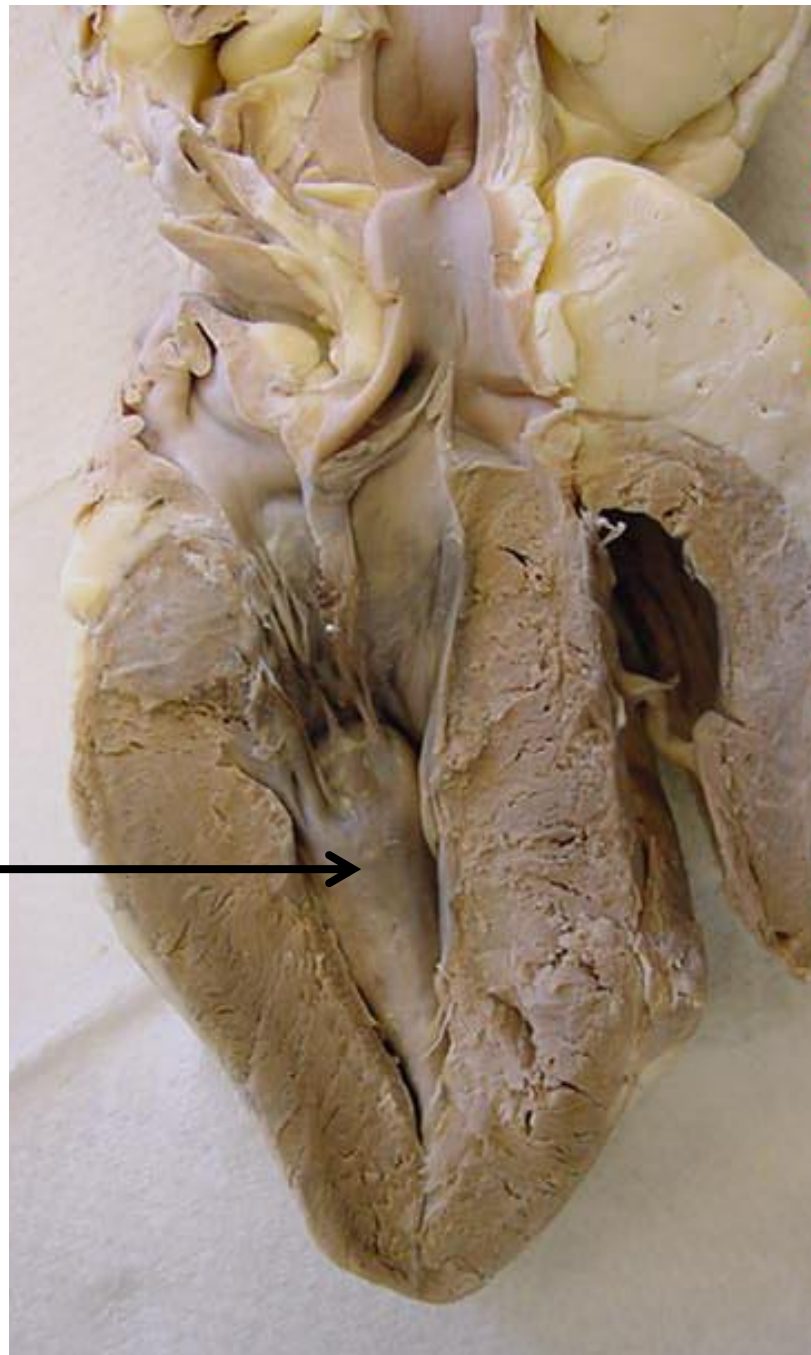


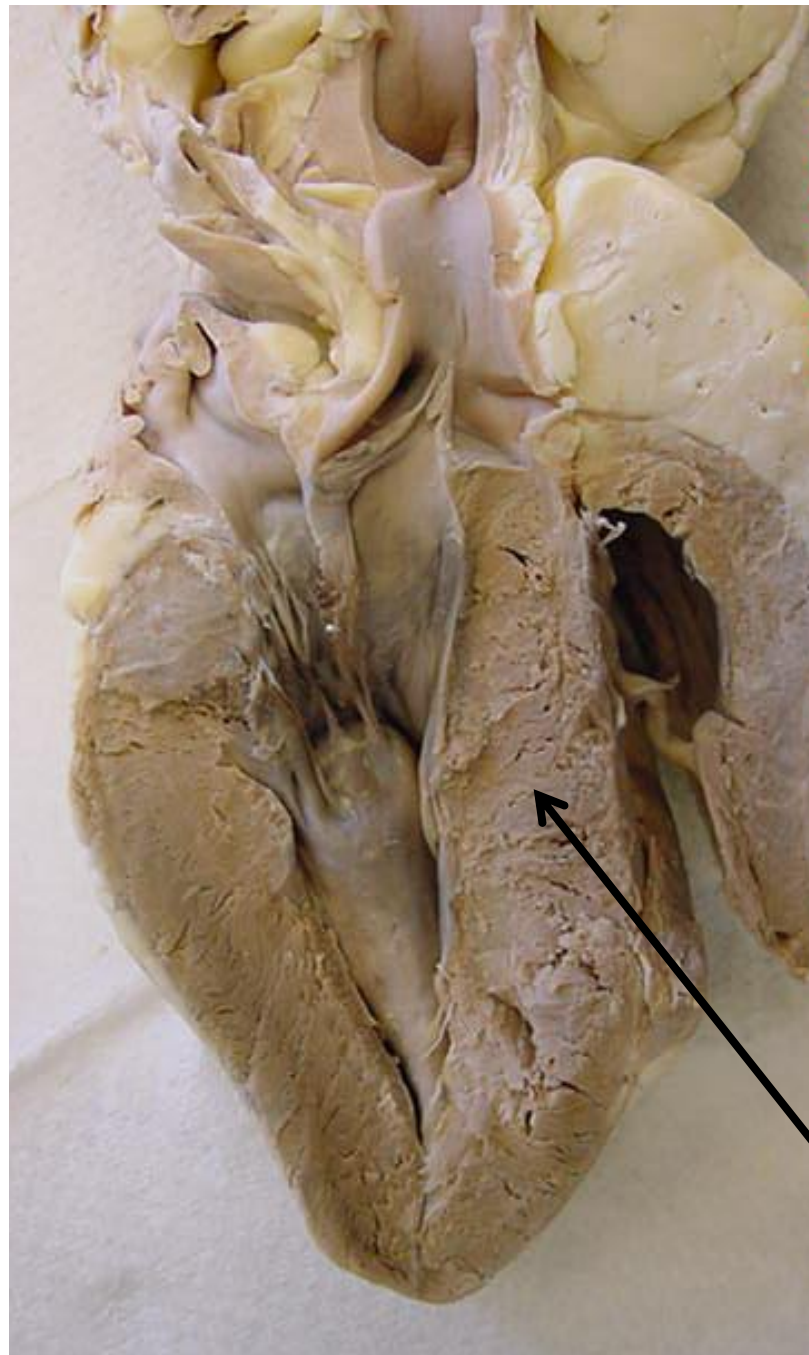
Pulmonary semilunar valve



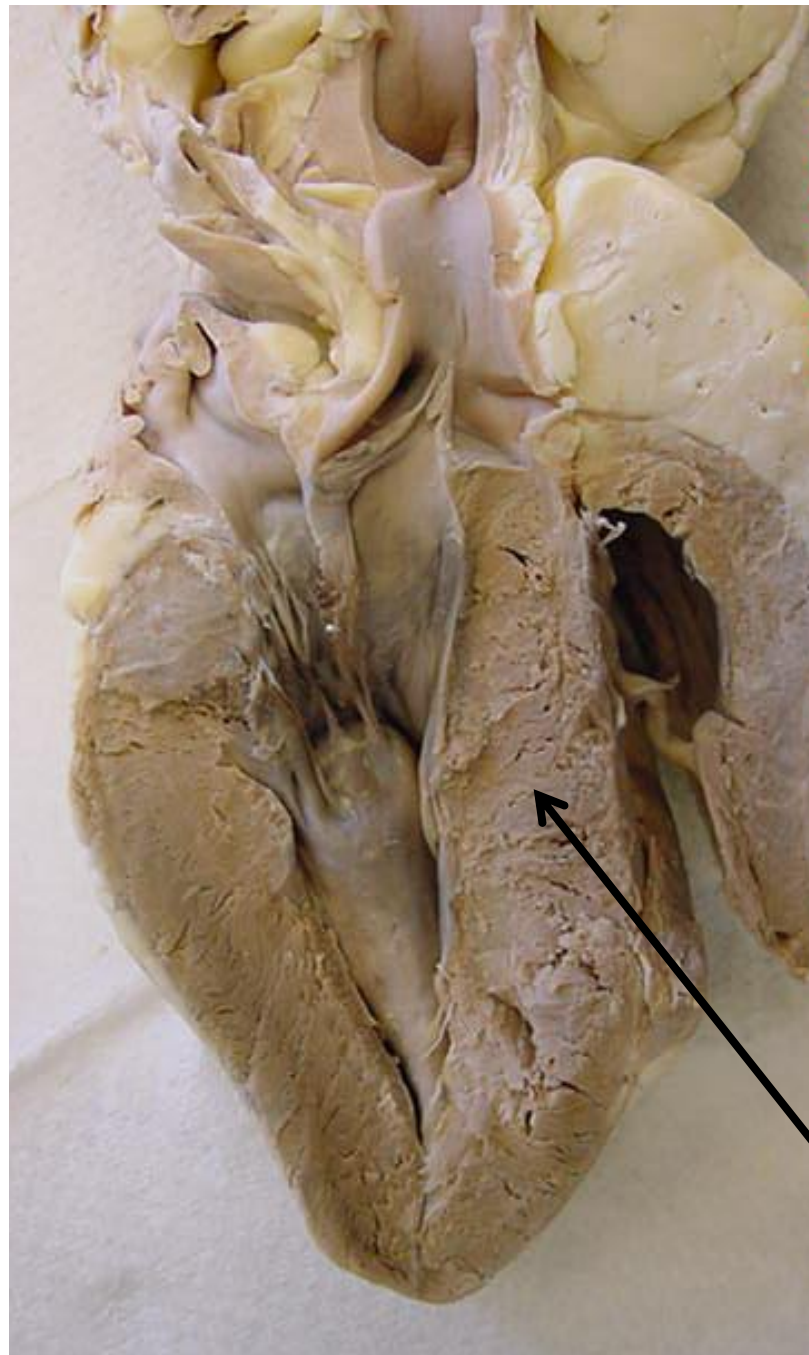
*scroll to the next slide to
check your answer

Papillary muscle →

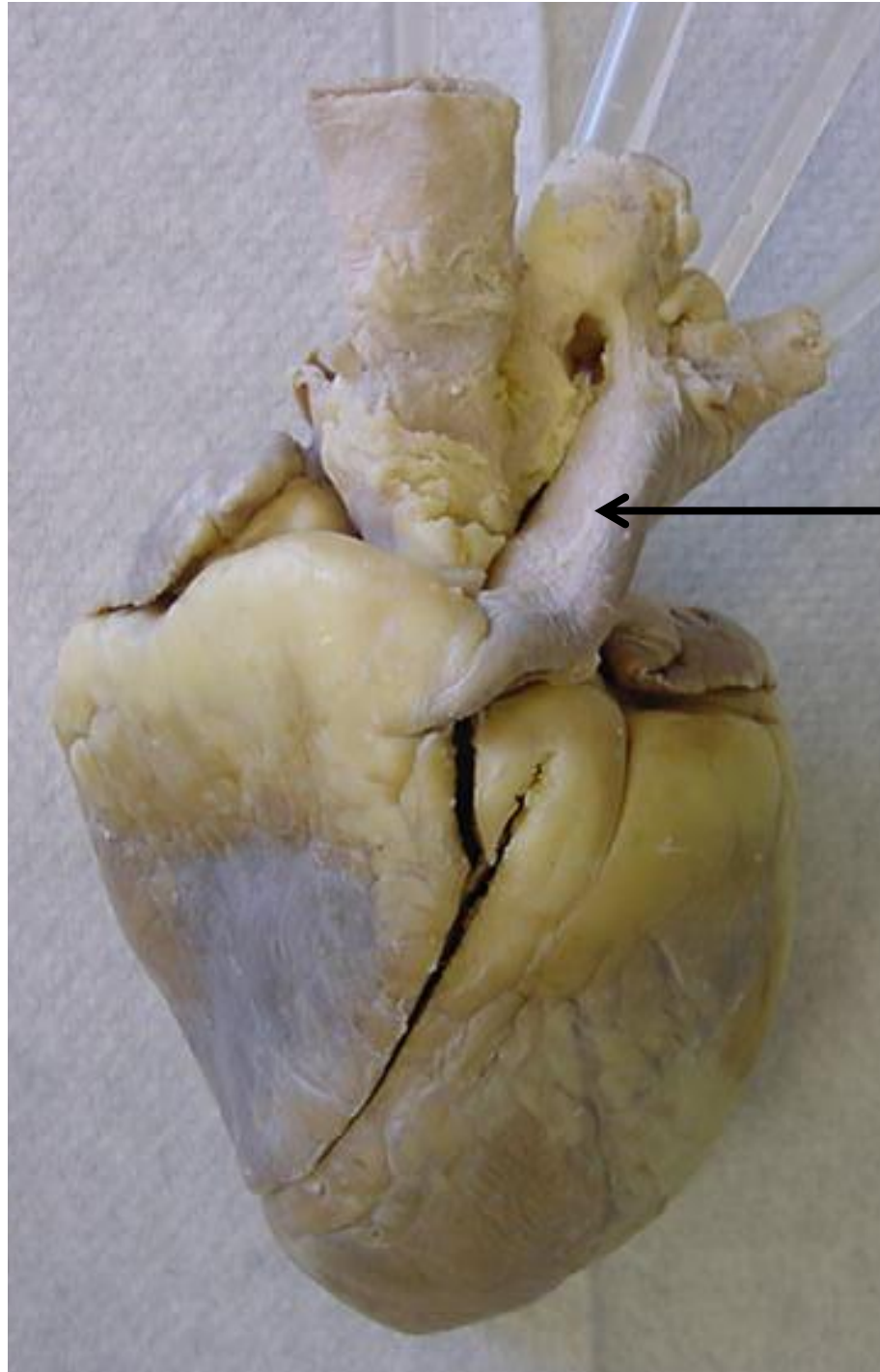




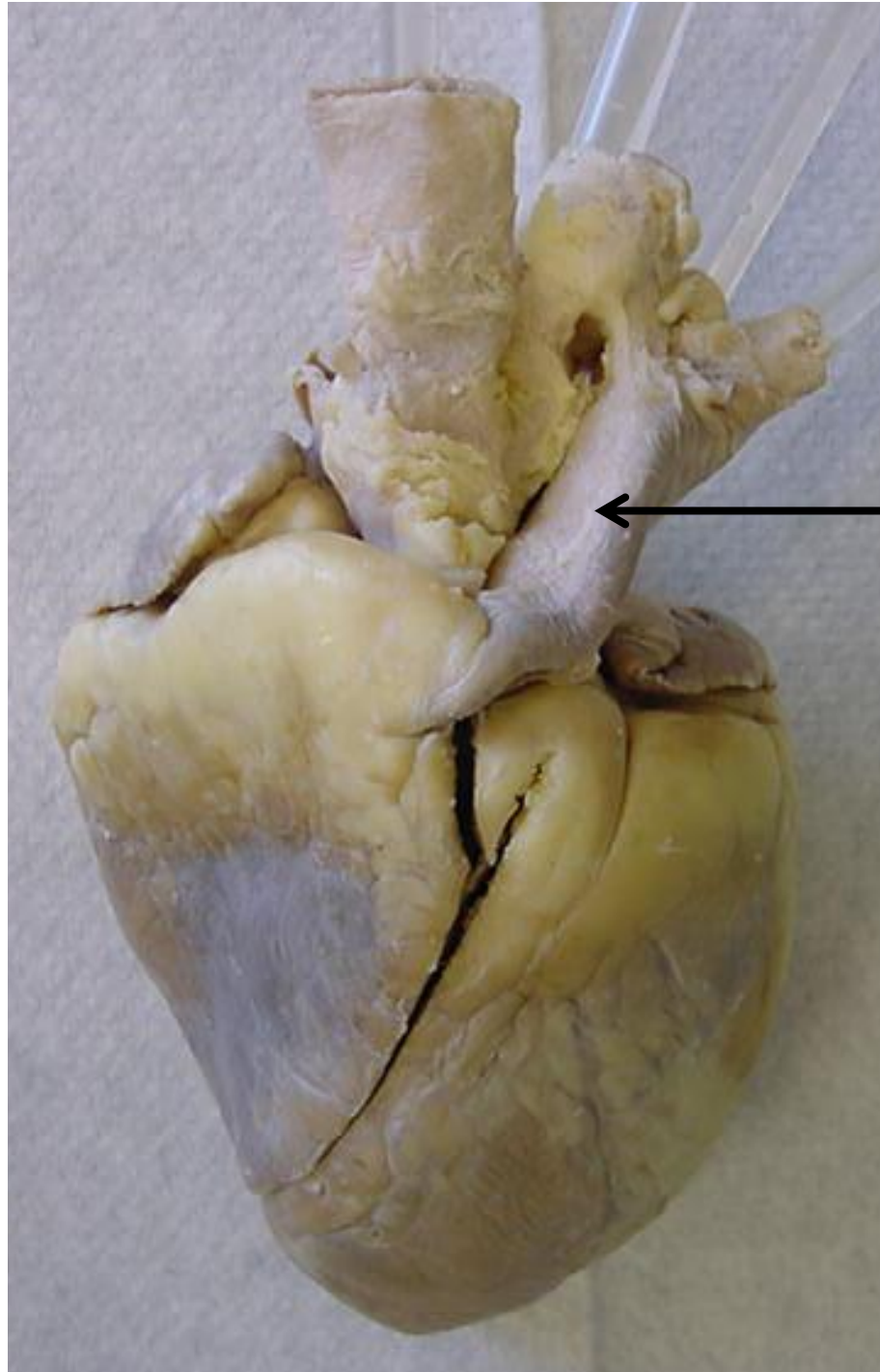
*scroll to the next slide to
check your answer



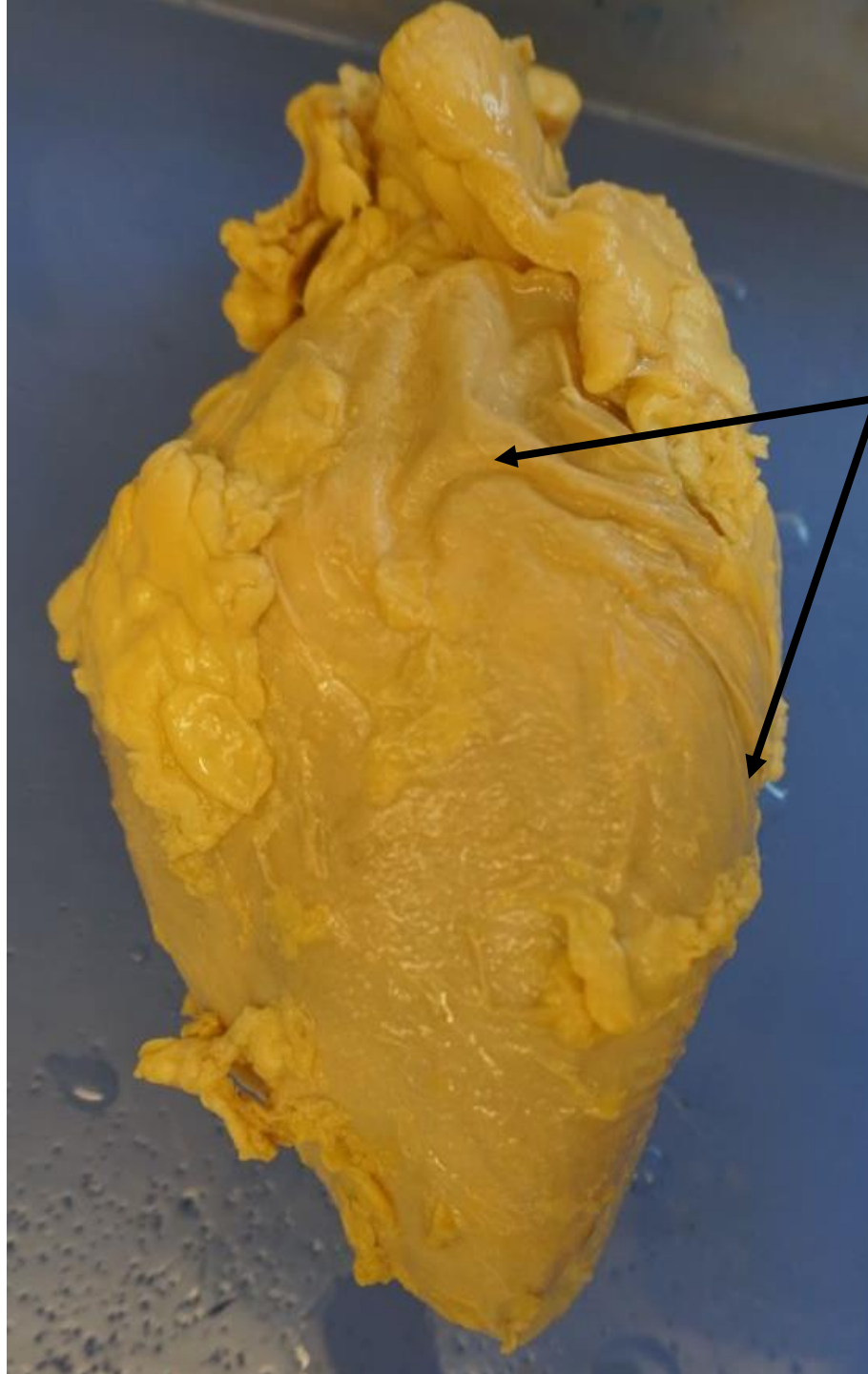
Interventricular septum



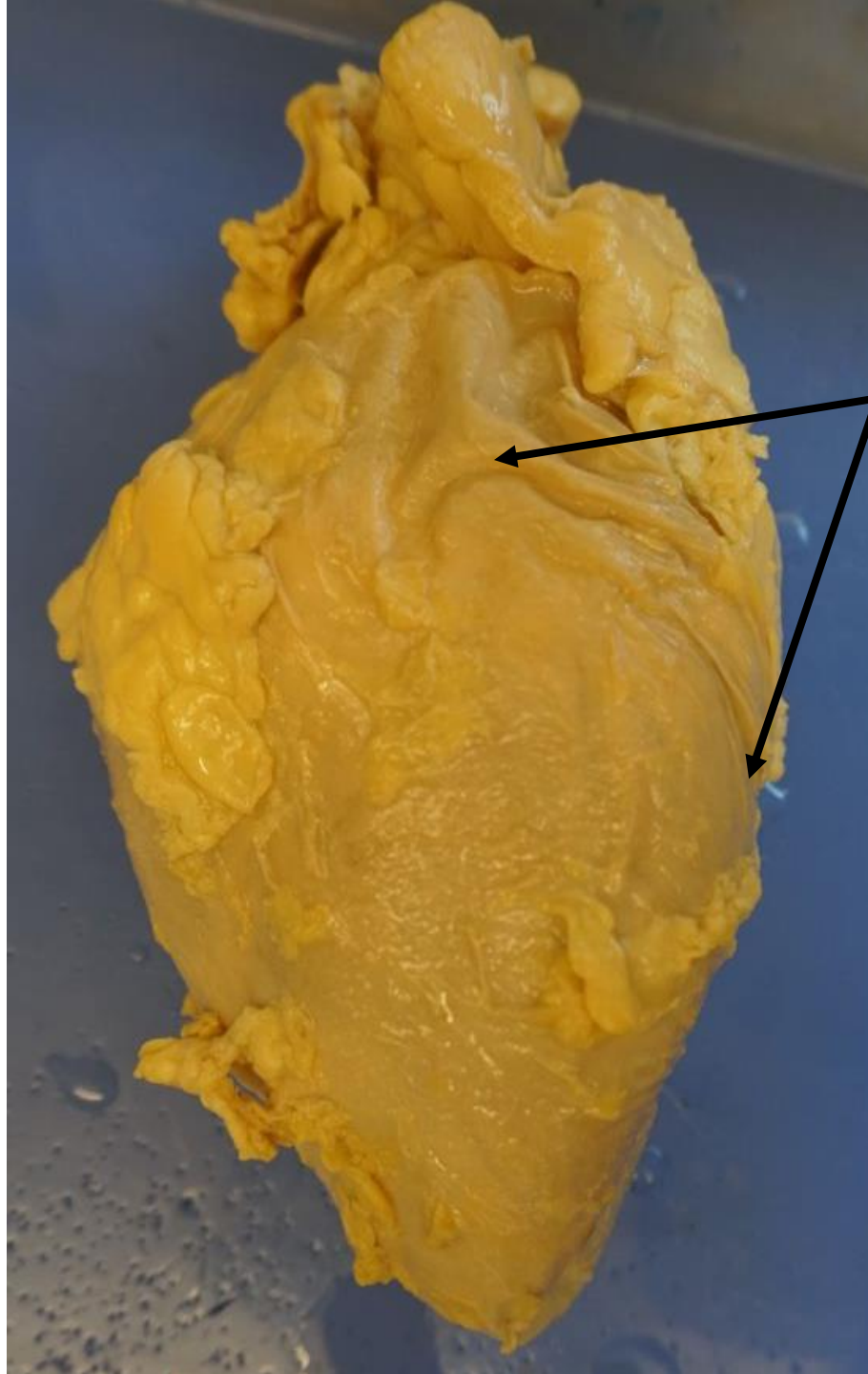
*scroll to the next slide to
check your answer



Pulmonary trunk



*scroll to the next slide to
check your answer



pericardial sac